

40. Secondary Corrections of Lip Scars

WHEN scars have been placed across normal lines, they produce an unnatural effect. Even when of fine quality they still strike a discord. At rest with a flat light they may be passable, but in the action of muscle contraction and against various angles of light they become grossly accentuated.

Scars under tension spread. In the lip not only does this spread produce wide stripes of discoloration but in the male the absence of hair emphasizes the discrepancy. When scars are placed along *natural lines* and the *tension* of closure has been *reduced* and *supported* at the subcutaneous and muscle level, there should be less need for scar revision.

STALL FOR TIME

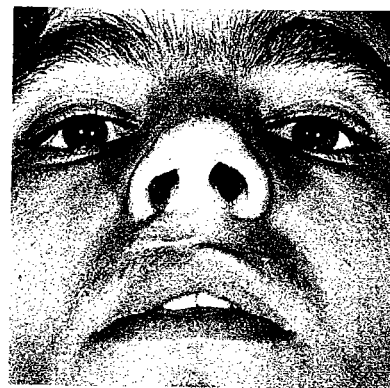
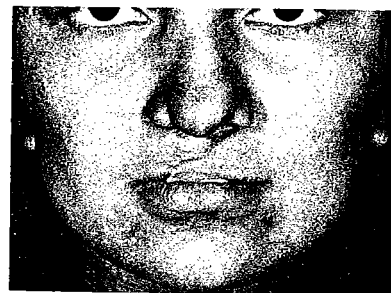As Sir Harold Gillies once said,

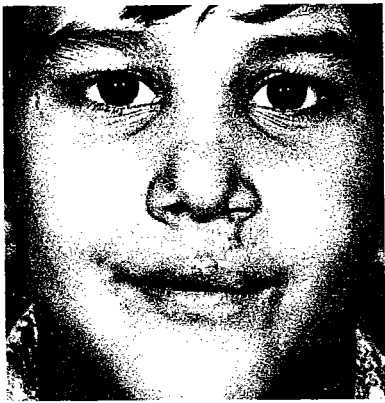Time, although the plastic surgeon's most trenchant critic, is also his greatest ally.

He later simplified this idea to,

Never do today what can honourably be put off till tomorrow.

It takes time for scars to achieve their optimum healing—six months and more. During the early weeks and months after surgery, the fibroblastic contracture can wreak havoc with our work, causing discouragement and even panic. The inexperienced surgeon may be pressed into early reoperation. Patience will allow healing to solve the problem more effectively and less traumati-





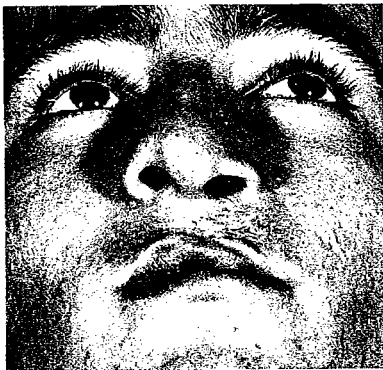
*scars still
angry*

cally. This sequence of events has been demonstrated repeatedly in the primary cases.

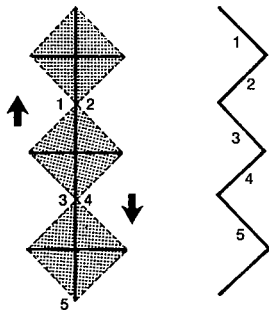
TEENAGE REACTION

Experience has shown that from the age of about 8 to 18 years surgery is followed by exaggerated reaction with longer periods of scar erythema and hypertrophy. More than ever patience is important because if the surgery was executed correctly and the teenager is given the chance, the scar will eventually soften, smooth and fade. Make certain to tell *him* so.

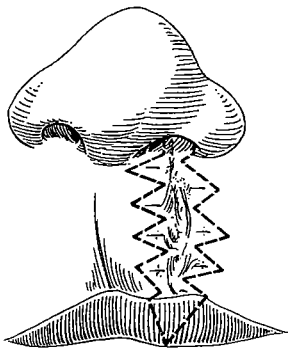
INEXCUSABLE STITCH MARKS



Unforgivable and often uncorrectable are the hideous broad stitch marks flanking the lip scar like ties along a railroad track. These telltale marks are the result of widely placed retention sutures used to counteract the tension that adequate, careful undermining and muscle approximation by deep suturing should have alleviated. True, they are rarely seen any more but when encountered are a nightmare. Fine skin sutures must be placed close to the edges, must not be tightened and must be removed within two to four days. To ignore these fundamentals of wound closure is to be responsible eventually for some surgeon's facing the horrible stitch mark dilemma, which has no acceptable solution. The total area is too wide for simple excision, and sandpaper abrasion cannot smooth deeply enough.



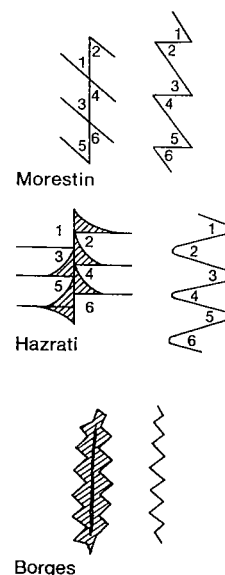
Jack Penn's individual diamond excision of each "crosshatch" scar carried out in a double saw-toothed series, the defect being closed by a shift of the opposing edges until they mesh, may improve the scars, but the zigzagging across normal lines is far from ideal. Besides, in such a confined area the shift might distort the mucocutaneous border unless a discrepancy was already present.



Another secondary procedure aimed specifically at stitch marks and ending up with the same general zigzag scar was presented by Onizuka of Japan in 1971. He marked a Borges W-plasty

excision of the vertical scar of the lip, with the upper interdigitation similar to the rotation-advancement maneuver. He created a philtrum groove and then approximated the series of interdigitations after quite a wide resection of skin and scar.

These various interdigitations are all in the same saw-tooth scar family as Morestin's multiple Z-plasties, Hazrati's compound right-angle Z-plasty and Borges' W-plasty. Considering this general principle as a possible approach to the cleft lip scar, I challenged skin scar expert Albert Borges, the perspicacious Cuban, to send me from Falls Church, Virginia, the photos of a secondary cleft lip case in which he had used a series of his W-plasties. What a pleasure to receive this candid and refreshing response:



The W-plasty is not indicated in the revision of postoperative cleft lip scars for two main reasons. The excision of skin which is required in the W-plasty technique would further increase the already high transverse tension of the repaired upper lip frequently seen in many cases. Following a W-plasty on a wrongly indicated vertical lip scar, each segment of the zigzag scar lies almost perpendicular to the normally vertical relaxed skin tension line of the lip. This should give a poor esthetic result since scars that cross the R S T L direction are notoriously unesthetic as compared to those that follow it.

right

amen!

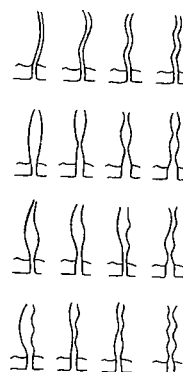
A WAVY LINE

In 1973 at the Copenhagen Congress Gerhard Pfeifer, who has followed Schuchardt as chief of Nordwestdeutsche Keiferklinik, University of Hamburg, offered his wave-line scar closure. He had developed it over the past eight years, using it in 200 primary clefts and 200 secondary clefts. He diagramed his design prior to the suturing as

Parallel, symmetrical and differently curved wave lines,

explaining,

The variable system consists of a few basic types of semicircular skin incisions which can be adapted to the requirement of each individual case. . . . The resultant scars are vertical or curved in form . . . all bilateral clefts can be closed in the same operation.



Pfeifer mobilizes and approximates the orbicularis oris muscle fibers during his wave-line skin closure.

DOUBLE-BREASTED VEST SCAR REVISION

The double-breasted vest scar revision, first presented in 1970, has been found of value in certain cleft lip scars. Of the many factors that adversely influence the character and width of a scar, tension is probably the prime offender. Smiling and crying are constantly pulling on the lip, which inevitably under this tugging has to spread its scar. Then the young teenager, just at the time for secondary revisions, tends to react more angrily to everything, including his wound, heaping fibrous tissue into the zone of the healing. In areas of no tension, a hairline scar is not unusual, so if the tension can be taken up "underground," the edge-to-edge scar should have less "tension reason" to spread.

In lips that have a vertical straight-line or curving scar which has broadened or is ugly, and especially when the lip conformity is flat on the scar side with lack of philtrum column, the double-breasted vest is indicated.


First the lines of incision are marked (1). Then the epithelium is dissected from the lip scar, leaving the dermis intact (2).

Along one side of the scar an incision is made through the dermis into the subcutaneous tissue. Then this edge is undermined on the bias laterally with a scalpel, somewhat more than the width of the scar (broken line) (3).

The dermal scar, still attached to the opposite side, is undermined as a thin sheet until just before the level of the opposite side is reached, at which point the undermining dips deeper (broken line) (4). Along the point where the denuded dermis joins the normal skin, a nick incision on the bias is made to a conservative depth but deep enough to create a matching edge for level apposition with the skin thickness of the opposite edge (5).

The scar sheet, attached to the freed edge of one side, is pulled across and under the opposite edge until their two skin edges

almost overlap. Then the scar tether is sutured with 4-0 Mersilene to create the first-line under-buttoning, taking up all the tension of the closure (6). The advancement of this sheet of scar can be increased by rolling it on itself, and in the process it not only relieves tension but forms a mound similar to the missing philtrum column (7). With all the tension taken up at the subcutaneous level, a subcuticular suture of the relaxed skin edges can achieve an outside buttoning, or fine interrupted sutures can be used (8). Any stretch of the scar at the underpinning is hidden. The adhesions of the dermal imbrication should ensure against the exertion of any tension on the actual visible skin scar.

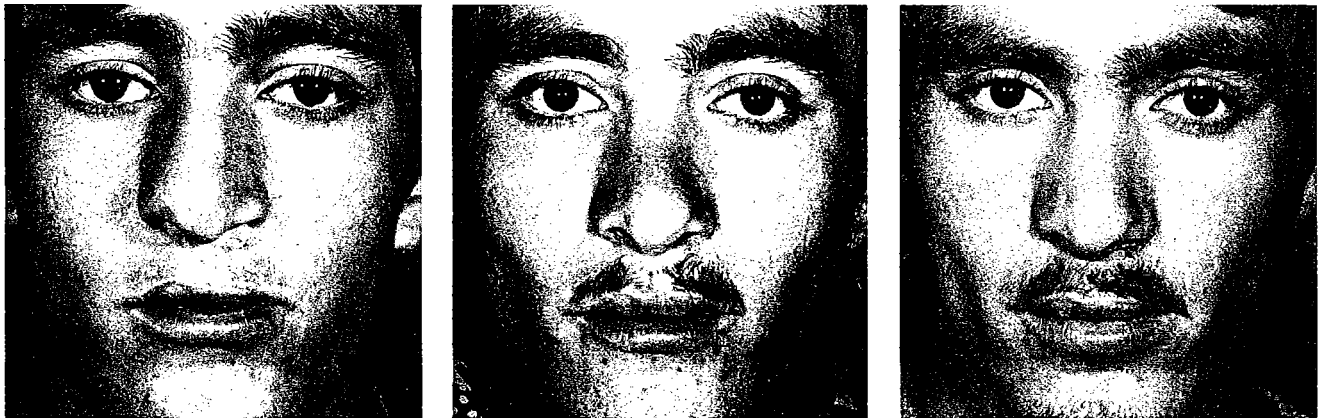


SIMPLICITY OFTEN SUFFICIENT

Of course, most of the time scar excision need not be so fancy, particularly when the scar runs along natural lines. Simple, clean perpendicular excision of the scar, freeing and careful approximation of the muscles and accurate skin apposition can eventually produce an almost invisible union.

HIDING THE SCARS IN THE MUSTACHE

When the lip scars and cross-hatching stitch marks are such that excision is impossible and abrasion ineffectual, at least in the male it is possible to let the hair grow and excise special portions of the scars to effect a balanced mustache. This principle obtained a reasonably good result (below) but the central and left area seemed more bald than the right. A hair-bearing free graft from the bushy eyebrow was transplanted and is so swashbuckling that the left brow may be called upon for the right mustache.



ABRASION

When the lip scars are too many or too scattered for effective excision, they may be improved by abrasion with sanding. If the scars are reasonably good but show some minor irregularities which cannot be benefited greatly by further excisions, often they can be smoothed by abrasion. This is but a *final scar-polishing*

gesture. It can be done along with other minor revisions, such as a V-Y vermilion roll-down and normal alar base and cleft side alar rim excisions as shown.

