

37. *How to Rotate and Advance in a Complete Cleft*

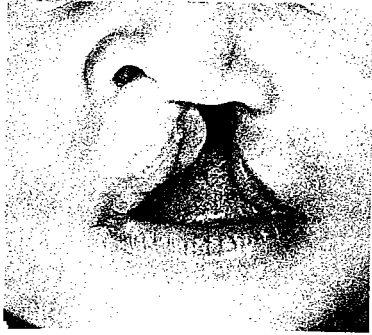IT has been said often that a natural-looking result following closure of a congenital cleft lip is a work of art. In fact, it is a three-dimensional work of sculptured art. Principles, measurements, marks and incisions of a technique can be standardized and a blueprint of the technique memorized. Yet the last few millimeters which make all the difference must depend upon *the sculptor and his clay*.

Before marking and cutting, compare the normal side and the abnormal cleft side with your eyes, switching back and forth again and again in a horizontal nystagmus. Then, by transposing the ideal normal over this entire component in your mind's eye, it will become apparent what is present, its position, and what is needed. Now comes the surgical scramble to make up the difference without compromising the normal.

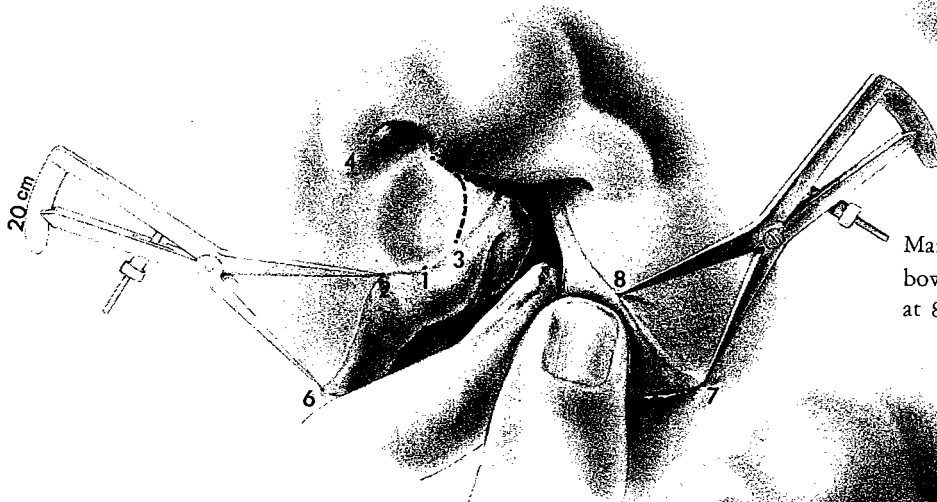
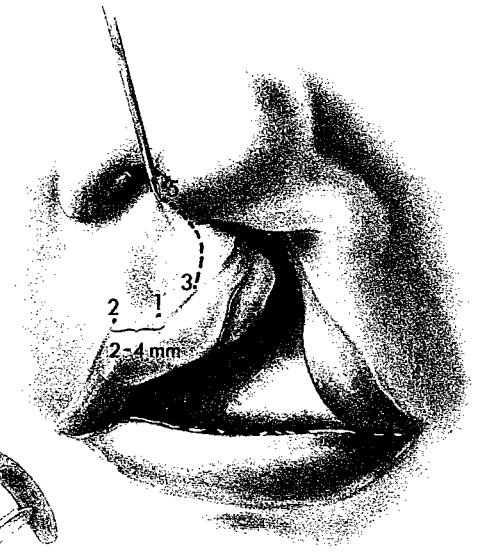
SKIN MARKING AND SCORING

First dot-mark the key landmarks on the non-cleft element as described in Part V, Incomplete Clefts, 1 to 2 to 3 of the cupid's bow, all of which are usually 2 to 4 mm. apart. An important measurement on the normal side is the distance from point 2 at the height of the bow on the non-cleft side to the alar base 4, which measures from 9 to 12 mm. This is the distance that will have to be matched on the cleft side and is roughly the length that must be achieved eventually along the rotation edge as well as along the advancement edge. Mark the rotation incision, which rises vertically up to the cleft side of the columella base and then curves across the midline hugging the columella base but stopping just short of the philtrum column of the normal side 5. The back-cut marking is postponed temporarily. The rotation incision mark is scored with a #67 Beaver blade.

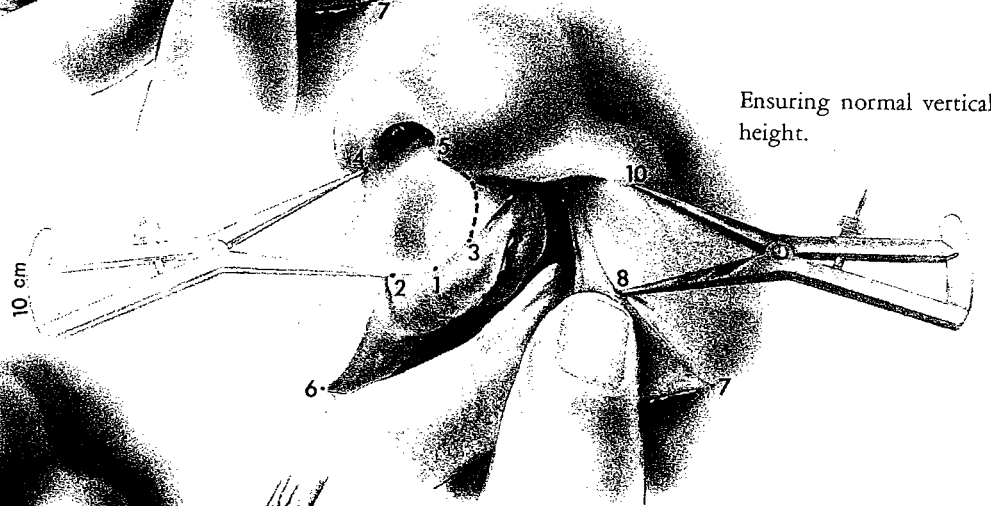
The distance from the commissure 6 to the height of the cupid's bow on the non-cleft side 2 is measured and is usually about 20 mm. The same distance is marked on the cleft side from the commissure 7 to a point along the mucocutaneous junction line of the lateral lip element 8. Point 8 indicates the limit of lateral paring. The highest and most medial point 9 of usable lateral lip element is marked as the probable tip of the advancement flap.



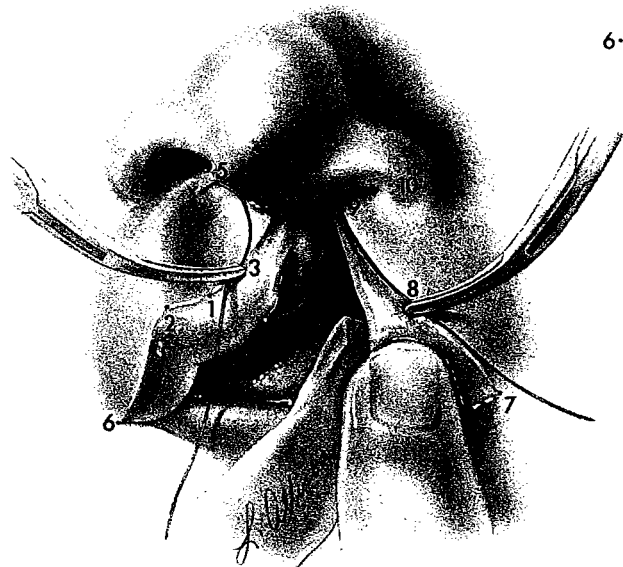
Dotting the bow.
Marking the rotation.



Marking normal commissure-to-bow-peak distance on cleft side at 8.



Ensuring normal vertical height.




Matching length of rotation incision with edge of advancement flap by bending and straightening a wire.

If the lateral element is diminutive, it may be necessary to extend point 9 up into the nasal vestibule to get the extra cleft edge length required to match the rotation edge. This extension will enable one to hold the line at point 8 in the lateral paring. An estimate of these distances is best checked by the curved-wire technique. When all available tissue has been incorporated into the tip of the advancement flap and the flap is still short, conservative paring of the cleft edge laterally even beyond point 8 may be necessary for a millimeter or two at most.

The next point 10 is set at the midpoint of the alar base join with the lip. In incomplete clefts this may be the lateral extent of the upper curved horizontal incision. Yet in complete clefts that incision must be continued to the lateral extent of the alar base join with the lip 11 and, depending partly on the amount of alar base flare, may have to be extended farther in a circumalar direction around to point 12.

If the length of the lip from the alar base at 10 to the mucocutaneous ridge at 8 is much shorter than the distance from the normal 4 to 2, then the incision from 9 to 10 to 11 and even to 12 may have to be raised to include a millimeter or more of alar base in the lateral lip flap B. Including a bit of alar base in the upper part of the lateral advancement flap will conveniently shift this prominence, as this flap advances, into

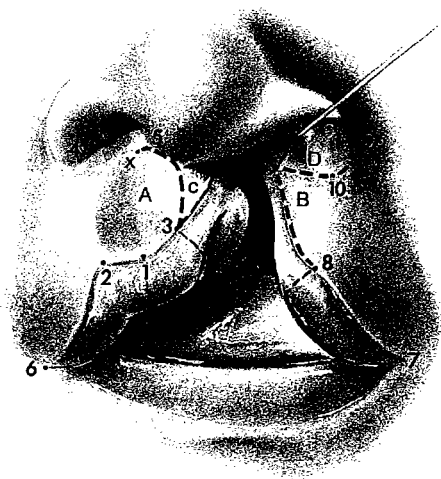


For needed edge length tip of flap (9) can be extended into the vestibule.

For required vertical height the base of the ala can be included in the lip flap.

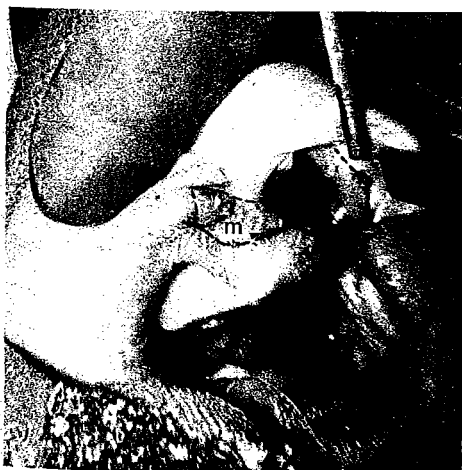a nostril sill position in incomplete clefts or columella base in complete clefts. The stretched ala can well withstand such minor shortening.

A line is marked to join these points 8, 9, 10, 11 and possibly 12, and the line is then scored to define the advancement flap B. Now the rotation and advancement flaps have been marked finally.

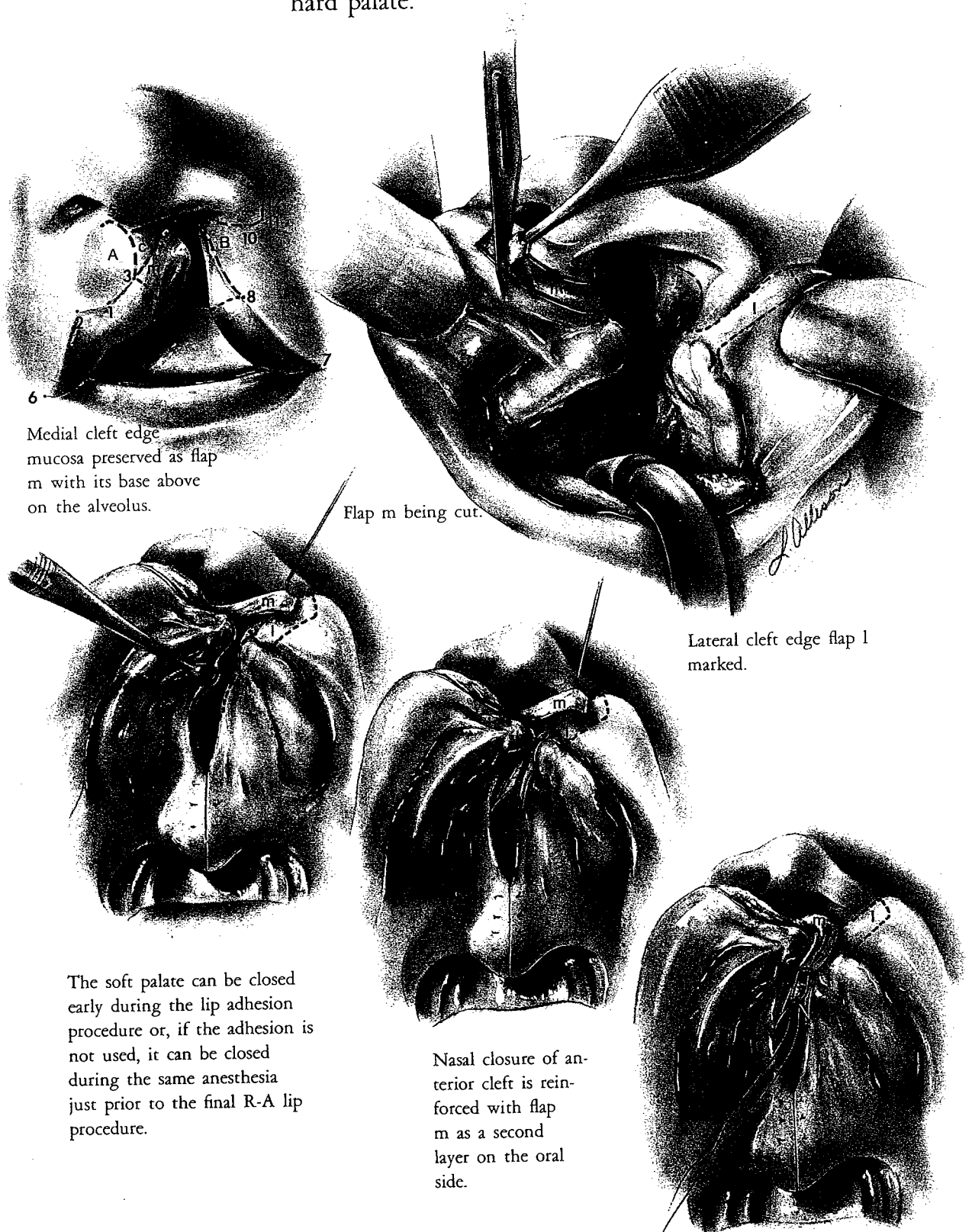


SAVE THE PARINGS

The next step is concerned with the salvaging of the cleft edge mucosa. As the cleft edges must be pared in order to approximate them, a flap of vermilion based above on the mucosa of the alveolus in the upper labial sulcus is stabbed off each side of the cleft with a #11 Bard-Parker blade and left dangling for later use.



Of course, various possibilities offer themselves. The medial mucosal paring flap based above on the alveolus can be used as the second *oral* layer in the closure of the alveolus and anterior hard palate.



6
Medial cleft edge mucosa preserved as flap m with its base above on the alveolus.

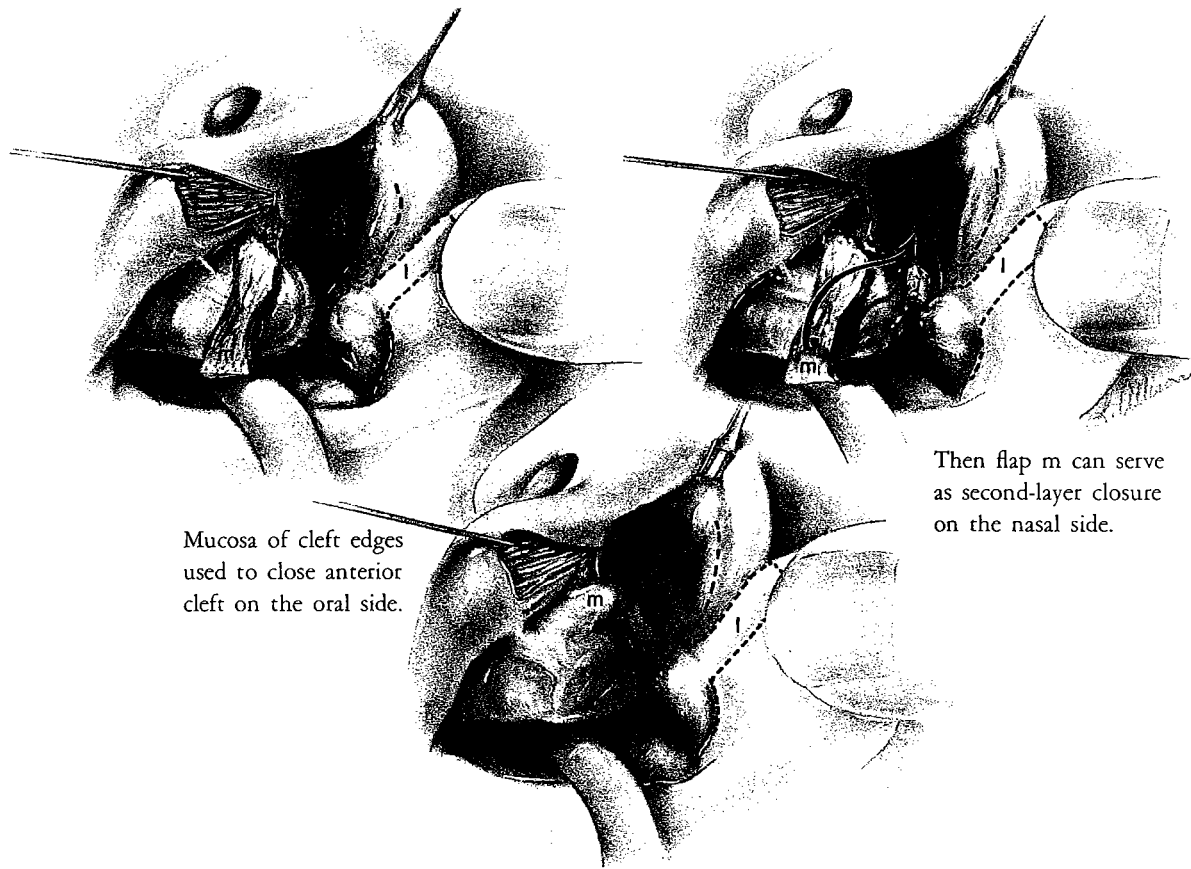
Flap m being cut.

Lateral cleft edge flap l marked.

The soft palate can be closed early during the lip adhesion procedure or, if the adhesion is not used, it can be closed during the same anesthesia just prior to the final R-A lip procedure.

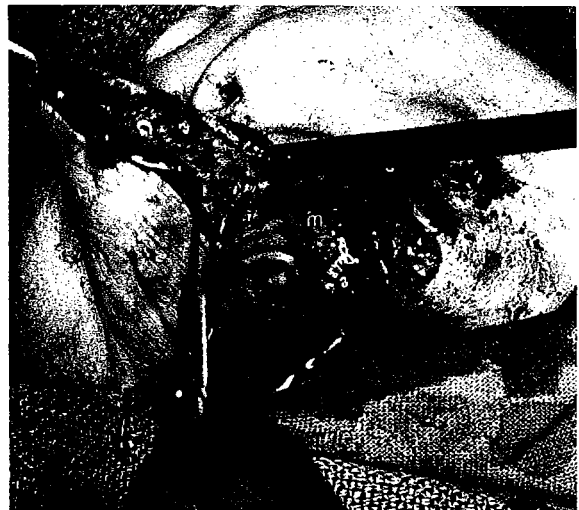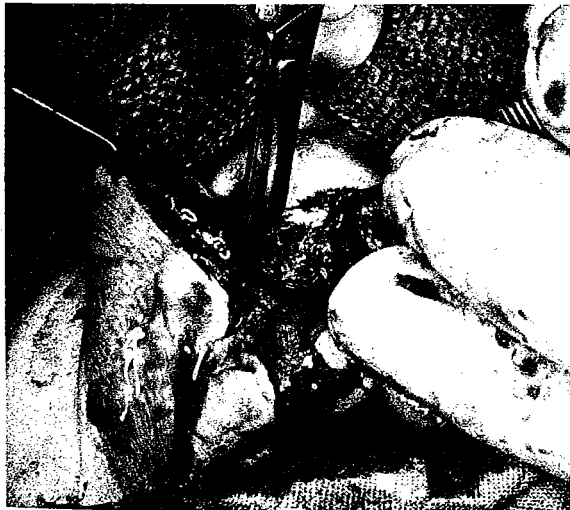Nasal closure of anterior cleft is reinforced with flap m as a second layer on the oral side.

Or this medial vermilion paring flap can serve as the second layer but on the *nasal* side.



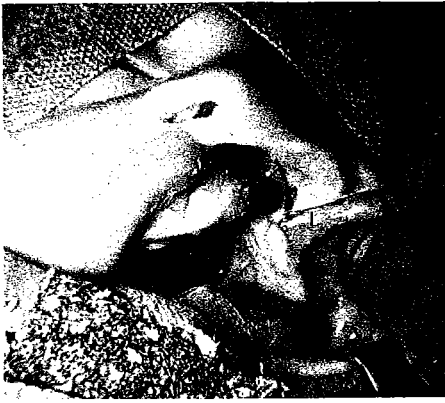Mucosa of cleft edges used to close anterior cleft on the oral side.

Then flap m can serve as second-layer closure on the nasal side.



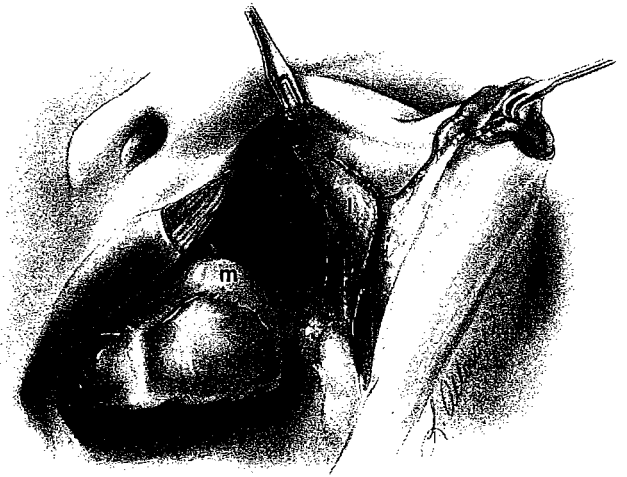
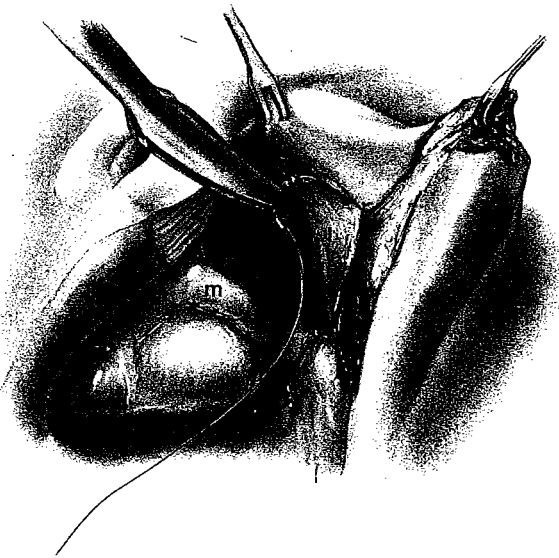
Freeing the medial lip element off the maxilla.

With care to avoid the base of this flap, the medial lip element is freed by sharp dissection from the maxilla.



A similar paring of the vermilion edge of the lateral lip element can produce a flap based above on the mucosa of the maxilla. This flap is extremely valuable as a filler for the defect produced during the incising of the lateral vestibular lining when freeing the alar base from the maxilla.

The strategic position of this flap (1) and the ease of its transposition into the vestibular defect have caused it to become standard in this maneuver. When one considers that this tissue has been discarded for centuries, its present salvage is an important step making alar release possible without secondary contracture.

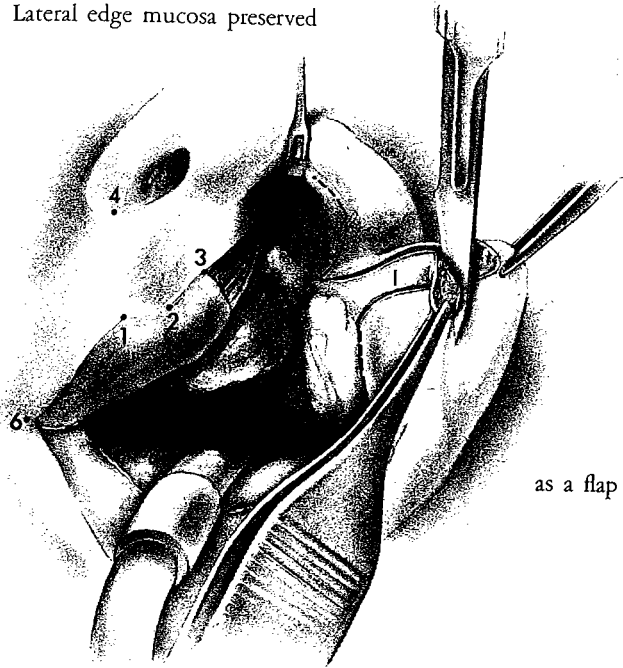


Lateral edge mucosal flap 1 fits into this lateral vestibular defect and maintains nasal ala advancement against contracture.

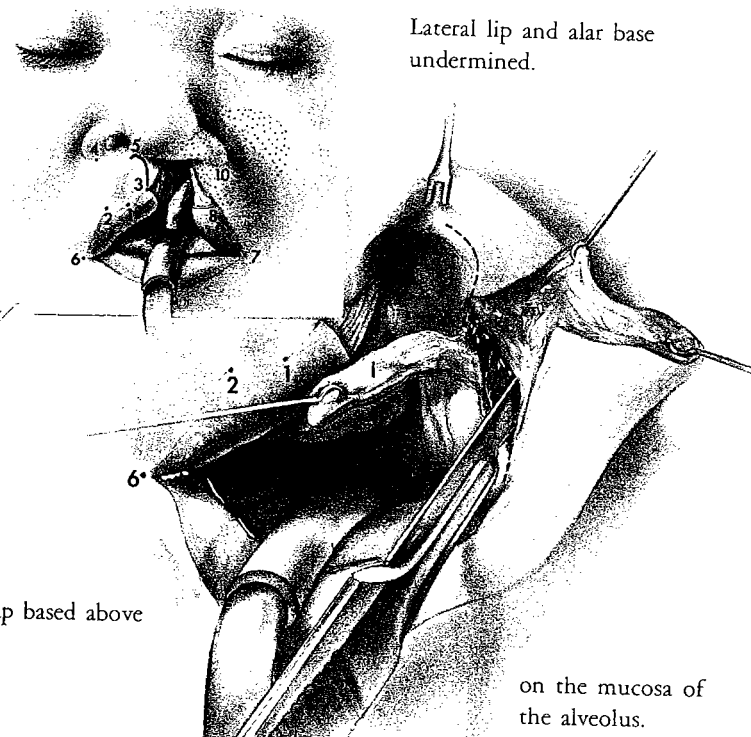
I like using flap 1 during the adhesion

A preliminary adhesion procedure is being used in almost all complete unilateral clefts at about 3 weeks of age. It is now standard at the time of this adhesion to insert flap 1 of the cleft edge vermilion from the lateral lip element into the lateral vestibular defect after release of the alar base from the maxilla. This freshens one lip edge for the adhesion and lets the nose and alar base come forward early without threat of back contracture.

Lateral edge mucosa preserved

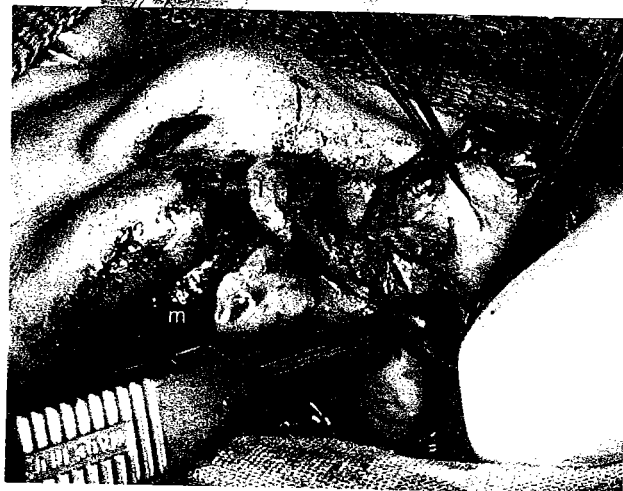
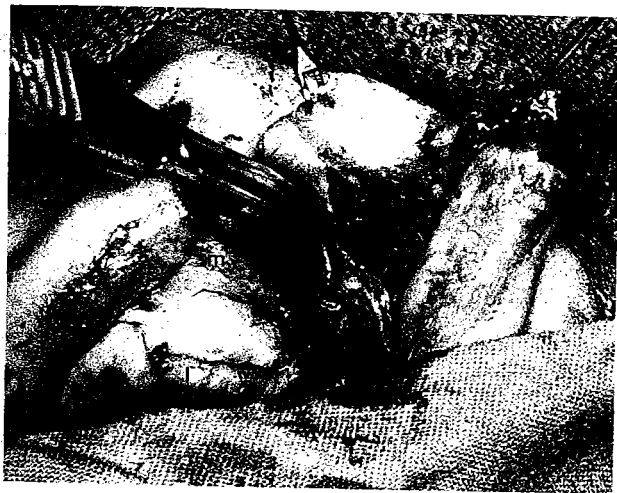
Lateral lip and alar base undermined.

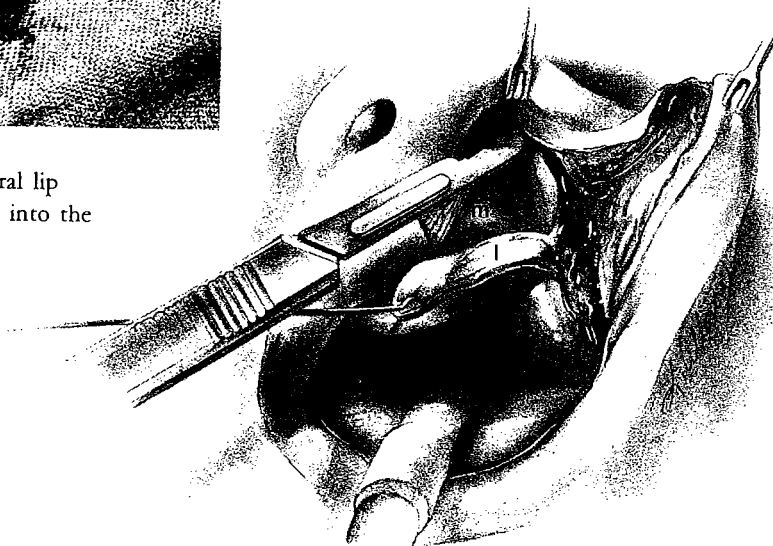


as a flap based above

on the mucosa of the alveolus.

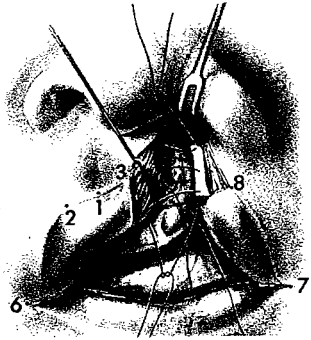
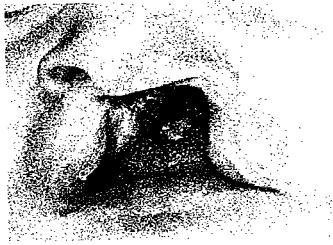

Release of alar base and lateral lip undermining is extended up into the nasal vestibule.



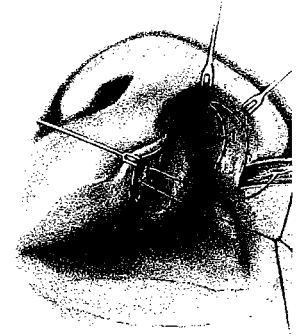
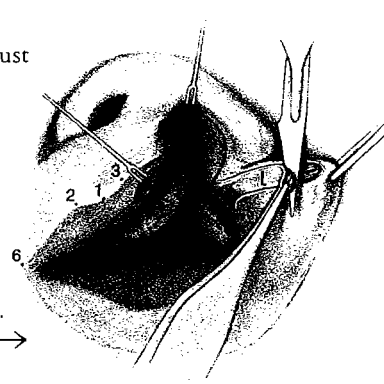
PRESENT APPROACH IN COMPLETE CLEFTS

In most complete clefts today, an adhesion is created in the early weeks as shown here, preferably using flap 1.



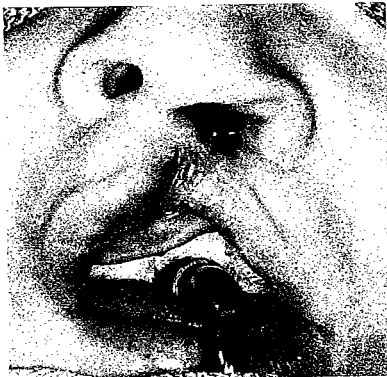All landmarks must be preserved.

Lateral mucosal flap slid under medial element, or preferably flap 1 shifted into nasal lining.

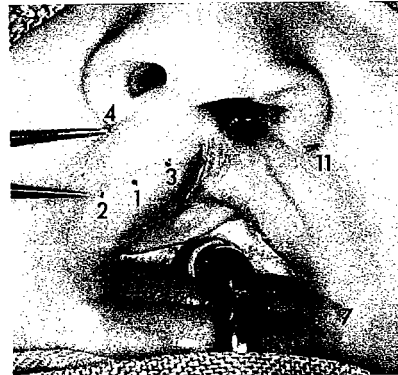


Medial lip element freed from the maxilla but lateral element left attached when possible. Mucosal flap dissected from lateral element and used to advantage. Adhesion sutured in three layers.

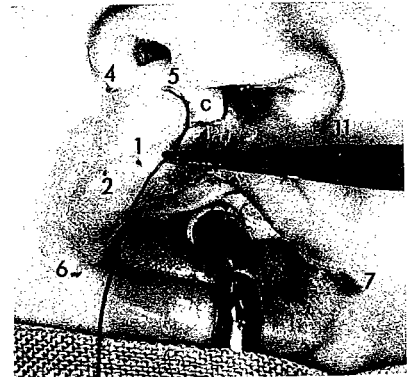
Then, at six to eight months of age, the rotation-advancement operation is carried out. First the rotation and then the advancement incisions are marked. Thus the "in-between" mucosa and scar tissue of the adhesion are left to be marked as (m) and (l) flaps, but are not as important if 1 flap already used in adhesion.



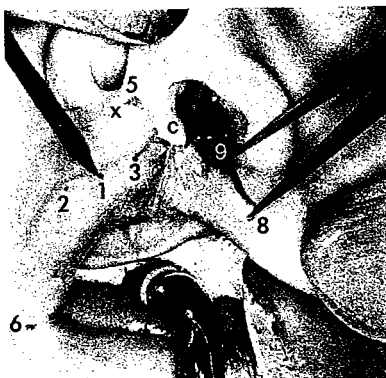
Adhesion preserves landmarks.



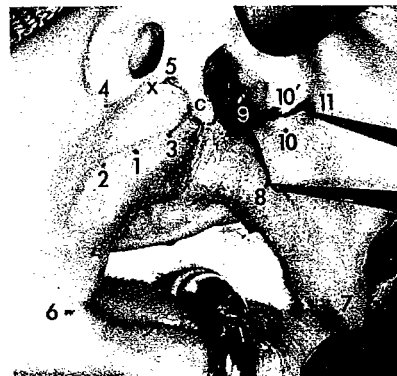
Marking the bow and measuring the height.



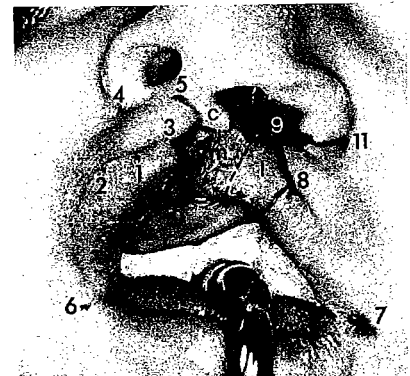Wire-measuring rotation incision.



Rotation marked and advancement edge measured.

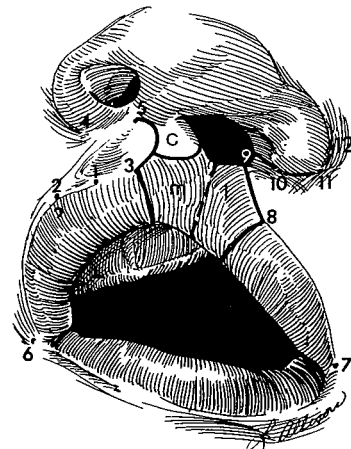


Vertical height on cleft side is short

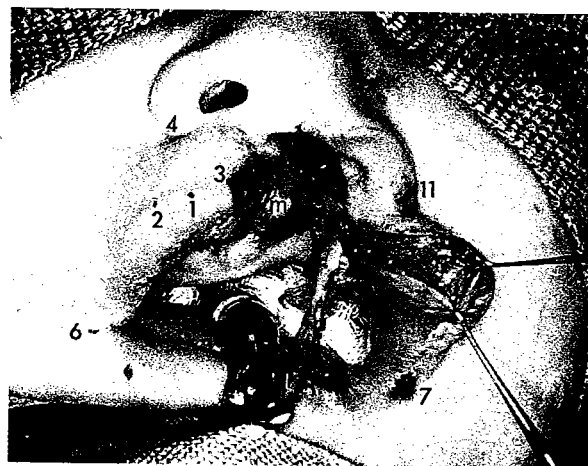
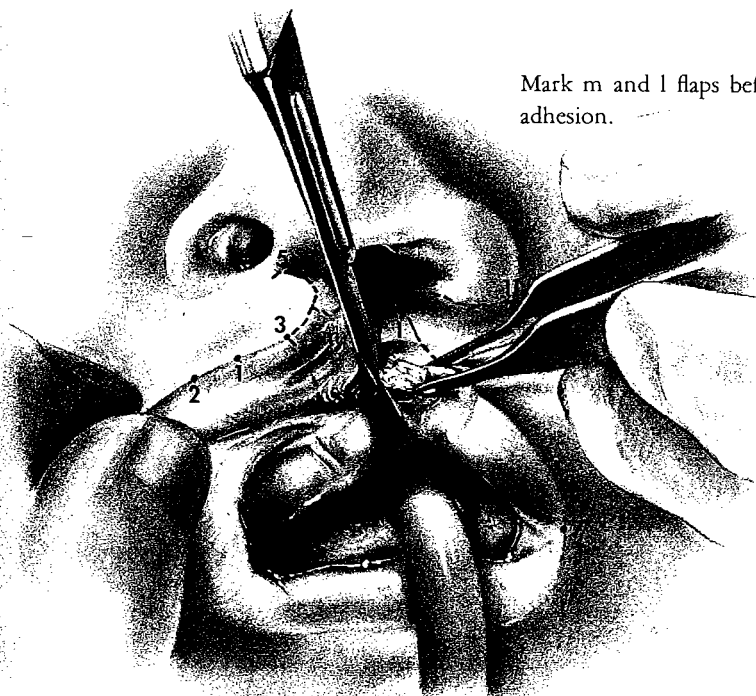


so portion of alar base is included in the lip flap.


Then the adhesion is divided down its center between the two flaps to open the lip for full exposure of the cleft. The two "adhesion-edge paring" flaps (m and l) are dissected free and left dangling temporarily.



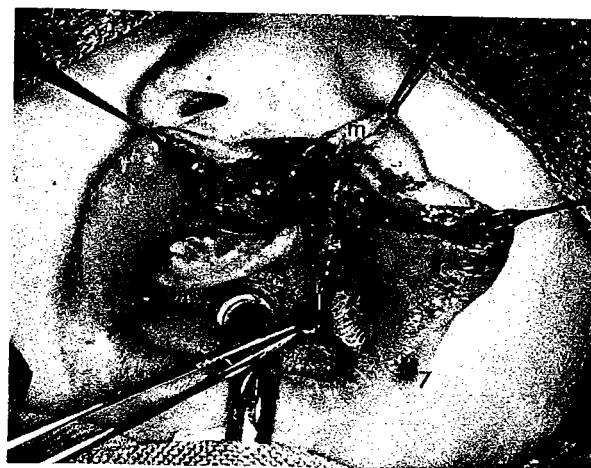
Mark m and l flaps before dividing adhesion.



Flaps m and l are cut.

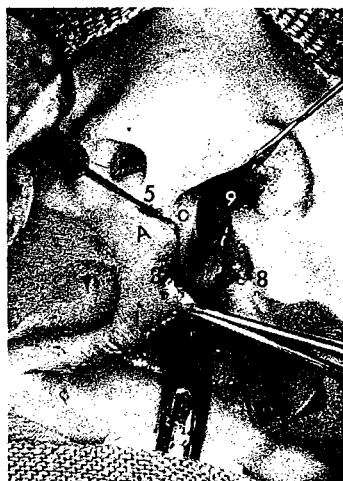

They are left dangling ready for use later.

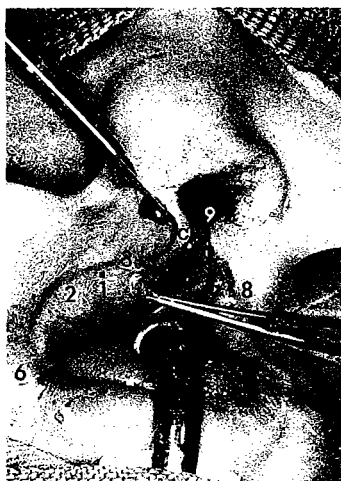

ROTATION

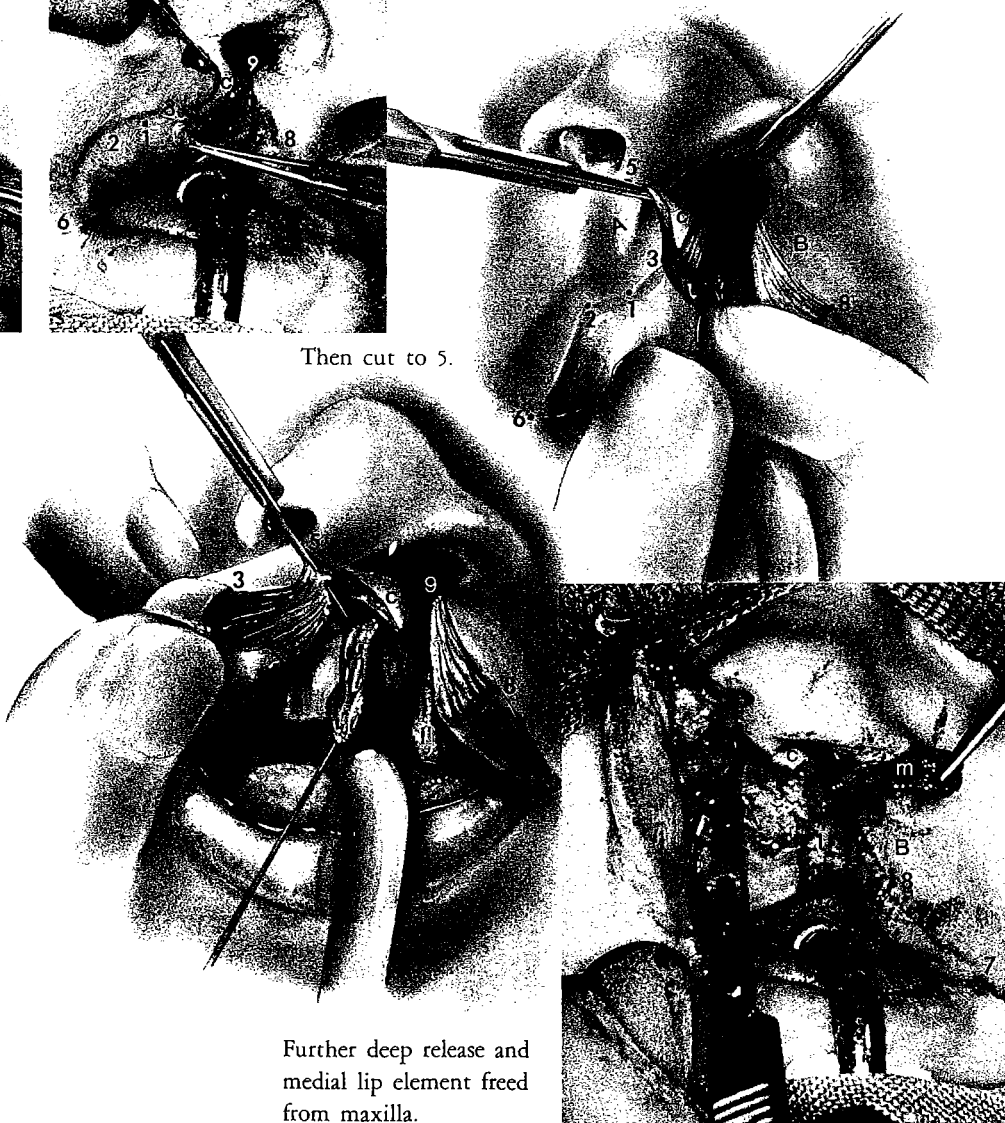
Score the rotation incision first. Then pick up the medial lip element A with your left thumb and index finger and lift it free so that a #11 Parker blade can be stabbed completely through the full thickness of the lip along the scored rotation line. It is usually easier to start at point 3. The scalpel should be slanted on the bias to retain as much muscle and mucosa in the lip as possible. This maneuver will join the previous cleft edge paring already accomplished.



Rotation incision scored.



Then cut to 5.

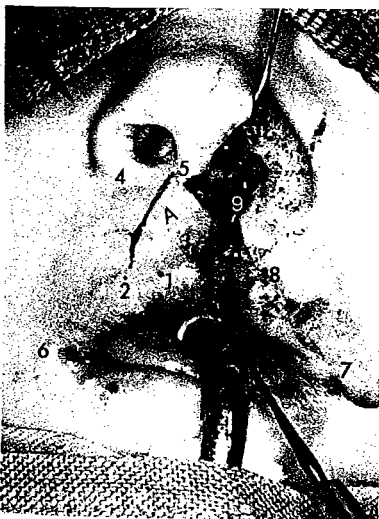

Further deep release and medial lip element freed from maxilla.

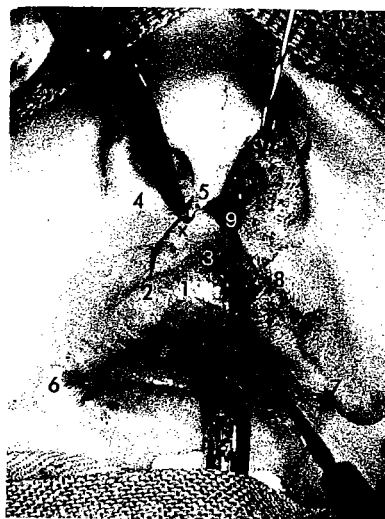The amount of required rotation depends directly upon the difference in vertical height of the cupid's bow peaks on the normal side at point 2 and the cleft side at point 3 of the medial lip element. As soon as the rotation incision has been cut to point 5, the position of A should be tested to see if the drop has been adequate to line up the peaks of the bow on an equal horizontal plane. Further stabbing with the point of the scalpel in the subcutaneous tissue and muscle attachments will increase the release. Then, with care to avoid the base of the mucosal edge flap (m), undermine the medial lip element free from the maxilla a moderate amount to facilitate the rotation.

BACK - CUT

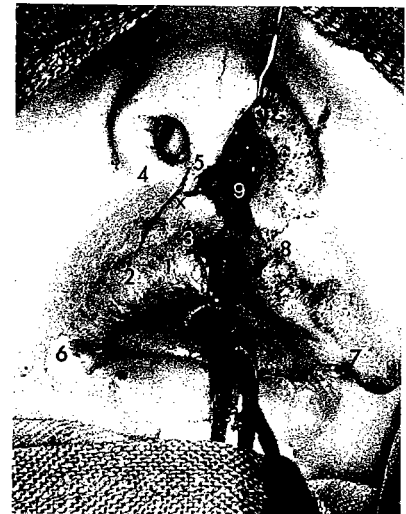After the simple rotation to point 5 and the undermining, there is usually a slight discrepancy in the downward positioning of flap A with its cupid's bow and philtrum dimple. Here the back-cut makes its triumphant entry. The back-cut checks the transverse direction of the incision as it is directed obliquely downward, being pricked with the #11 point a millimeter or two to point x. This approach can make up for a discrepancy in bow peak height of 5, 7 or 8 or more millimeters, so do not panic when the difference is more than the fictitious 3 or 4 mm. cited by some to harass beginners.



Rotation stopped short of the normal philtrum column (marked in ink).



Stick-pricking the back-cut.



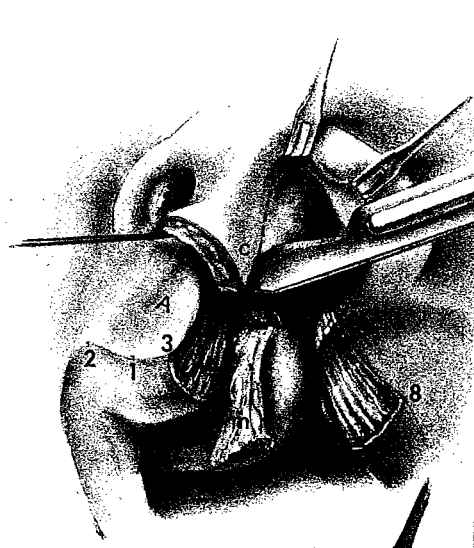
Release after back-cut.

FLAP c

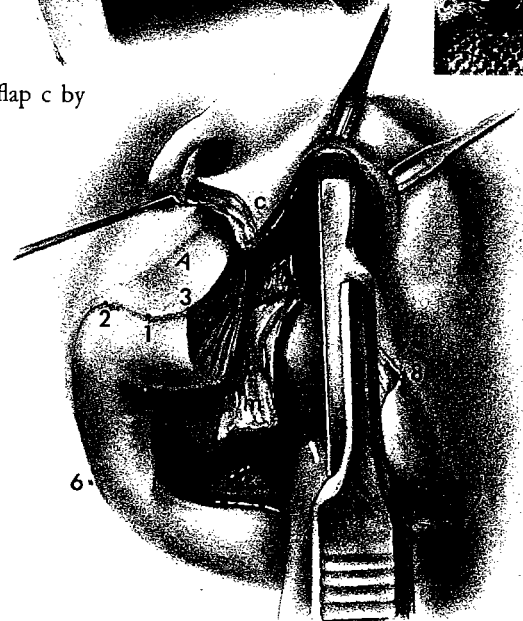
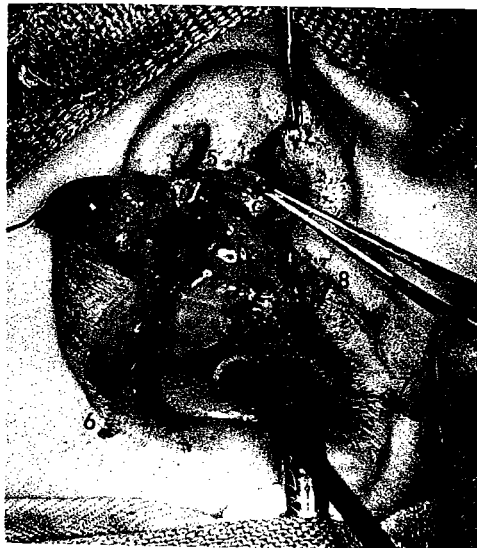The immediate and valuable by-product of the rotation plus back-cut drop of flap A is the freeing of little flap c, which is allowed to rise out of the lip as a one-sided "forked flap." When the slumped alar arch is lifted with a hook to match the normal, a defect opens on the short side of the columella, and flap c naturally moves toward this area. Flap c, which has been pared of its edge mucosa, is further released by an incision posteriorly in the membranous septum on the cleft side all the way up under the nasal tip, allowing flap c to ride even higher. Then, scissor-point dissection between the medial crura of the alar cartilages frees the inferiorly placed cleft side crus to facilitate its advancement ahead of flap c along the short side of the columella. The action of flap c is partly advancement and partly rotation as its trimmed tip actually rises but also swings around into the upper gap of the back-cut. These combined maneuvers enable the construction of a well-balanced, symmetrical columella in its lower two-thirds.



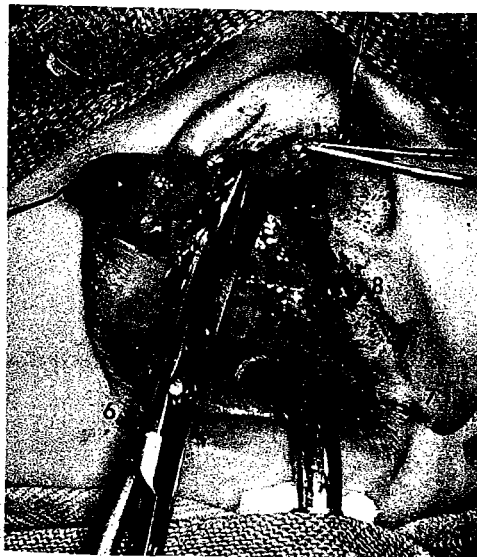Posterior release of flap c by



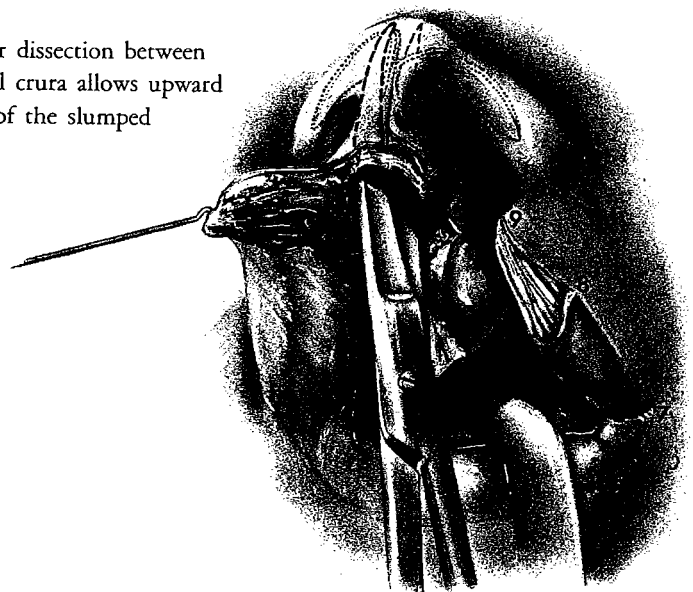
membranous septal incision.



If primary alar lift planned, this incision joins intercartilaginous incision from lateral side.



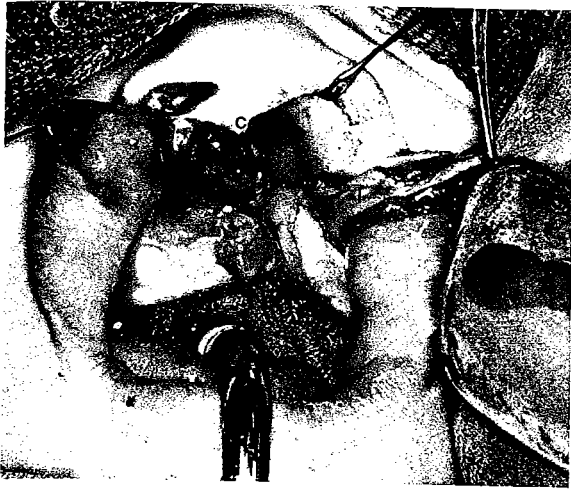
Scissor dissection between medial crura allows upward shift of the slumped side.



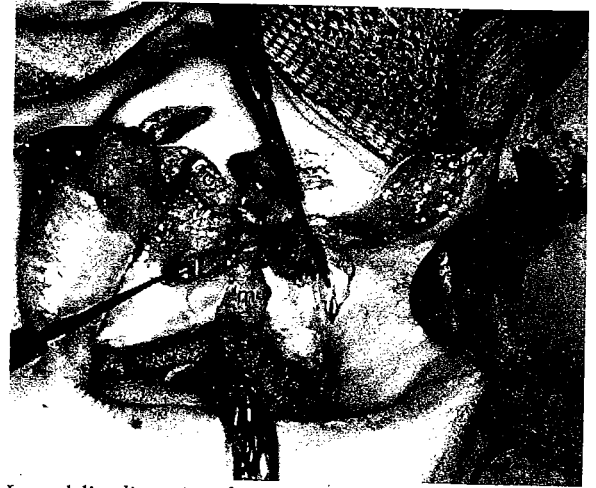FREEDING THE LATERAL ELEMENT

Avoiding the base of the lateral mucosal flap (l), the surgeon dissects the lateral lip element from the maxilla through a releasing incision at the top of the labial sulcus. The soft tissues of the lip and cheek are undermined usually up to the infraorbital foramen and laterally until the lip will advance easily without evidence of tethering. The incision then enters the nasal vestibule, cutting the alar base free from the maxilla, starting laterally at the bony attachments of the pyriform opening and proceeding in an arch up and around along the intercartilaginous line. In many instances this will suffice, but in certain cases the distortion of the nasal tip is so severe that primary correction seems warranted. Then the intercartilaginous incision is extended to join the membranous septal flap c—freeing incision under the nasal tip. This presents the exposure necessary for alar lift.

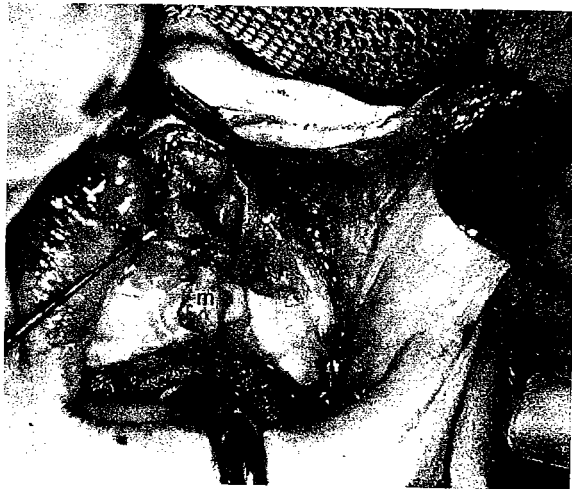If the medial mucosal paring flap (m) is not needed for the second layer of the anterior maxillary cleft closure, it can be draped over the raw maxilla to speed healing and maintain a deeper superior labial sulcus.



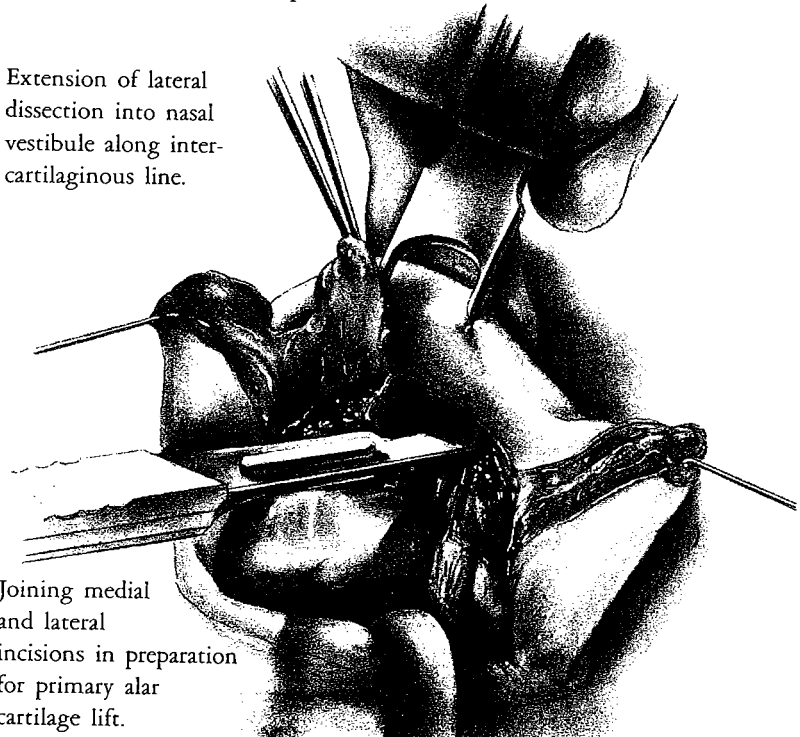
Exposure.



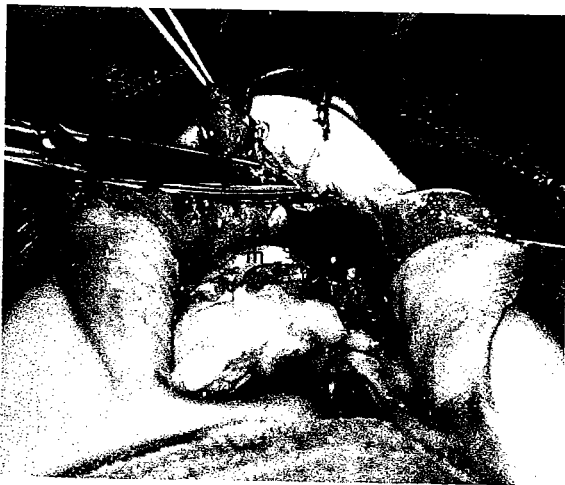
Lateral lip dissection from maxilla.



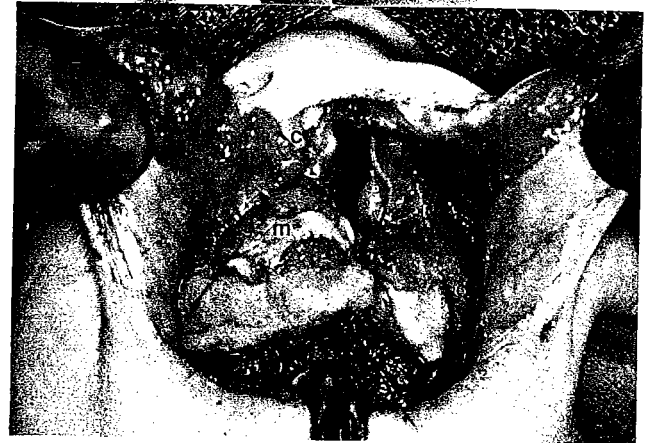Extension of lateral dissection into nasal vestibule along intercartilaginous line.



Joining medial and lateral incisions in preparation for primary alar cartilage lift.

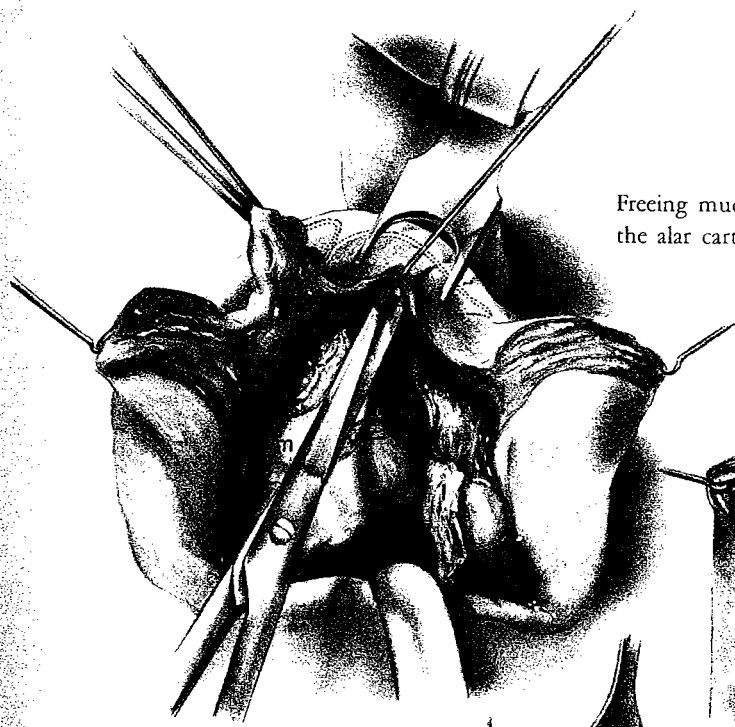


After total vestibular incision.

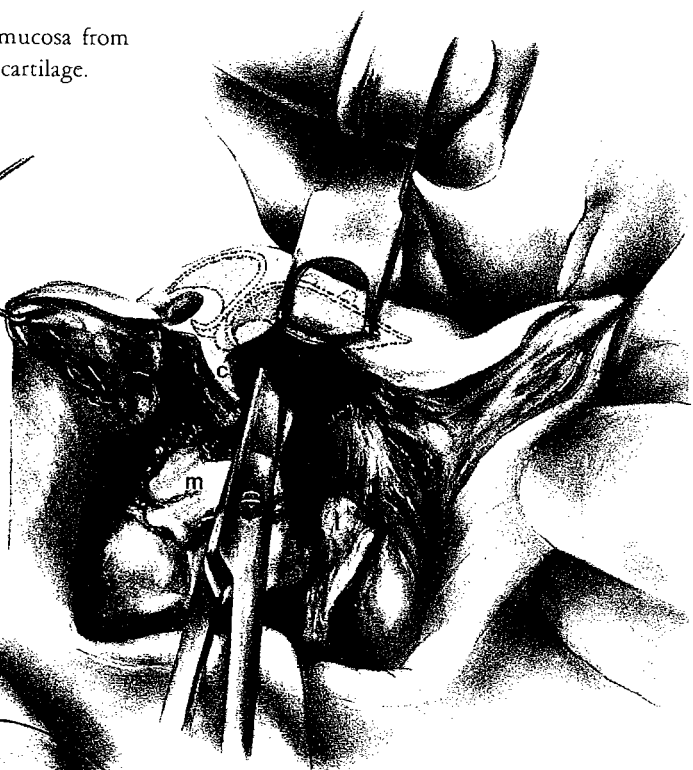


PRIMARY ALAR CARTILAGE CORRECTION

First the mucosa is freed from the undersurface of the alar cartilage for half a centimeter. Then the alar cartilage is freed from its overlying skin with right-angled scissors. Further undermining of nasal skin is continued up over the upper lateral cartilage to the septum and across to the opposite alar cartilage. Then a 4-0 Prolene suture (Ethicon #8603) or a 4-0 Mersilene (Ethicon #765) takes a bite in the upper edge of the septum approximately 1 cm. from the tip and picks up the freed edge of the alar cartilage just lateral to the angle of the crura. As the suture is tied, the alar cartilage is lifted out of its doldrums over the upper lateral cartilage to ride in reasonable symmetry with its normal mate. A second suture from the medial portion of the slumped alar cartilage to the normal opposite alar cartilage sometimes helps in the fixation. Minimal if any mucosa requires trimming prior to suturing with 4-0 catgut.

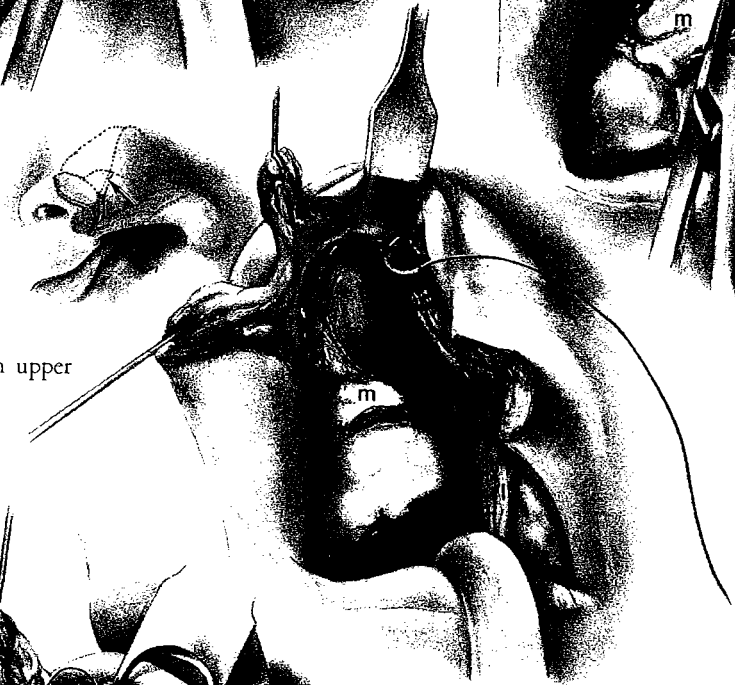


Freeing mucosa from the alar cartilage.

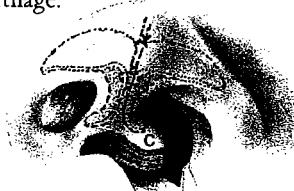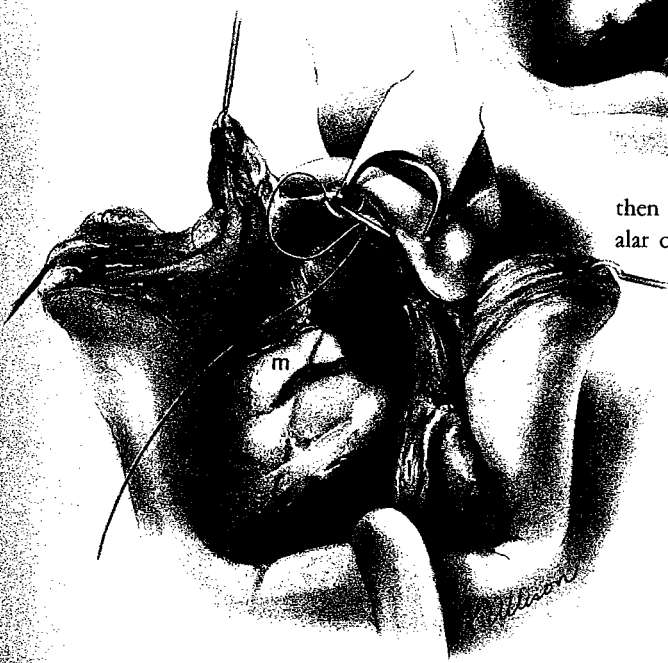


Freeing the alar cartilage from the overlying skin.

Suture placed in upper edge of septum

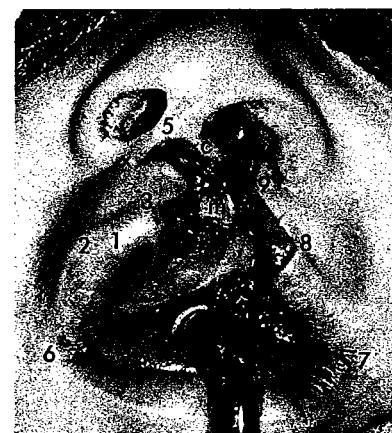

then picks up alar cartilage.



Another suture approximates the angles of the two alar cartilages.

Tying the sutures lifts the alar cartilage into new symmetry with its mate.

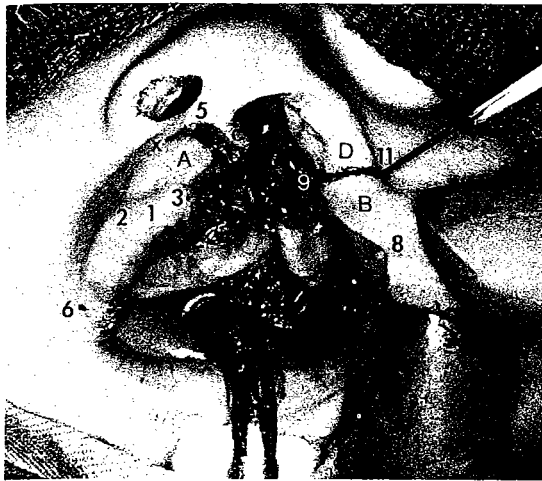


SEPTUM

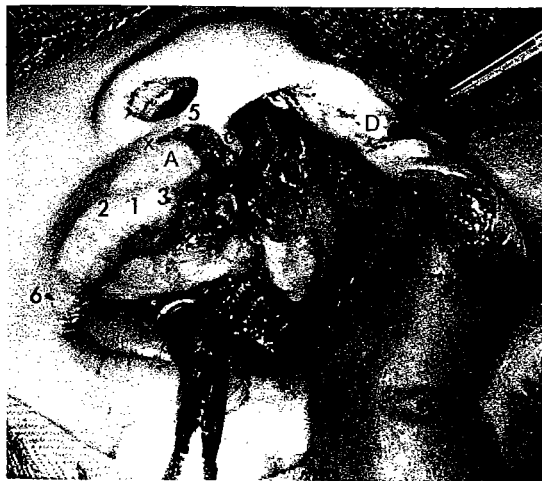If the septum is severely dislocated into the normal nostril at the spine, it can be carefully freed submucosally, scored on its concave side, slipped over the spine and fixed into a straight position in the midline. Excision of the spine may be indicated. Septal dissection during the primary cleft surgery must be conservative but rarely is indicated at this stage of life.

ADVANCEMENT

Pick up the lateral lip element with your left thumb and index finger and again mark the advancement incision. Then, with the #11 B.-P. blade, stab from points 8 to 9 to 10 to 11, cutting on the bias to retain in this lip element all the subcutaneous tissue, muscle and mucosa available. If the alar flare is severe, it may be necessary to extend the incision 9 to 10 to 11 and even to 12 on around the alar base. If the lateral element is diminutive, the tip of the flap at point 9 will have to be extended into the vestibule.

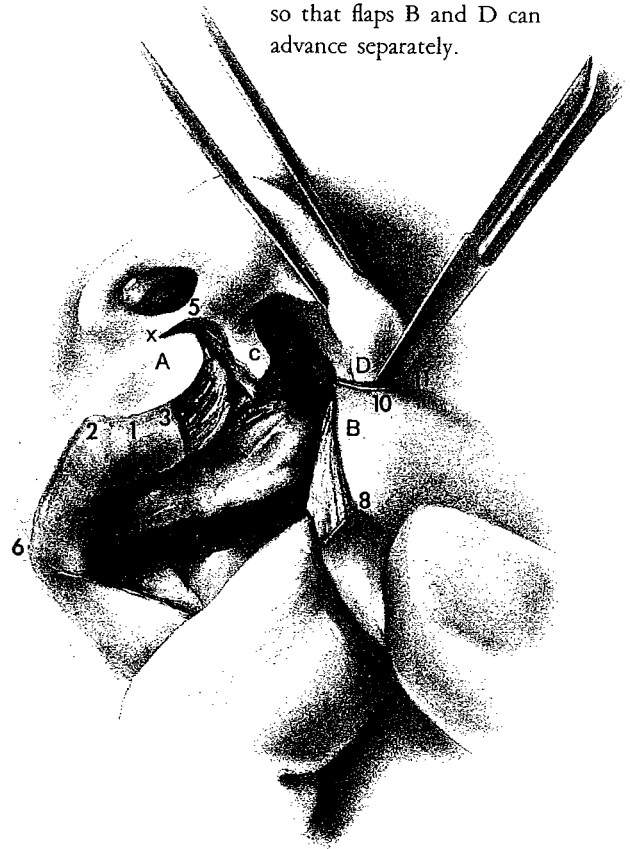


Marking the upper transverse advancement incision.



Stabbing the alar base free from the lateral lip.

Incising the circumalar incision so that flaps B and D can advance separately.

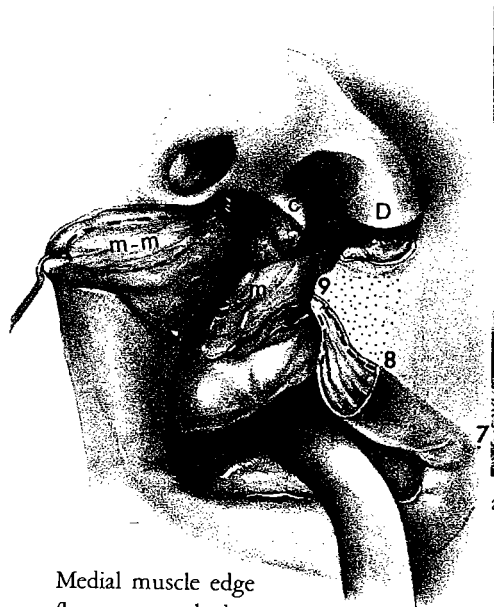

MUSCLE ALIGNMENT

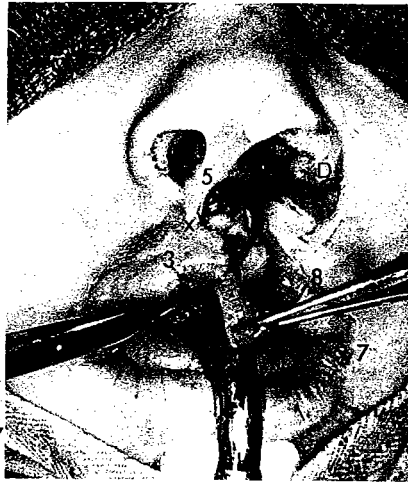The latest refinement is the method of aligning the orbicularis oris muscle. As has already been pointed out, the rotation and back-cut places the orbicularis oris fibers of the medial lip element into true horizontal position. A cleft edge "muscle" flap based above on the medial element not only freshens the muscle edge to healthy end-on fibers and presents a more tailored edge for approximation but creates a "muscle" flap which can serve as a transposition across the cleft into any lateral muscle gap.

The lateral element during its advancement undergoes some degree of rotation-transposition, which improves the original direction of the orbicularis oris fibers. They are not, however, brought down completely by this action into horizontal position. Then too, when there is a bulge in the muscle of this lateral element with attenuation above, more radical dissection seems indicated.

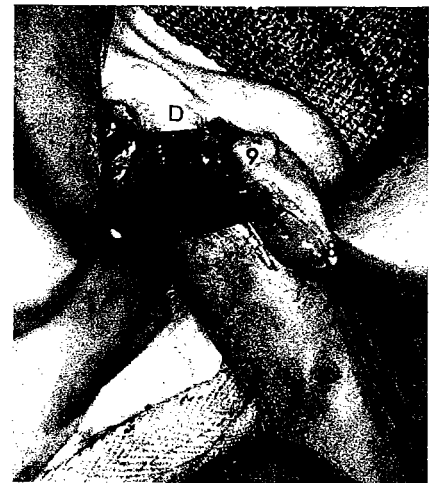Leaving the upper one-half centimeter of lateral lip element intact to be carried by the key stitch into the rotation gap, dissect the lateral lip skin off the orbicularis oris muscle. Then free the muscle from the posterior mucosa so that it can be divided above with scissors and brought down into more nearly perfect horizontal fiber alignment. Of course, a muscle gap will be left above to be filled by the medial edge muscle flap m-m.



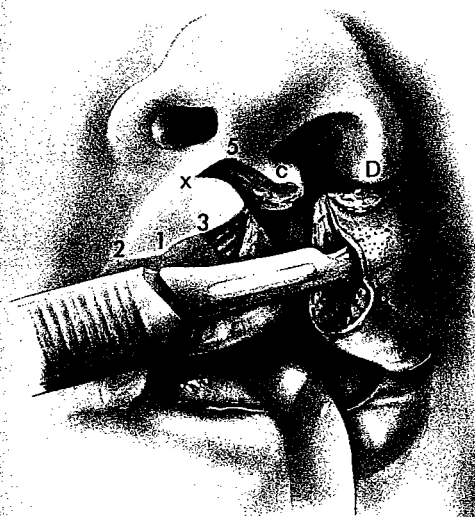
Medial muscle edge
flap m-m marked



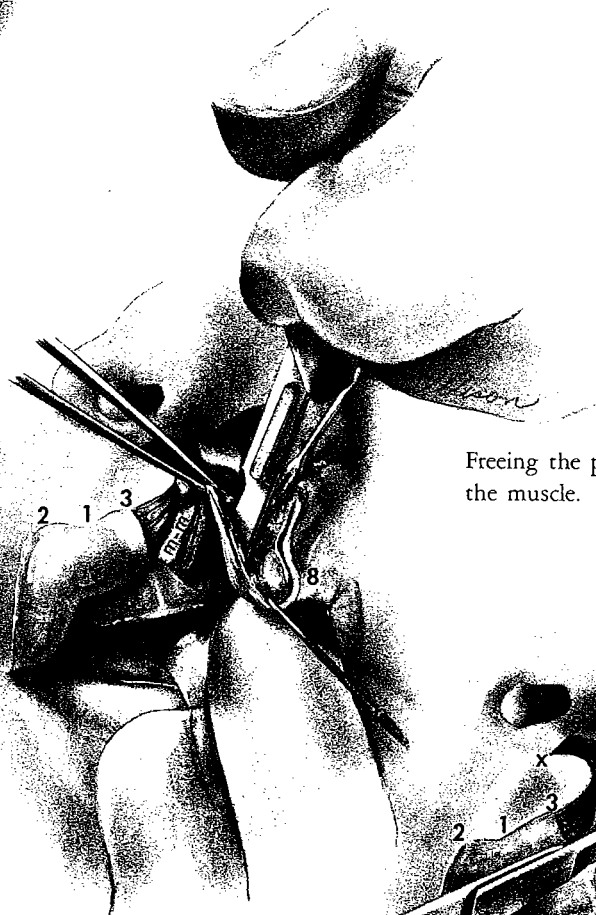
and cut with base above.



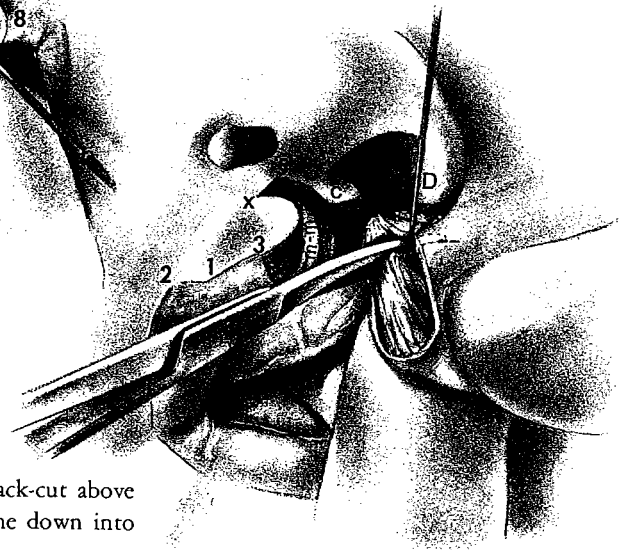
Freeing skin from muscle
of lateral element.



Muscle being undermined
but leaving upper edge
intact.

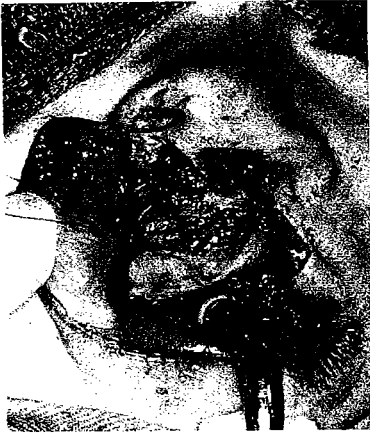

Freeing the posterior mucosa from
the muscle.



Cutting the muscle in back-cut above
to allow its fibers to come down into
alignment.

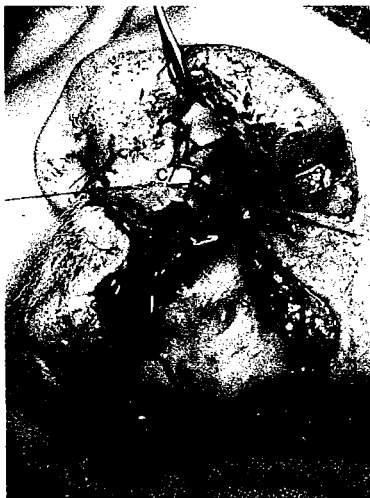SUTURING OF FLAP m



If the maxillary components are within a centimeter of each other and are not abutting, the adhesion with the limiting prosthesis has been successful. A vomerine and premaxillary mucoperiosteal flap is dissected free with its base superior, turned over and sutured with 4-0 chromic catgut (Ethicon #752) to a mucoperiosteal flap from the lateral cleft edge. Closure of the nasal floor and nasal closure of the alveolar and anterior hard palate cleft are thus achieved. The mucosal flap (m) pared from the medial cleft edge carrying most of the adhesion scar is used as a second, oral layer to this closure, as already illustrated. If the hard palate edge flaps are turned the other way, flap m can be used to supply the second layer on the nasal side.

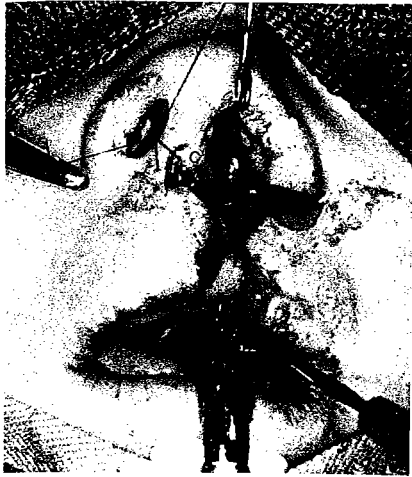If the alveolar and anterior hard palate cleft is not going to be closed at this time or the medial flap m is too short, it can be used to cover the raw area of the anterior alveolus to preserve the upper labial sulcus. This is often sutured earlier, before the alar lift, in order to get the mucosal flap out of the way.

SUTURING OF FLAPS c AND l

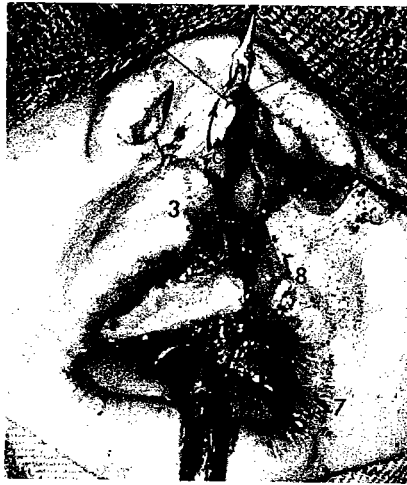

As flap c advances into the columella and rotates into the back-cut, it is fixed in front with two or three sutures of 6-0 silk (Ethicon #780) in the skin of the mid-columella. Then the posterior edge of flap c is advanced along the membranous septum with 5-0 chromic catgut (Ethicon #792). This maneuver enables flap c to contribute to the construction of the cleft side columella and its base to achieve symmetry.

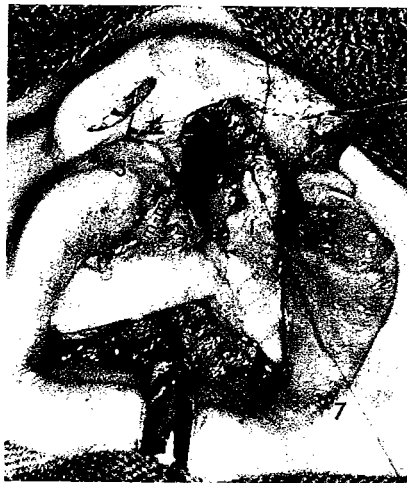The lateral mucosal paring flap (l) is sutured with 4-0 catgut into the lateral nasal vestibular defect, extending as far as possible up along the line of the intercartilaginous release. This will maintain the forward position of the alar base.



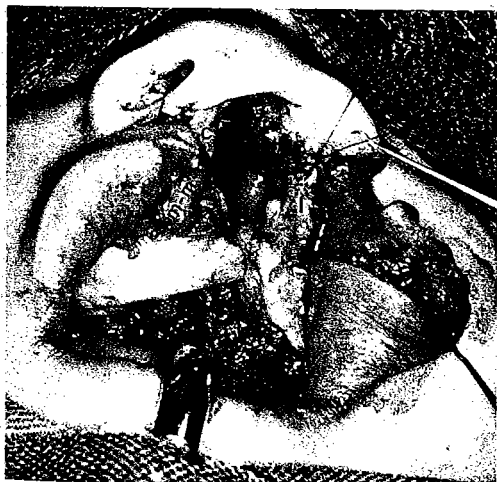
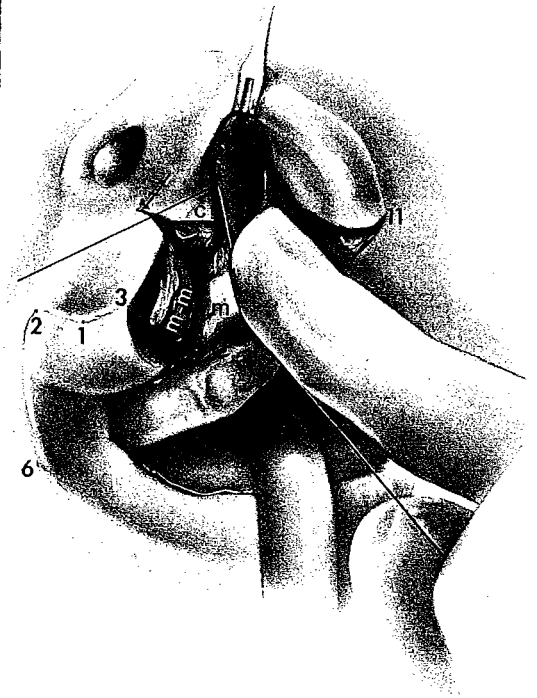
Suturing the rotation of flap c into upper back-cut.



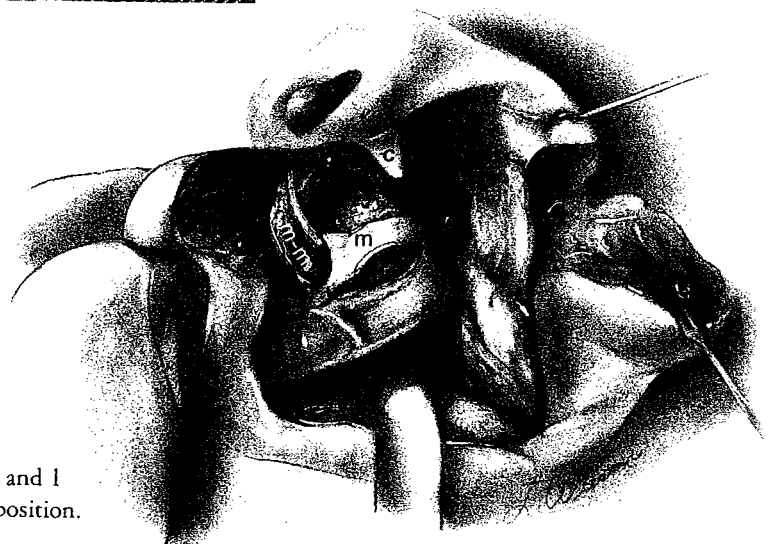
Suturing the membranous septum as flap c advances upward as a one-sided "forked flap" for columella lengthening.



Lateral mucosal paring flap l being sutured into the lateral nasal vestibular defect to maintain the release of the alar base.

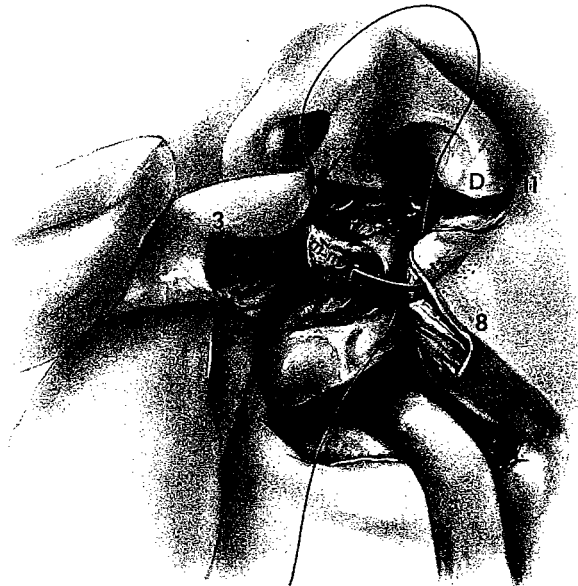


Flaps c and l are in position.

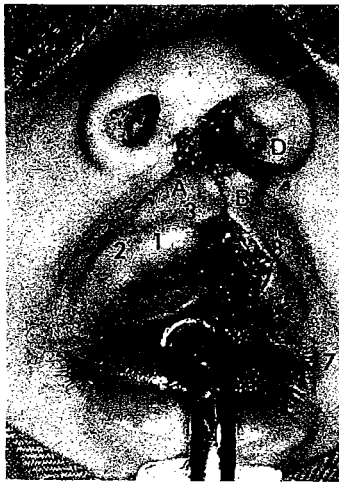

KEY STITCH

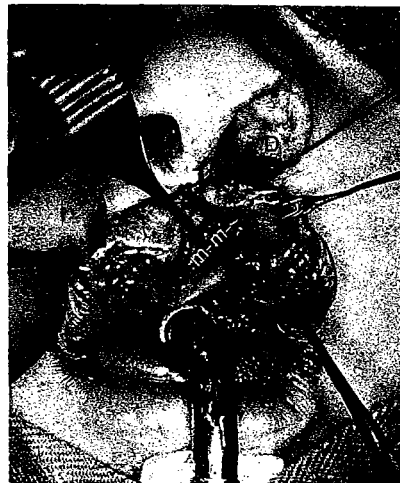Rotation of flap A down, advancement of little flap c up and release of alar base have set the stage for advancement of flap B into the rotation gap. A good bite of the deep tissue of the tip of the advancement flap B is taken with a 4-0 white Prolene or 4-0 Mersilene, and then a similar good bite is taken in the depth of the rotation gap at the bottom of the back-cut. Remember that this stitch determines the amount of rotation and if placed too low can pull up on this element to the detriment of the final resting place of the cupid's bow. It is a trial and error stitch and should be placed and replaced until absolutely correct, for upon it "hang all the Law and the Prophets."



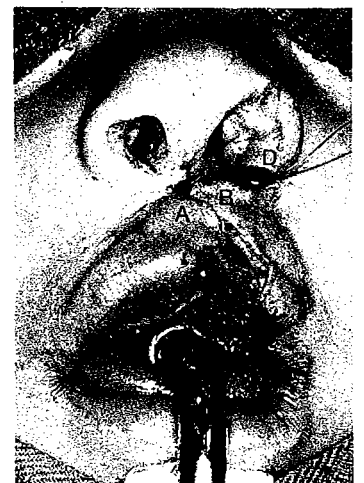The key stitch first picks up the subcutaneous tissue of the tip of the advancement flap and then takes a bite in the depth the back-cut above flap m-m.



Tying this stitch brings flap B into the rotation gap.



The medial muscle edge flap m-m is transposed into the high muscle defect of the lateral element (*arrow*).



The muscle edge flap is guided into the defect with a pull-through suture coming out the upper edge near the alar base.

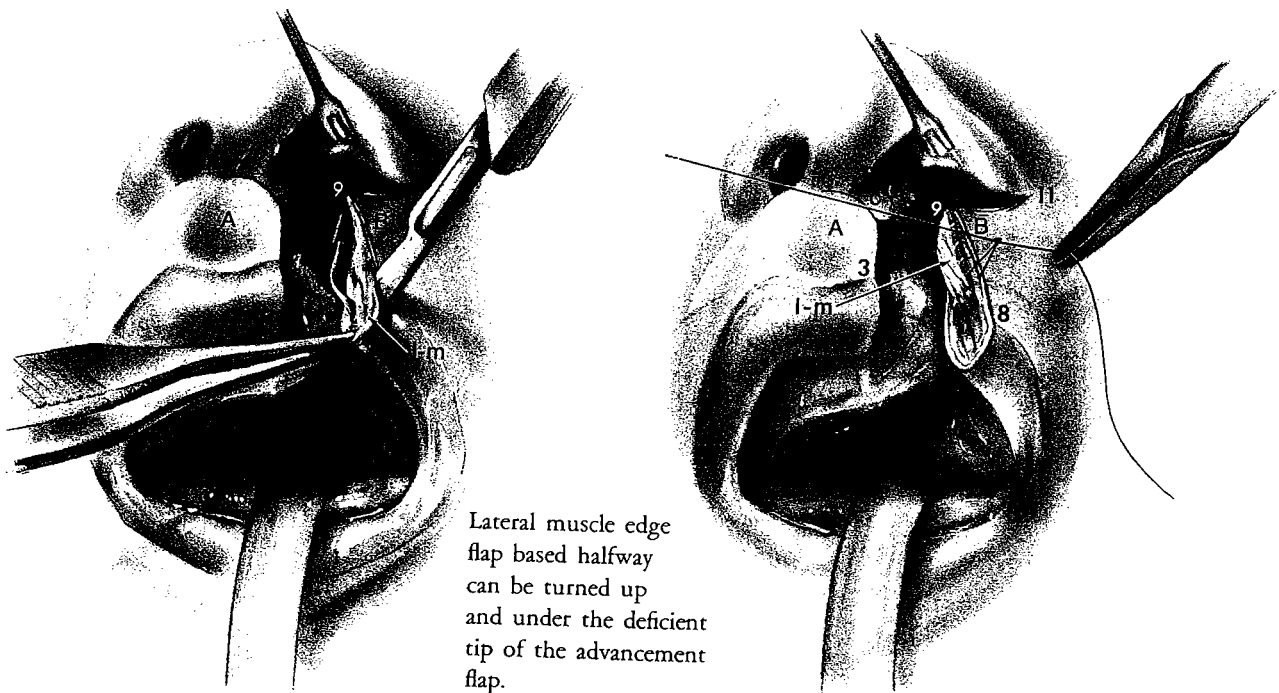
INSERTING THE MUSCLE EDGE FLAPS

Next the medial muscle flap m-m is guided by a 4-0 chromic catgut pull-through suture from the upper raw edge of flap B across the cleft into the muscle gap in this lateral lip flap.

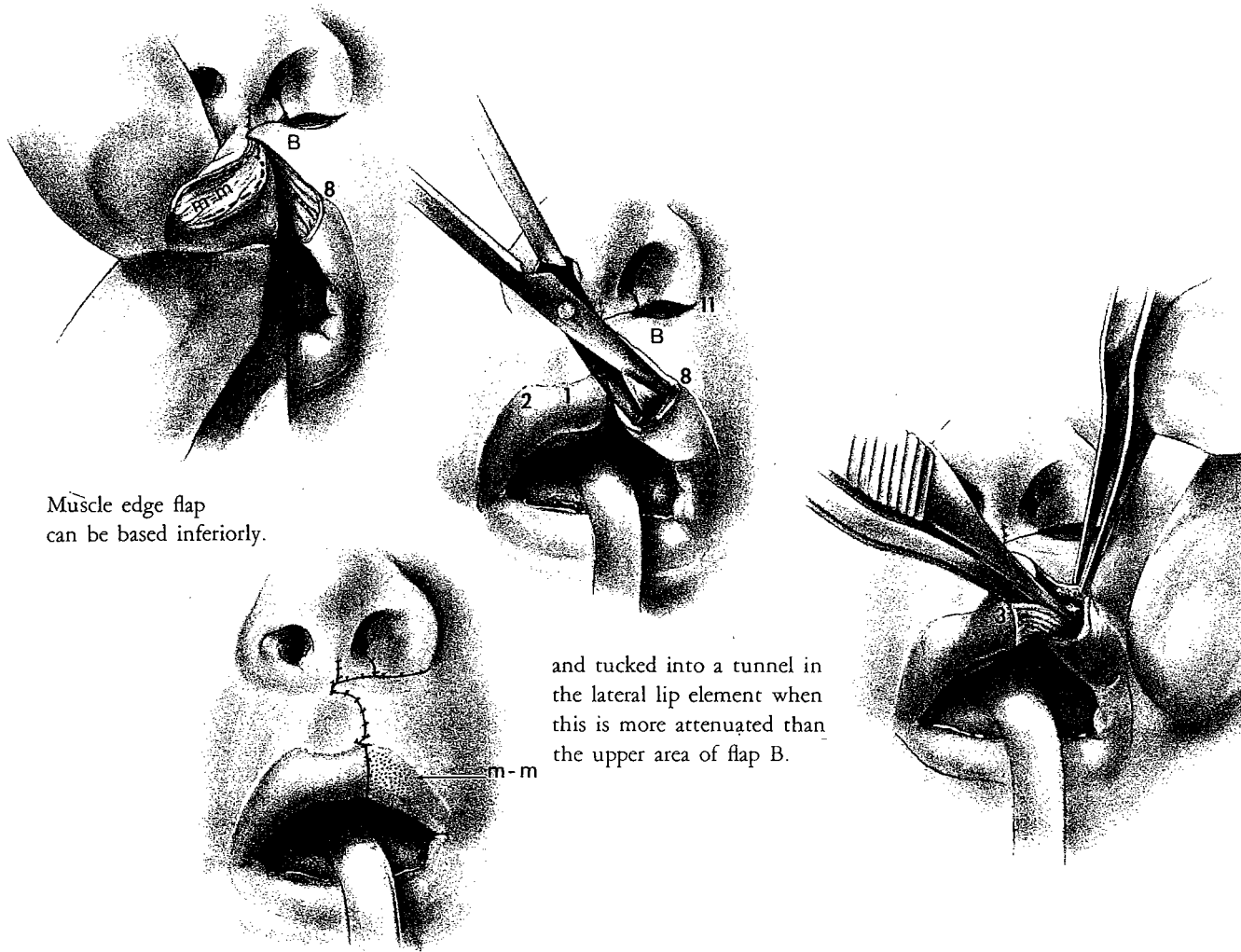
OTHER CLEFT EDGE MUSCLE FLAPS

If a muscle bulge of the cleft edges is present—usually a result of the method of mucosal paring—then these must be reduced to ease the fitting. This trimming can be salvaged as muscle flaps for use in various ways. Probably it is most important where, as already described, the muscle flap is taken from the medial cleft edge based superiorly and used to cross the cleft to make up for deficiency in muscle, a groove or an actual gap in the upper area of the lateral lip element.

The muscle flap has been taken from the lateral cleft edge l-m and tucked under itself to bolster the thin tip of its own advancement flap. This can be quite effective.



It can be taken from the opposite medial side m-m based inferiorly and inserted "tongue in tunnel" to add body to an attenuated lateral vermilion border.

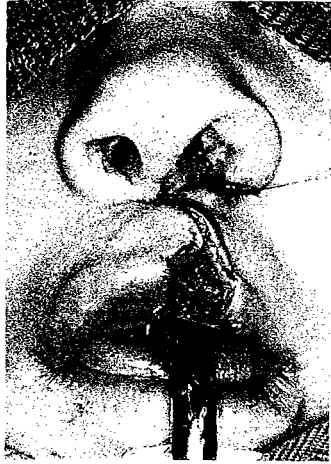

Muscle edge flap
can be based inferiorly.

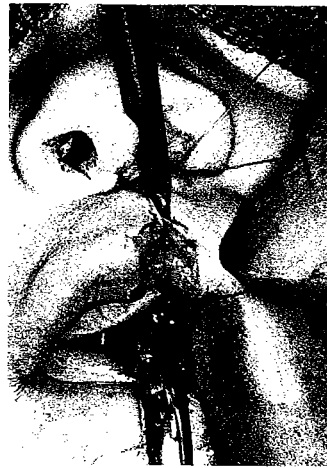and tucked into a tunnel in
the lateral lip element when
this is more attenuated than
the upper area of flap B.

PREPARATION OF THE CLEFT EDGES

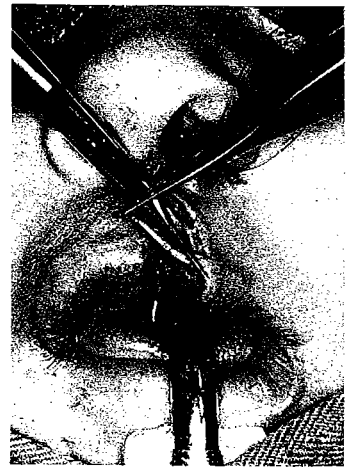For the scar of union to simulate the curve of the philtrum on the normal side, it should have a convexity laterally. Thus, the natural convexity of the rotation edge is ideal and only an exaggeration need be trimmed. The usual convexity of the lateral edge is not desirable as two convexities do not fit. A curved excision of skin from the lateral edge is therefore called for, to produce a gentle concavity. This will increase the length of the edge slightly and reduce the need for extra paring. Thus, the skin excesses are marked and then the lateral edge is trimmed to a concavity with scalpel and scissors, the 2 mm. by 1 to 1.5 mm. "white roll" flap of mucocutaneous junction ridge being



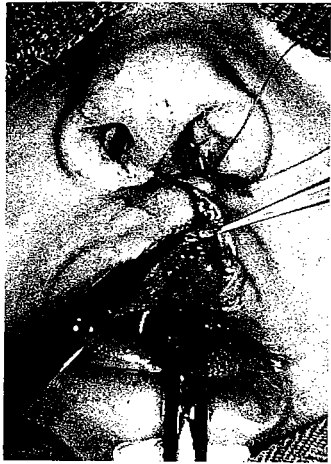The excess of the skin edges marked.



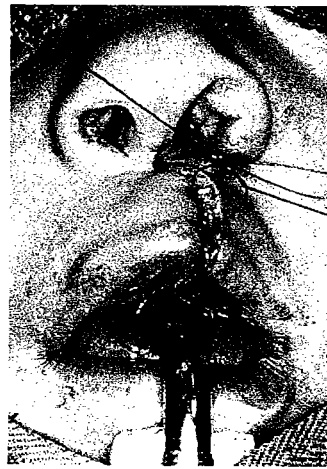Trimming the lateral edge.



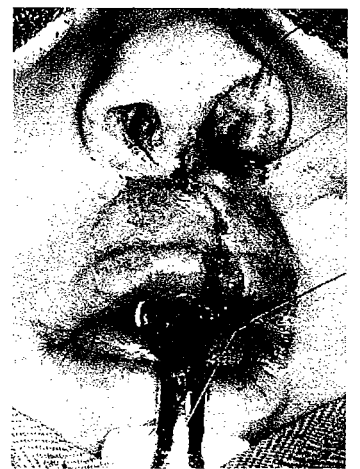Preserving the white roll flap.



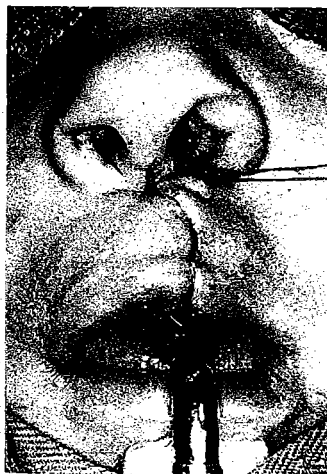Trimming the medial edge.



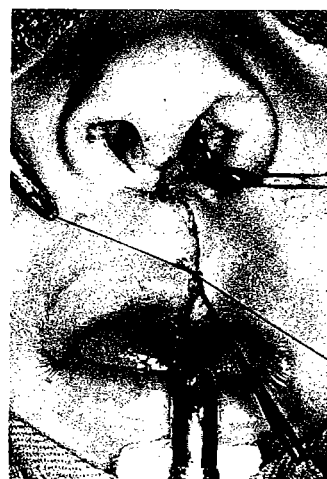Suturing the muscle fibers end-on.



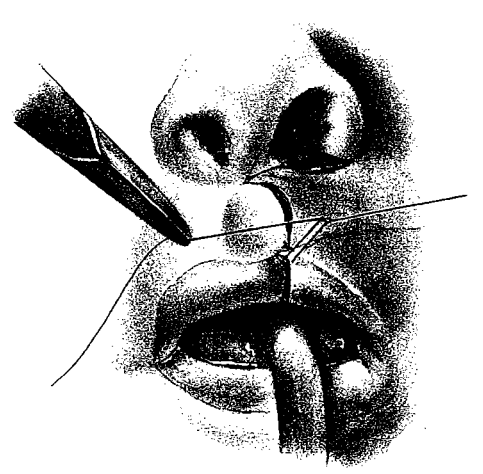
Suturing the free border muscle.



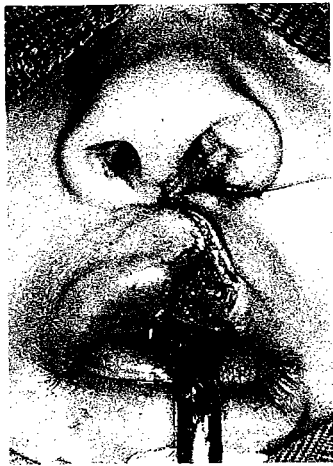Ready for skin suturing.



Suture placed just above white roll flap.



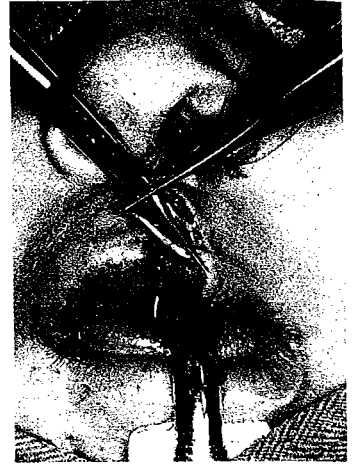Another suture placed in vermillion just below white roll flap.



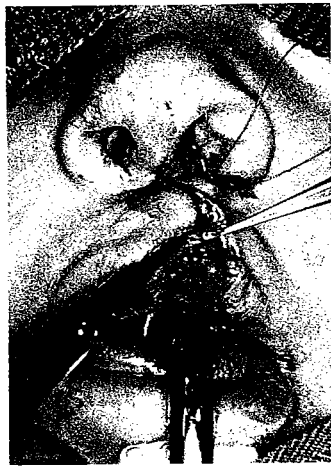The excess of the skin edges marked.



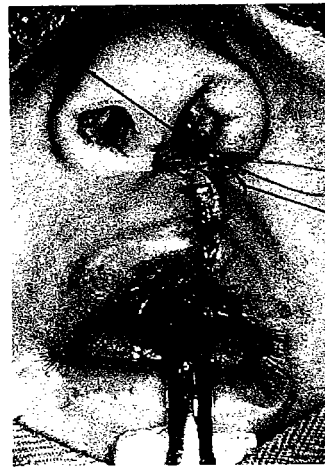Trimming the lateral edge.



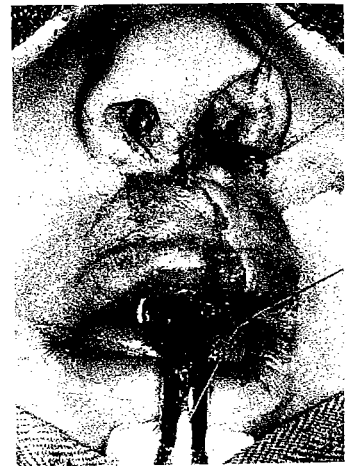Preserving the white roll flap.



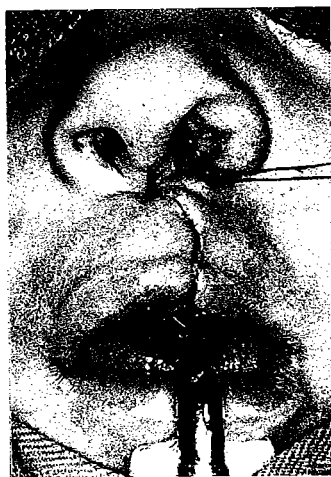Trimming the medial edge.



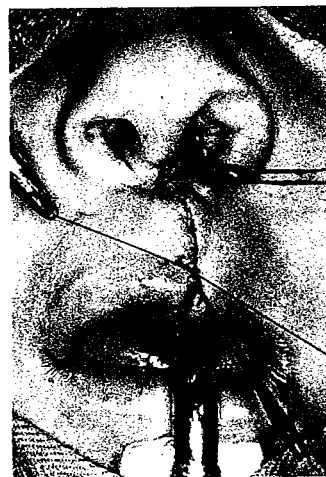Suturing the muscle fibers end-on.



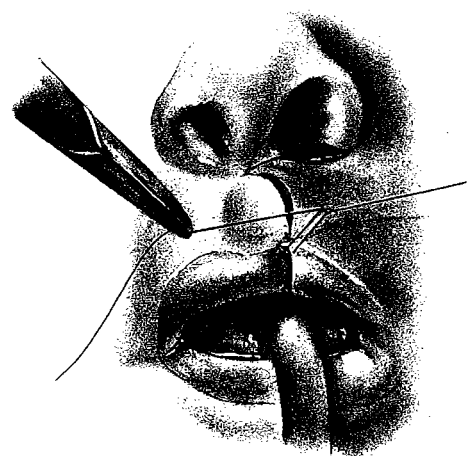
Suturing the free border muscle.



Ready for skin suturing.



Suture placed just above white roll flap.



Another suture placed in vermillion just below white roll flap.

preserved on the lateral element. The medial skin edge is tailored only slightly but maintained as a convexity. Then the dermis and mucosa on either side of the orbicularis oris muscle along both edges of the cleft are freed a millimeter or two to facilitate three-layer closure.

THREE-LAYER CLOSURE

First, closure of the advancement incision in the upper labial sulcus is achieved with 4-0 chromic catgut sutures in the mucosa. Then, staunch approximation of the muscle fibers end-on across the cleft is accomplished with 4-0 Mersilene. It is important to bring the muscle of the vermilion border (*pars marginalis*) together at the very edge with authority.

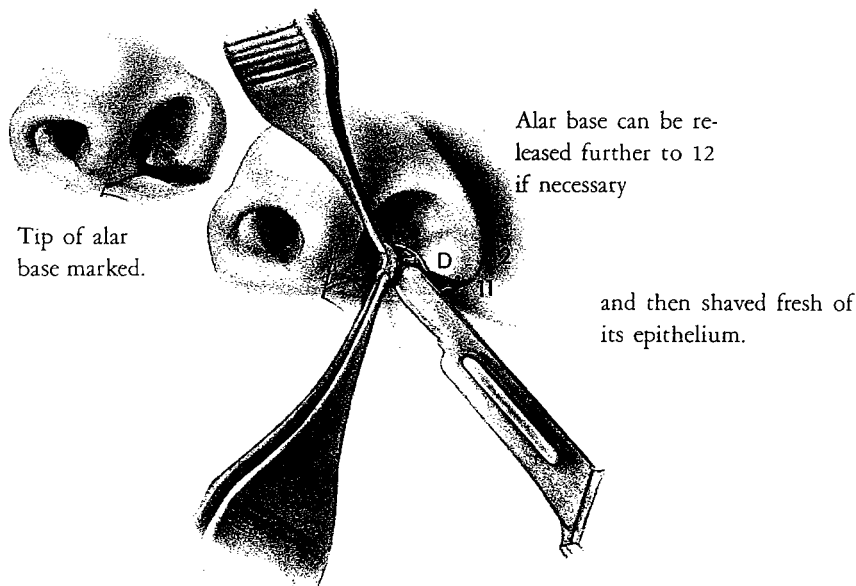
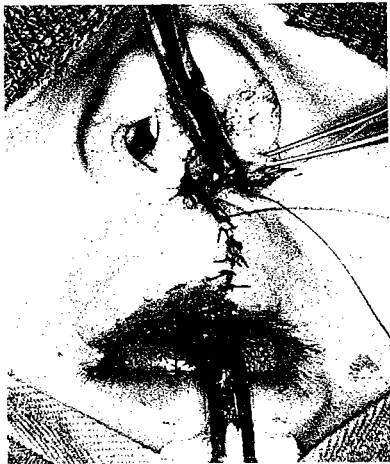Although the white roll flap was cut during the early paring, in actual practice it often has to be discarded. After placement of the key stitch, the lateral lip segment, which was relatively contracted before the stitch, stretches out with an increase in the distance from point 7 to 8. This calls for a slight shifting of point 8 laterally to match 6 to 2 on the normal side, offering two dividends. It allows a millimeter or two more of lateral paring with additional length to this edge—usually a little short. During the paring it allows a new cutting of the white roll mucocutaneous ridge flap, which at this point is quite well developed in the lip. A 6-0 silk suture is placed in the skin just above the future position of the white roll flap interdigitation, and another is placed just below in the vermilion. Thus the white roll flap is fixed in overlap position along the mucocutaneous ridge, which is now ready for interdigitation. The actual insertion is still postponed.

The remaining 6-0 silk skin sutures can be placed in the lip and 6-0 catgut (Ethicon #790) in the free border vermilion until out of sight around under the edge. At this point 4-0 chromic catgut sutures are used to close the posterior mucosa, taking some muscle in the bites. When there is an excess of posterior mucosa, it is usually interdigitated across the straight-line closure. The details vary in every case, but invariably some type of mucosal interdigitation posteriorly out of sight is used.

PREPARING AND FIXING THE ALAR BASE

In order to correct the outward rotation and flare of the alar base and at the same time the unnatural width of the nasal floor and to prevent subsequent lateral shift of the ala, a method has been devised which is proving to be effective.

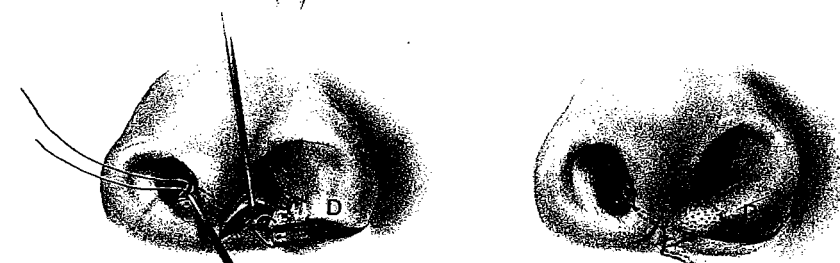
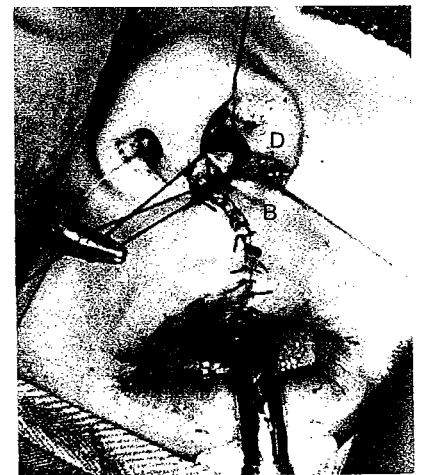The circumalar incision 9-10-11-12 has freed the alar base as flap D from the lateral lip flap B. It is now able to rotate medially and independently of the advancement flap B. It will, in fact, *out-advance* the *advancement*. The tip of this flap is denuded of epithelium for several millimeters, so that it can be pinned with a 4-0 white Prolene or 4-0 Mersilene suture to the area of the septum near the nasal spine under the tip of flap c. By eye and suture, the alar bases should be set up in nearly perfect symmetry. Then, subcutaneous sutures approximate the alar base in its new advanced position to the upper edge of the lip advancement flap B.



Tip of alar base marked.

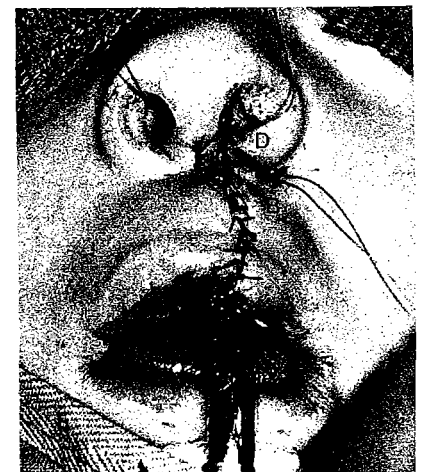Alar base can be released further to 12 if necessary

and then shaved fresh of its epithelium.



Through a stab incision on the opposite side near the edge of the septum a 4-0 Mersilene suture comes across picking up the tip of the denuded alar base.

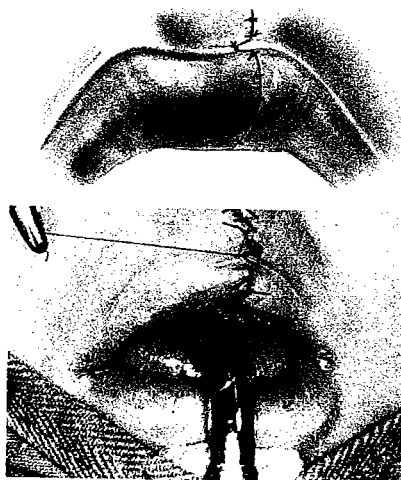
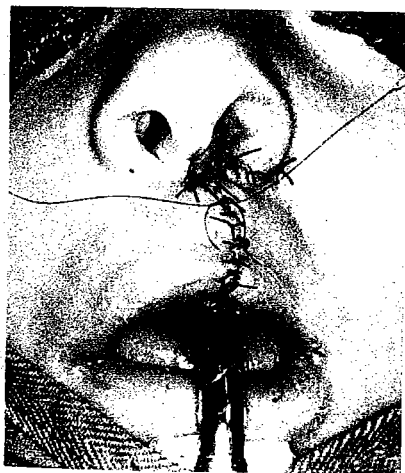
As this permanent suture is tied, the raw tip of the alar base is pulled under the lateral tip of flap c and fixed to the septum.



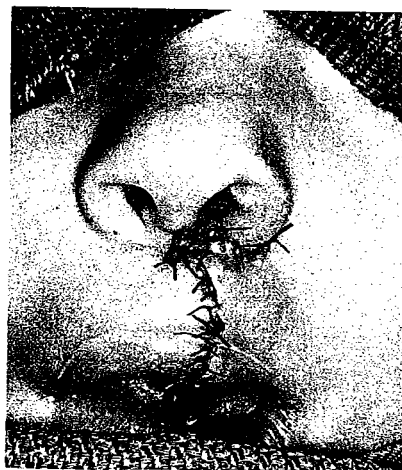This positions the alar base in symmetry with the normal side.

WHITE ROLL FLAP INSERTION

As described in the incomplete cleft operative section, insertion of the white roll flap is postponed until suturing on either side of the mucocutaneous ridge has been finished. Now the little flap, which is spearhead-shaped and measures 1 mm. thick, 1.5 mm. wide and 2+ mm. long, overlaps the noncleft side. It is lifted out of the way, and a similar-sized and -shaped skin section from the opposite adjacent mucocutaneous ridge is removed. Then the white roll flap fits neatly into this bed and is fixed with a couple of 7-0 silk sutures (Ethicon #768), breaking the line of the vertical scar crossing the mucocutaneous ridge. Interdigitation of a white skin roll to interrupt the red of vermilion mucosa "bleeding" into the red of the vertical skin scar avoids the effect of an accentuated bow peak or even a suggested contracture when none exists. This little flap also tends to *round out the curve* of the cleft join at the bow to the more gentle smoothness of the normal side which otherwise may be too sharply angular.

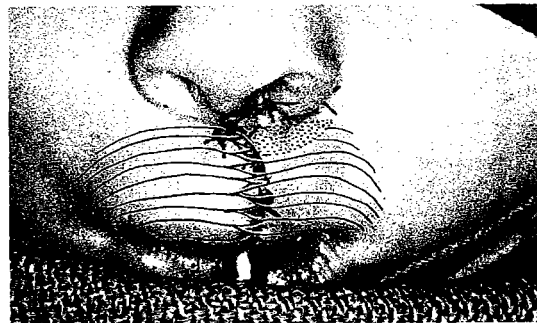
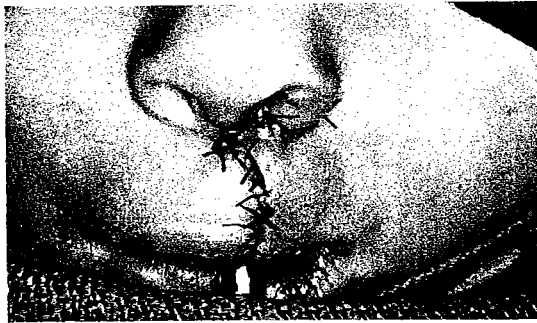


The area of overlap by the white roll flap on the medial side is excised and the mucocutaneous interdigitation is completed by fixation with 7-0 silk.

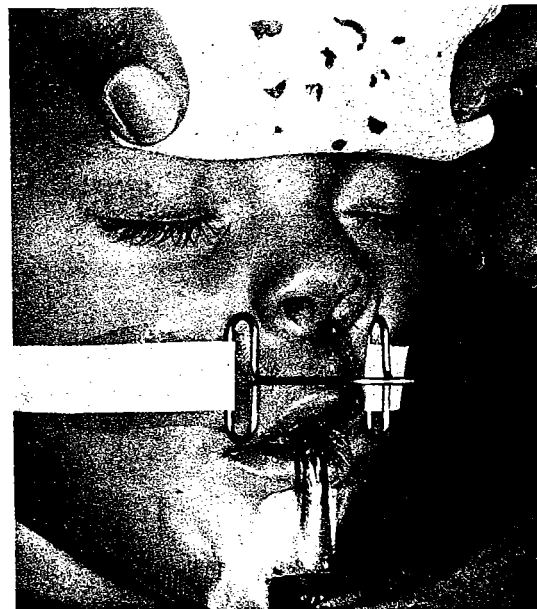


The final posture of the lip and nose after rotation-advancement plus alar lift and muscle alignment should have the alar rims reasonably symmetrical and the muscle fibers in end-to-end approximation. A Logan bow gathers it all together protectively postoperatively, and the suture lines are covered with an antibiotic ointment.

The amount of tissue discard, scraps of epithelium, attenuated edges of muscle and mucosal tip bits, has been reduced to a minimum, as demonstrated on the piece of gauze.



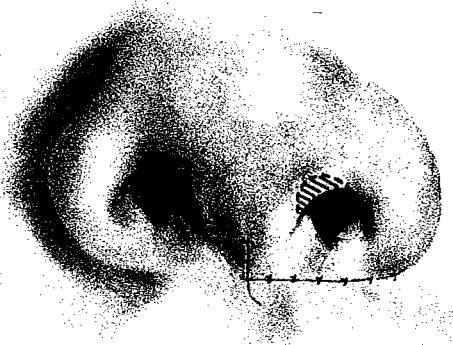
Post-op nasal and labial posture.




Minimal discard of tissue.

ALAR RIM CORRECTION

If a primary alar lift has been used, the alar rim may not seem to require surgery at this time. In such case, it is well to postpone alar rim surgery until the need is more obvious. Eventually, it will be indicated to some degree for there is always a skin web of varying amount which is not influenced appreciably by the columella and alar base positioning and is not completely removed even by the alar lift. This excess skin can be excised directly and 6-0 silk used for closure.

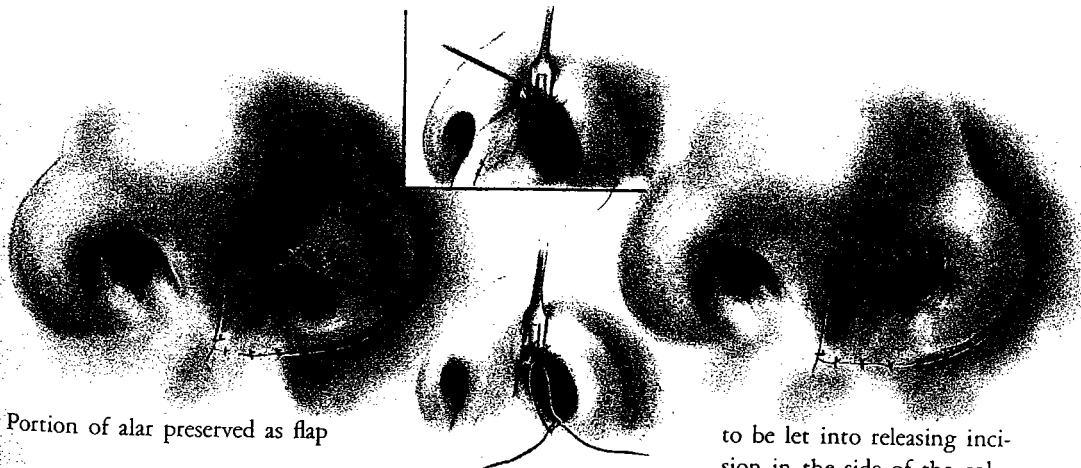


Alar skin web excised



and sutured directly.

It can be taken as a small skin flap based medially and let into a tiny releasing incision in the side of the columella at the height of the arch to give added length to the columella.

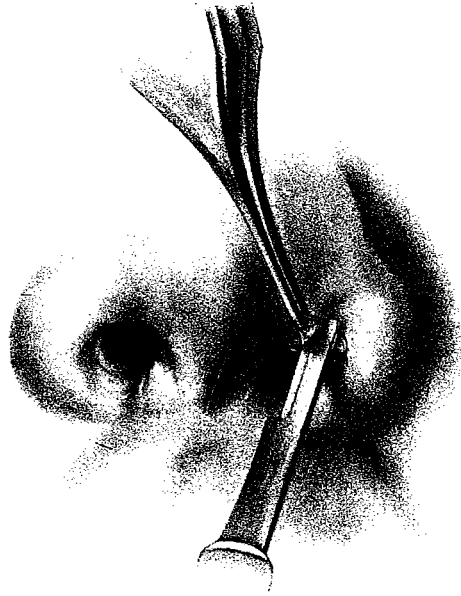


Portion of alar preserved as flap

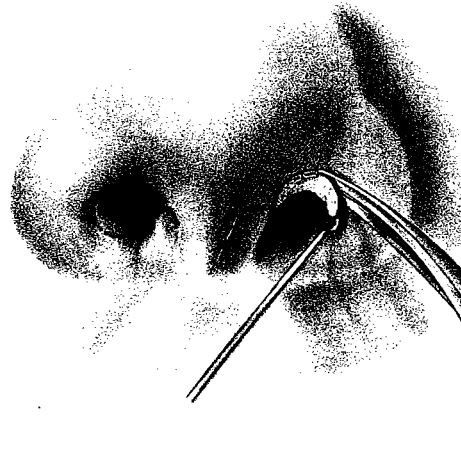
to be let into releasing incision in the side of the columella.

The excess can be denuded of epithelium, cut as a flap and introduced beneath the undermined nasal tip skin into the area of greatest weakness where the alar crease extends as a groove

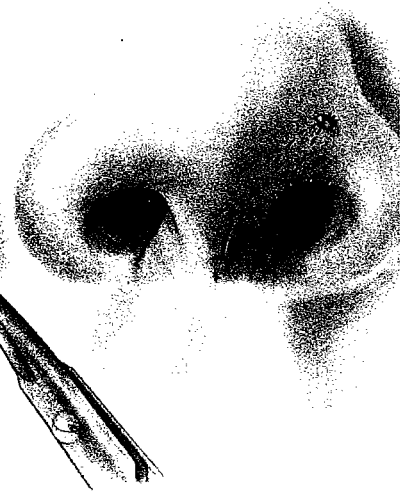across the tip toward the alar margin. This transposed flap usually is guided with a pull-out 6-0 silk, which is tied externally over the skin of the tip and is removed in two days. The alar margin is then sutured neatly with 6-0 silk.



Denuding epithelium of alar web.

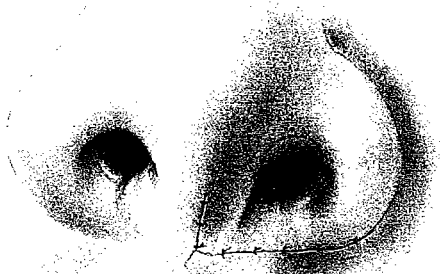


Cutting denuded web as a flap

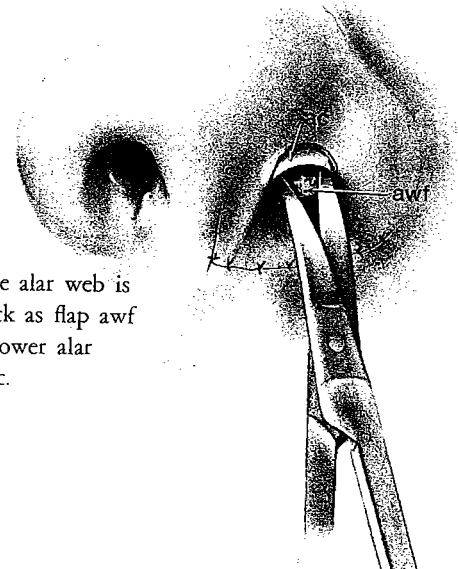


to be introduced in undermined area of alar deficiency.

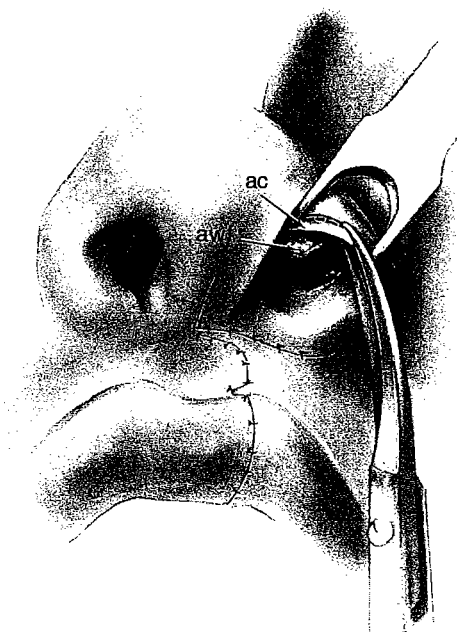
Recently, another variation has been found beneficial. The new alar rim is marked on the drooping side to balance the normal side. An incision is made along this line, and the skin inferior to it is dissected thinly to expose the inferior edge of the alar cartilage. The cartilage is freed from the mucosa and is cut as a flap ac to be transposed up into the tip in the alar groove area. The skin flap awf which once covered the alar web is tucked up under the alar rim as additional vestibular lining with a 5-0 catgut mattress suture. The alar rim is then sutured to the alar web flap along the margin with 6-0 silk.




Normal height of alar arch is marked on cleft side.



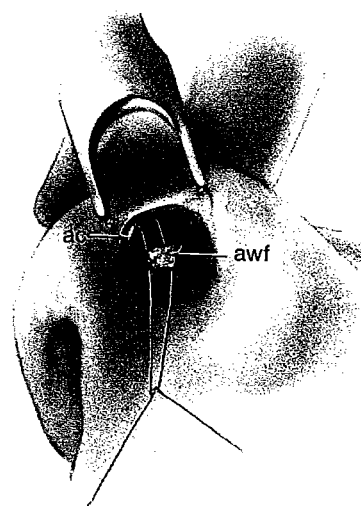
Skin of the alar web is turned back as flap awf exposing lower alar cartilage ac.



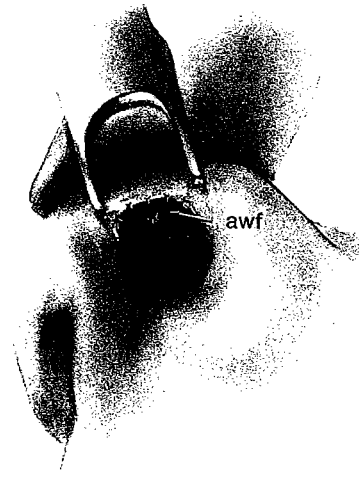
Alar cartilage ac trimmed as a flap.



Cartilage flap transposed under skin of nasal tip in the alar crease area.



Alar web flap awf is lifted with mattress suture up under the alar arch to provide more lining.



Alar rim is sutured to alar web flap awf along margin.