

30. Postoperative Care

ALL visible suture lines are covered generously with an antibiotic ointment. Then a Logan bow is placed across the sutured lip with inward tension on the cheeks.

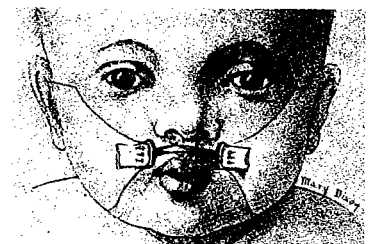
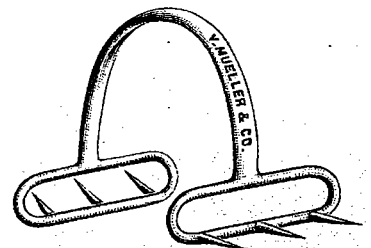
William H. G. Logan, a soft-spoken, diplomatic plastic surgeon and Dean of the Loyola School of Dentistry, was also the son-in-law of Truman Brophy and in a sense directed the Brophy principle of metal control of cleft parts to the postoperative protection of the sutured lip. In 1921 he designed a curved metal piece with spiked loops on each end through which tape could be passed and secured. This device has enjoyed popularity in many cleft surgery clinics over half a century. In 1923 Brophy endorsed his son-in-law's bow in his usual dogmatic and persuasive manner. In his book *Cleft Lip and Palate*, with the accompanying illustrations, he wrote:

This is Dr. W. H. G. Logan's invention and it is not open to the slightest objection. Tension on the lip may be increased or diminished at will, and this is a feature that has not been possible with any other method. It not only holds the lip in a state of quiet without pressure against the vessels, but at the same time allows access to all its surfaces so that they may be kept absolutely clean and the process of repair may be watched from the time of operation until the sutures are removed. The horsehair sutures may be removed from three to five days after operation, thus avoiding suture scars, while the appliance remains.

Although today some surgeons sneer at the Logan bow, I still feel it helps to relax the operative site and counteract the deleterious effects of crying and laughing on the wound edges, thus affording better insurance toward ideal healing. At the same time,



William Logan



it protects against an unexpected blow as well as leaving the wound exposed to facilitate local treatment of the suture line. The metal arch of the bow stands like an identification flag on a ship to warn the nurses of what has been done because after surgery, with ointment over the suture line, it may not be obvious that a cleft has "been and gone." It is extremely important that those attending the infant not let him lie face down!

The standard nursing care of the cleft lip wound previously entailed constant cleansing of the suture line with hydrogen peroxide to remove crusts. This is painful and irritates the stitches and the wound. I therefore cover the suture line generously with an antibiotic ointment after the surgery. The nurse can keep the sutures covered by application of the ointment three times daily after meals. The ointment protects the stitch holes from the contamination of constant nasal discharge, prevents crusting and keeps the sutures soft for easy removal on the fourth postoperative day. The antibiotic ointment is continued one day after suture removal until the stitch holes are sealed.

Other early postoperative precautions are taken. Sedation is ordered for excessive crying as this will cause undesirable tension on the healing lip. Arm restraints are applied to the elbows to prevent the infant from getting his fingers into his mouth and inadvertently separating the new wound. A slatted elbow restraint is made by sandwiching tongue blades side by side between two layers of 4-inch adhesive tape or fitting them into a cloth band with tie straps. This straitjacket is wrapped around the infant's elbow at the end of surgery and pinned to the pajama shoulder to prevent slippage. Plaster of paris elbow casts are also effective.

TAKING OUT THE STITCHES

Suture removal is one of the most difficult procedures in postoperative care. Many surgeons in desperation resort to general anesthesia to keep the baby quiet long enough to remove the stitches before a head jerk pulls open the freshly healed wound. Others sedate the baby, then wake him up to strap him on the

treatment room table and with his soft little head in a hand vise and a bright light in his eyes extract the sutures painfully one by one.

I am willing to take any amount of time to place the sutures exactly but not one second to remove them, so a method was worked out by nurses Janet Kuszaj and Beverly Wirch that has proved very successful. On the fourth postoperative day, the baby is fed and is given sedation equal to the preoperative order. One hour later the baby will be found sound asleep. The side of the bed is let down quietly, and with fine smooth forceps and tiny sharp scissors the sutures are removed with great care. The baby seldom stirs during the procedure. This takes a steady hand, a good eye, great patience and a love of babies, but then so does all of pediatric nursing.

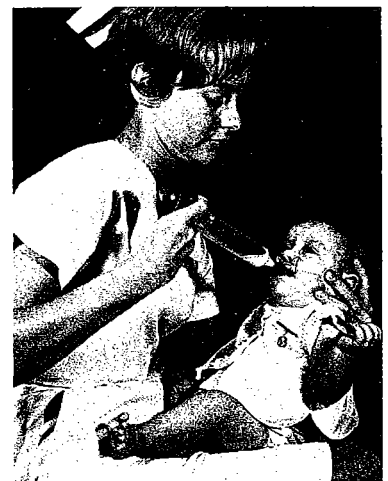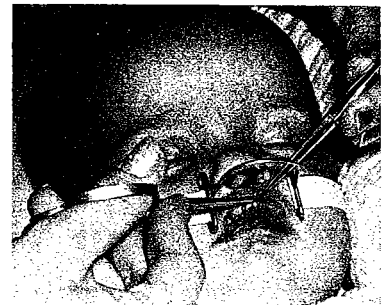FEEDING AFTER LIP SURGERY

After the cleft in the lip has been closed and the muscles of the lip are approximated, it is important to give this wound as much immobilization as possible to encourage good healing. The Logan bow is an aid. If the baby is allowed to suck a nipple, a pull will be exerted on the new lip scar. The baby is best fed by a method that does not require the sucking movement—that is, the same routine used before surgery. The baby is held upright in the crook of the nurse's arm with his head in her left hand. A 1½-inch rubber catheter attached to the end of a 50 cc. Asepto syringe can be slipped past the baby's healing lip and over the tongue. The liquid can be introduced by the squeeze of the bulb at whatever speed and amount the baby can tolerate easily.

The type of diet ordered by the surgeon for the postoperative cleft lip is called a *cleft palate diet*. This usually consists of clear fluids only for 24 hours, then half-strength formula for 24 hours, to be followed by normal formula. Like most orders that become habit, this diet is outmoded. As soon as the baby reacts fully, clear liquids are safe, and after 12 hours there is no reason why regular formula cannot be started. Return to bottle feedings one month after surgery is allowed unless there is also a cleft of the



Janet



Bew

palate. In this case the Asepto technique should be continued until some time after palate surgery.

Antibiotics are not used routinely. If the lip wound shows inflammation, they can be instituted, or if there is temperature spiking that cannot be explained by dehydration, a short course of antibiotics is in order.

The patient is allowed to go home on the fifth postoperative day with the Logan bow and elbow restraints in place. The bow and restraints will be removed after two weeks. Prior to discharge, the mother is retaught to feed her baby with the Asepto feeder.

It is important for both parents and pediatrician to realize that the lip scar that is red, firm and contracting at one month after surgery usually will be soft and pale at six months and almost invisible at one year. When a minor lip correction is necessary, it is usually done at six months or postponed until time for further palate surgery.