

23. Basic Confirmation

SKIN LINES

BASIC studies by others have corroborated the soundness of the rotation-advancement principle. This is exemplified by Dupuytren's study in 1834 of the natural direction of skin lines. He noted that three round puncture wounds created by an awl in the skin of a suicide victim had been drawn flat as if cut by a knife and concluded that fiber alignment accounted for skin tension. Then Langer in 1861 repeatedly punctured cadavers with a 2 mm. awl at 2.5 cm. distances and hypothesized that skin was always in a state of dynamic tension caused by the arrangement of fibers of connective tissue, and this pattern was thought to be in the direction of the muscle pull.

Then Leonard Rubin at Kings County Hospital in Brooklyn, New York, in 1948 in *Plastic and Reconstructive Surgery*, using a police technique of coating the skin edges with a colorless chemical, mapped on sensitized paper the pattern of facial lines. Analysis of the anatomical skin line structure of different faces showed definite trends—at times similar to, at other times at variance with Langer's lines. Rubin made an important conclusion:


The skin lines followed a definite pattern; being at right angles to the resultant pull of the underlying muscles. Since the skin is attached to the muscles by fascia, it was thrown into accordion-like folds or lines always at right angles to the muscle direction.

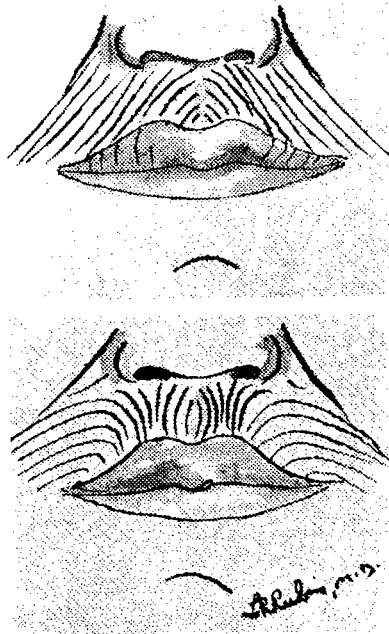
The subsequent work of Conway and Kraissl confirmed Rubin's hypothesis.

Rubin also noted that there was individual variation in the



Leonard Rubin





direction of lines, which was influenced by the fact that "some facial muscles are stronger than others." This was particularly notable in the cheek as represented by their uplifted direction in the happy type and downward drooping in the sad. Fortunately, regardless of the emotion involved, the lip lines coincide invariably with the rotation-advancement plan. What's more, Rubin practices what he preaches for he wrote in 1972:

I have been teaching my residents at the Nassau County Medical Center and Kings County Hospital the technique of the rotation-advancement repair since its introduction. Our long range evaluation has shown it to be the procedure of choice over all other procedures.

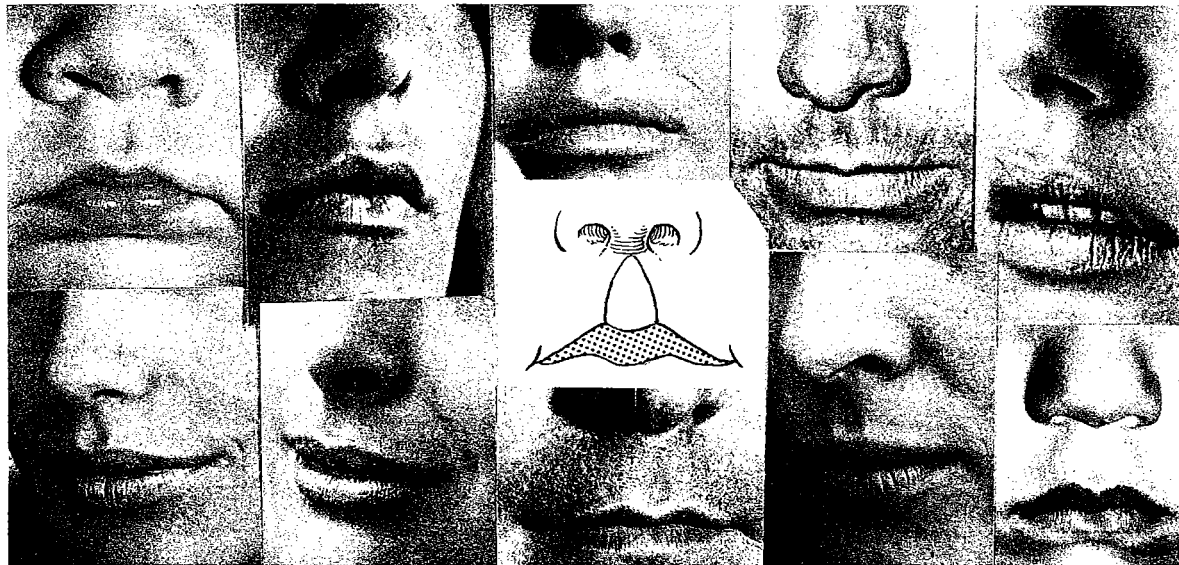
To help our residents do the surgery without "eyeballing" we have devised a simple wire technique patterned after Tennison's bent wire which allows our boys to do the surgery with the greatest of ease.

PHILTRUM COLUMN VARIATION

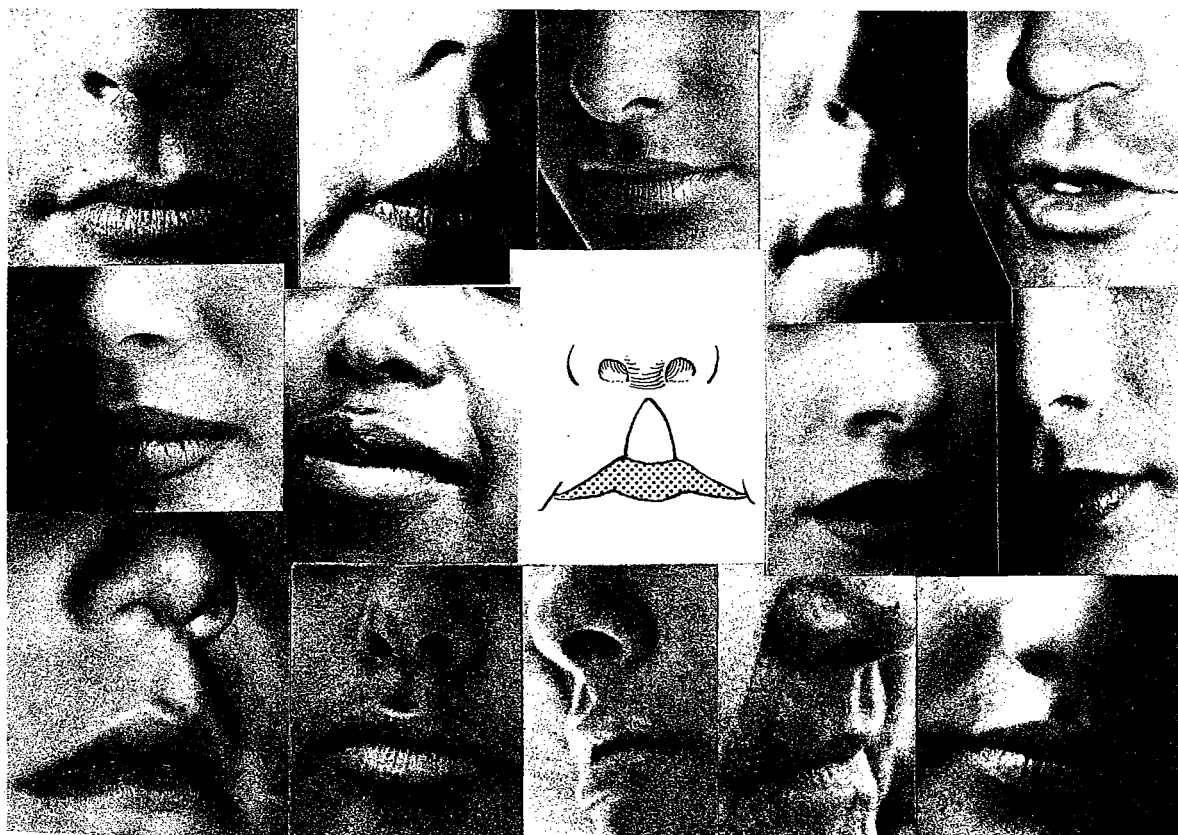If the premise is right that the scar of cleft lip union can best be camouflaged by hiding it in the line of the philtrum column, the direction of the normal column becomes important. A study is presented of candid portrait photographs, taken by my brother Hamilton, of movie actors, actresses and models who, being the beautiful people, should have the nicest philtrums. Interspersed among the celebrities are some "regular" people. The direction and termination of the philtrum columns are seen to vary even among the movie stars. All were found to run from the height of the bow's arc in a gentle upward medial curve toward the base of the columella. Some terminated in the lateral sides of the columella base, while more seemed to meet at the front center of the base or before reaching the columella at all. Very rarely did the column eminence actually run into the floor of the nose, and when it did it usually was positioned to the medial side of the midline, blending with the lateral foot of the columella. Thus this important landmark coincides with the rotation-advancement design.

In the few cases in which the philtrum column actually runs directly into the floor of the nose the effect is less aesthetic. Ugly

Columns blend into the columella at its base and side.



Columns meet at or below the base of the columella.



or not, if it is the condition that exists on the non-cleft side, for the sake of symmetry an attempt to duplicate it on the cleft side may be justified. Here Reichert's positioning of the scar in the vertical direction all the way up into the nasal floor, after rotation, may be acceptable . . . ?

APPARENT VERSUS ACTUAL DEFICIT

Brown and McDowell in 1950 repeated the earlier concept held by Blair and Brown that

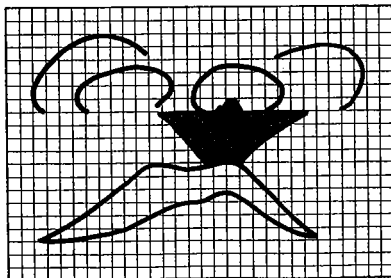

The major deficiency of tissue in an open lip is a triangular deficiency at the lower border on the columellar side.

Several years later Marcks repeated this premise. At the Second International Congress in London in 1959 I pointed out the fallacy of this established position of the missing triangle. Although the apparent gap in the cleft lip seems to be in the lower portion of the lip with its apex pointing toward the nasal floor,

The actual defect exists much higher and this fact was a contributing factor toward the development of the rotation-advancement principle.



Bard Cosman



In 1965 Cosman and Crikelair, of Columbia University Medical Center, with the aid of casts measured unilateral clefts and found that the perimeters of the cleft and non-cleft alae were not very dissimilar in length and the difference was not related to the width of the cleft. They also discovered that the sum of the lengths of the vermilion segments present on the cleft side and on the cleft edge of the normal side was equal to or slightly in excess of the vermilion length of the normal. Then, with the aid of scale diagrams, they charted an absolute deficiency of tissue in the unilateral cleft lip of a roughly trapezoidal shape as seen from in front and of a tapering tetrahedron as seen laterally, with the magnitude of the defect greatest beneath the nostril floor rather than at the vermilion border of the lip.

It was particularly encouraging that the scale diagrams, published in *Plastic and Reconstructive Surgery*, 1965, led Cosman and Crikelair to decide:

The technique which most nearly repairs the hypothetical deficiency is that of Millard. In this method the tissue advanced from the cleft side is placed superiorly beneath the nostril where the deficiency is greatest.

Actually this trapezoid is closer to actuality than a triangle. Its medial two-thirds (1) has always been filled by the medial advancement of the lateral lip element. The lateral one-third of the trapezoid, which is usually a smaller triangle (2), varies in amount. When there is a definite deficiency by measurement, the lateral lip flap must be extended into the vestibule to get skin or up on the alar base to steal the required lip tissue. A muscle edge flap from the medial lip can be transposed to provide extra muscle and bulk to this otherwise muscleless extension.

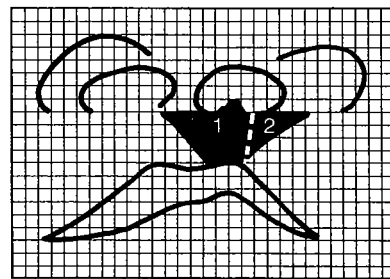
I. A. Kozin of the Moscow Scientific-Research Institute of Cosmetology of the Ministry of Health, Moscow, U.S.S.R., noted in 1969:

Great attention should be given the research of Millard and later Cosman and Crikelair, who proved beyond doubt that in this deformity, the absolute defect of the tissue had the shape of a triangle or trapezium, the base of which is located at the nose base and its upper part is directed towards the lip red on the cleft side. The authors also proved that the total amount of red sections of the cleft side of the lip equalled, or slightly surpassed, the length of red on the healthy half of the lip. Consequently, many contemporary surgeons (Borde, Lawrakerov, Wynn, Galambos) admit the appropriateness of such methods of lip plasty in which advancement of triangular wedges of tissue into the area of maximal lack, i.e., to the upper third of the lip . . .

Proving he practices what he preaches, Igor Andreevich Kozin, my correspondence friend from Russia, wrote a pleasant letter in April 1973. He said:

Quite recently I began to use your method of cheiloplasty in infants in the first year of life in incomplete and narrow complete clefts of the lip and palate. The results of the operation both I and my colleagues like but I would like to clarify several questions.

1. The amount of mobilization of the orbicularis oris in the region of the lateral flap?
2. How do you carry out the plasty of the vermilion border and mucous membrane of the lip?



Igor Kozin

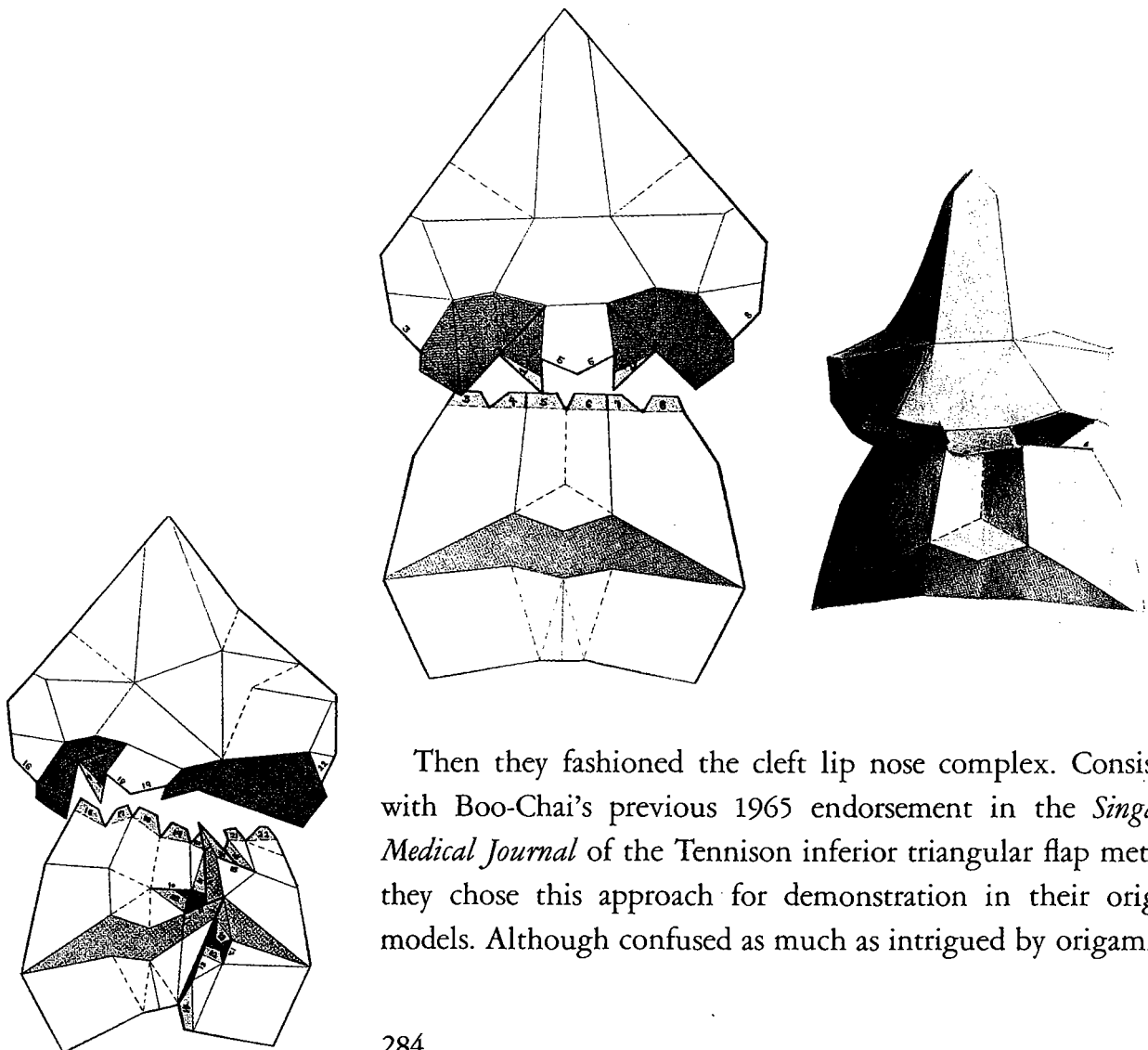
These are good questions, and, although the answers are always changing, the latest stand on each appears in this volume.

THE BOO-CHAI PAPERS



Khoo Boo-Chai

Soon after paper was invented in ancient China 2,000 years ago, the original Oriental art of paper folding was developed. Khoo Boo-Chai of Singapore, who has built his own 50-bed hospital and plows 10 percent of his earnings back into his cleft lip and palate program, decided to duplicate the cleft problem in paper. This study was published in 1970 in the *British Journal of Plastic Surgery*. Boo-Chai and Ichiro Tange of Tokyo, with paper, pencil and paste, created origami models to facilitate the study of the cleft deformity and its surgery. First they cut the pattern and folded it into the normal lip and nose complex.



Then they fashioned the cleft lip nose complex. Consistent with Boo-Chai's previous 1965 endorsement in the *Singapore Medical Journal* of the Tennison inferior triangular flap method, they chose this approach for demonstration in their origami models. Although confused as much as intrigued by origami art,

I challenged Boo-Chai's paper tiger, questioning the wisdom of his choice and suggesting action at a higher level in the origami lip models.

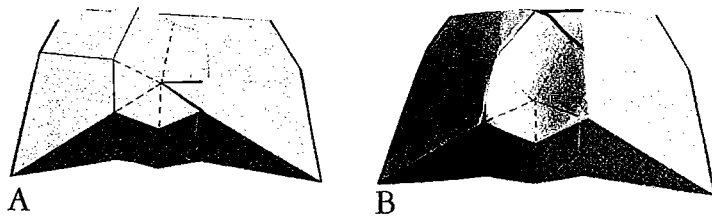
The scholarly Boo-Chai responded, admitting,

I welcome this sort of brainstorming session with you.

He reminded me of the observations that the original origami paper had brought to light, noting particularly:

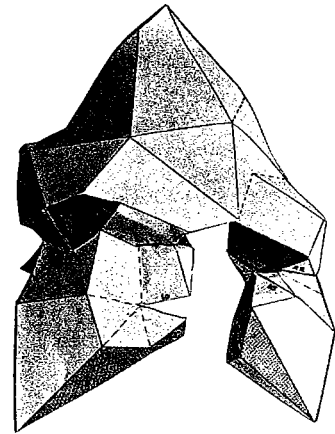
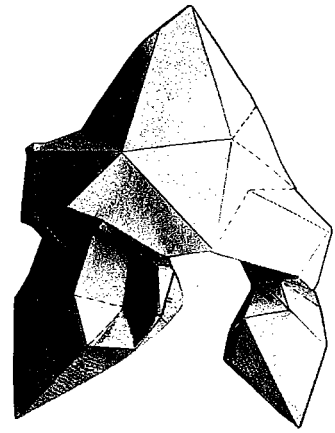
There is an apparent triangular defect in the lower portion of the columella border of the cleft . . . to this I would like to add another observation. There is an excess in the unfinished origami model of the medial lip element in the region of your flap "c." You have quite rightly utilized this area in the R-A technique for the nostril sill. Now the problem in question is the position of the triangular defect. In the unfinished paper model of the medial lip element you can see the triangular defect very clearly. In the R-A technique, you have rotated the whole lip (including the inherent defect) en bloc down. At the same time, you free the excess tissue on the lateral side of your cut for flap "c." You have, on many occasions, pointed out the advantages of this step, one of which is the preservation of the philtrum dimple. This can be simply demonstrated when you play about with the unfinished paper model of the medial portion of the lip. If you open up the paper model to show the triangular defect of the inferior incision clearly, then the dimple simply disappears.

Introduction of the paper flap into the lower portion of the paper philtrum flattens the cupping (A) whereas insertion of the paper flap high above the cupping drops the paper philtrum without diminishing its dimpling (B).



Boo-Chai concluded:

I have used both the triangular flap technique as well as the R-A method in my personal series of 850 cases. Nowadays, I tend to use more and more of R-A because a follow-up of my own cases (not reading about other people's series) has convinced me that it gives superior long term results and the underlying principles are sound.



Don't miss this point!
←

PROOF IN THE FLESH

Thus has Boo-Chai brought out more vividly than ever that flap interdigitation into the dimple releases the cupping and actually flattens it! To avoid destroying the coveted dimple, as we cannot go any lower, the obvious direction is ever upward to R-A! What a shame it would have been to spoil the dimple in this Jamaican baby. The rotation skirted the philtrum and only let the advancement in above, where it does the least harm.



MUSCLE ALIGNMENT

Then there is the positioning of the orbicularis oris muscle bundles. As first mentioned in Stockholm's concert hall in 1955 in defense of the rotation-advancement principle, it was later published in the *Congress Transactions*:

A well balanced lip is produced primarily because the strong medial lip element has been allowed to take over the major part of the construction. I have been impressed by the natural looking muscle action. Is it the lopsided "Z" and a half of full thickness flaps that more evenly distributes the balance of muscle pull by juggling the dysplasia of the orbicularis on each side of the cleft? In lips with a major portion of the scar vertical, the patients seem to smile on either side of the scar. In this method he is forced to smile through it.

CLEFT MUSCLE DISSECTIONS

It is reassuring that science eventually supported my optimistic impressions. Basic histological studies by Pennisi, Shadish and

Klabunde, presented in 1966 but not published until 1969, compared microscopic sections of the normal lip in the region of the philtrum and the fused portion (Simonart's band area) in an incomplete cleft lip. The normal revealed harmonious arrangement of all tissues with consistent transverse arrangement of the orbicularis muscle. The incomplete cleft lip revealed sparse transverse arrangement of orbicularis oris muscle and more abundant vertical muscle bundles with chaotic appearance of all tissues.

Other studies, by Fara, Chlumska and Hrivnakova of Prague in 1965 and Novoselov and Lavrentiev of Moscow in 1969, seemed to coincide generally with the findings of Pennisi, Shadish and Klabunde of San Francisco.



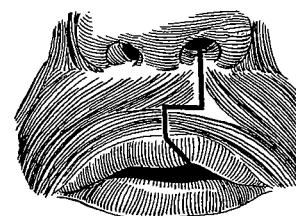
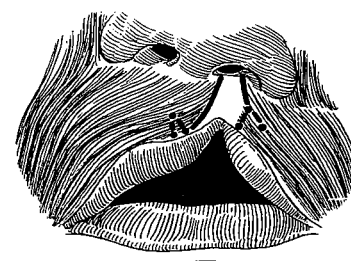
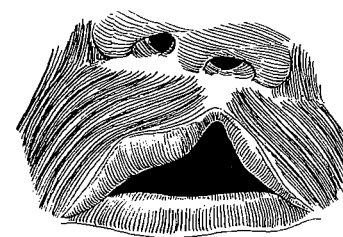
Vincent Pennisi

A CONSTRUCTIVE EVALUATION

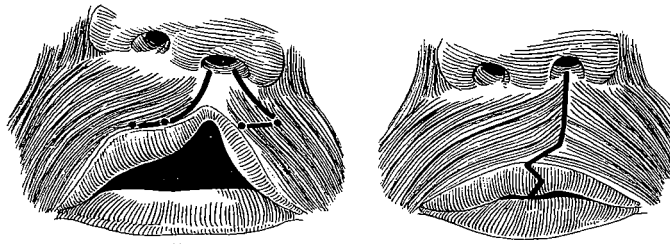
In the normal lip the orbicularis muscle is arranged in parallel horizontal bundles of considerable bulk decussating across the midline to provide the necessary strength for normal function. The correct positioning of these muscle bundles in the surgical closure of cleft lip is considered important. Thus, Vincent Pennisi with Shadish and Klabunde in 1966 closely examined the more popular procedures of today to determine how they fail in varying degrees to redirect the vertically placed muscle bundle mass.

The quadrilateral flap repair (LeMesurier) simply advances the vertical muscle bundle closer to the midline. An insignificant amount of the vertical muscle is directed transversely in the rotation of the quadrilateral flap. This does provide more normal animation about the vermilion but the remainder of the lip hangs as an inanimate curtain. Most of the orbicularis function on the cleft side is limited to an oblique line between the commissure of the mouth and the alar attachment of the nose. . . .

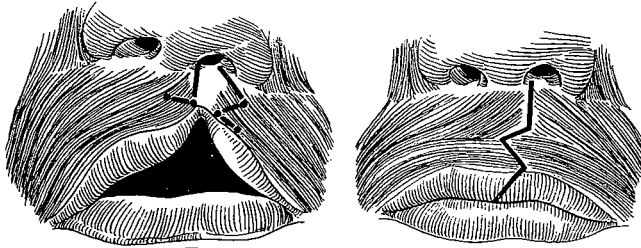
The same sin of omission may be ascribed to those procedures which utilize triangular flaps [Brown-McDowell and Tennison] whether they be single triangles above or at the vermilion and single or double triangles [Skoog] in the central portion of the lip. In each instance, only a small amount of vertical muscle is redirected horizontally, leaving the lip inadequately reconstructed from a functional point of view. . . .



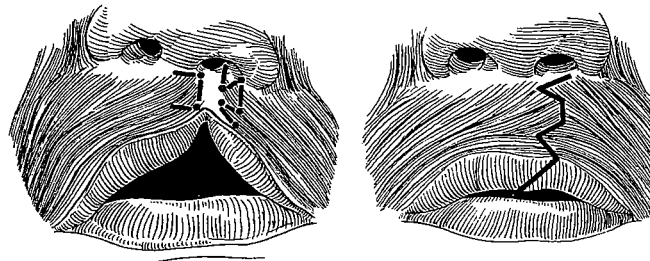
LeMesurier



Brown-McDowell



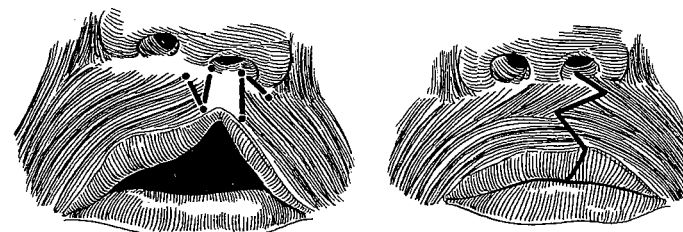
Tennison



Skoog

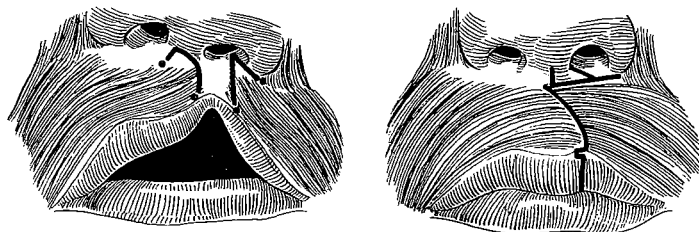
There are two procedures which could make a more realistic attempt at rotating the entire vertical orbicularis muscle by including it in the lateral flap on the cleft side. In both of these instances, the apex of the flap is directed toward the alar attachment of the nose and the base is located in the direction of the commissure of the mouth. In both procedures, the surgeon's attention must be directed at complete visualization of the vertical muscle mass, and its inclusion within the rotated skin flap. From this point on, an end to end anastomosis of the orbicularis muscle could be achieved.

A Davies type lip repair showing more satisfactory mobilization of the orbicularis muscle but still inadequate:



Davies

A Millard type repair showing complete mobilization of the orbicularis muscle on both sides of the cleft, permitting more normal functional and anatomical approximation:



Millard

Kurt Schneider of Zurich, MMM Fellow with me in 1972, had visited Charles University, Prague, and considered it important to bring my attention to a 1971 paper by Fara in *Acta Chirurgiae Plasticae*. Fara explained his experience to be,

in cooperation with several pathologic-anatomic Institutes, autopsy in 25 still-born children with different types of cleft.

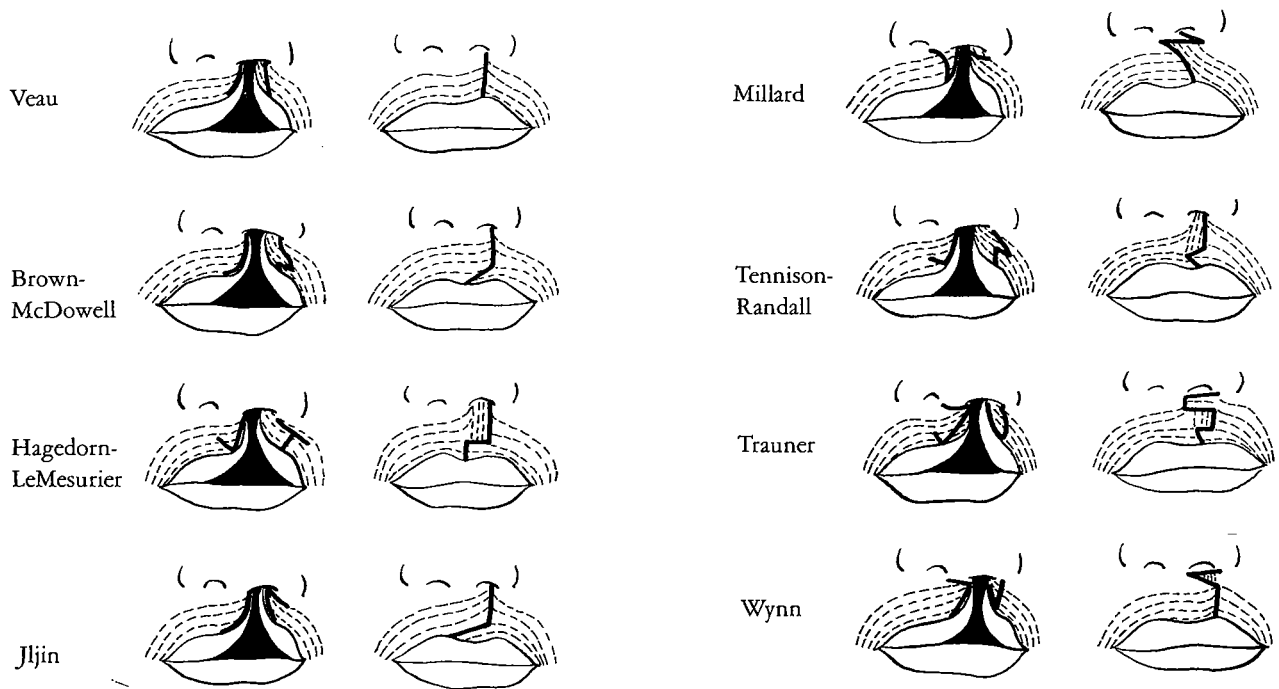
His anatomical findings (muscular and vascular) were much as he first described and similar to Pennisi's. His clinical application of these findings to the cleft surgery by now had become obsessed with obtaining, at all cost, end-to-end anastomosis of the orbicularis oris muscle fibers across the cleft. He said:

We pay maximal attention to the physiological reconstruction of the m.o.o. manifest not only in the esthetically satisfactory appearance of the lip, but mainly in far more favourable development of the maxilla.

Most would agree in principle with the concept that end-on muscle fiber anastomosis is ideal. In fact, I agree in most part with his stand that

Any crosswise incision over the course of the muscle bundles is of an unfavourable effect on its peripheral sectors which have been separated from the vessel and nerve supply. . . . It must be assumed that thus separated muscle fibers are unable to obtain nutrition from anastomosis in their upper—predominantly ligamentous—attachment at the nasal base and that they undergo scarring. The nerve supply is destroyed in every case by such a step because it depends upon the facial nerve fibers, proceeding from the corners of the mouth to the center of the lip.

Here the rotation-advancement approach is in perfect rapport

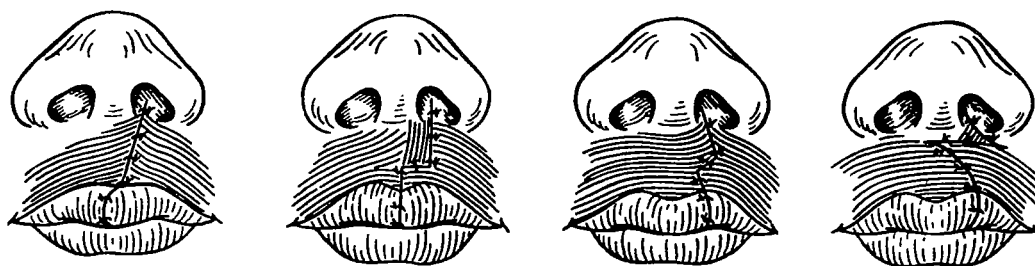


as its only muscle incisions are high up at the lip's so-called avascular and amuscular attachments to the nose!

Fara then indicated sketchily his interpretation of what eight different operations did to the muscle fibers of the lip. There are several inaccuracies in his sketches, but his dealing with the rotation-advancement design is hopeless. First, he has an inaccurate idea of the incisions and has diagramed something similar to my old Korean sketches which long ago became obsolete. Second, although he has the non-cleft element in good position, had he rotated correctly he would have the muscle fibers horizontal, ready and eager for end-on anastomosis. Third, although he has not drawn the advancement flap correctly, he has shown its oblique position being transposed horizontally into the rotation gap. The *unreal* part is that Fara shows the muscle fibers originally running in a less vertical direction than after the advancement! Of course, this is absolute nonsense.

In 1967 Von J. Koch of Leipzig, East Germany, indicated his preference for the rotation-advancement incisions because of a better orbicularis oris muscle fiber alignment.

In 1973 the robust Joachim Gabka of Berlin presented to me in Copenhagen his cleft lip and palate section in a new German *Handbook of Plastic Surgery*. Gabka, like Pennisi and Koch, favored the rotation-advancement positioning of the orbicularis



Veau

LeMesurier

Tennison

Millard

oris muscle fibers for end-on union. His schematic drawings clarified its comparison with several other standard methods.

I feel that Pennisi, Koch and Gabka were closer to the truth than Fara in the positioning of the fibers after rotation-advancement, but I also feel that the muscle fibers in the lateral lip element are not quite positioned into perfect horizontal alignment. The appearance and function of my lips over the years and recent electromyographic studies indicate that in most cases this is not of great importance, but Fara has a physiological point to which I now direct my attention.

Recently, a two-week-old complete unilateral cleft with cerebral anomalies became available for autopsy study. Dissection and sections taken by resident Gene Tanski reveal findings similar to those of other workers.

In general the muscle fibers seem to run parallel to the cleft edge, turning more horizontal as they progress away from the cleft. There is, however, some chaos in the arrangement which prevents any hope of getting true horizontal alignment with end-to-end anastomosis. The greatest chaos seems to be occurring in the cleft side muscle bulge.

Although Fara's and my muscle end point will be the same, our methods of achieving it are somewhat different. In his drive for end-to-end muscle fiber contact he ignores Langer's lines, dimple integrity, philtrum column balance and the artistic construction of the lip and nose complex. As he says:

We free the attachments of both labial muscle stumps from the periosteum of the edge of the piriformis aperture and fold it in distal direction. We cut off the ligamentous terminations so that the muscle bundles afford sharp intersections and we thus prepare the muscle stumps suitably for suture. . . . Thus relatively optimal reconstruction of the labial muscle circle is obtained. . . . We may carry out minimal skin excisions because even

Back to Rose
and Kilner
and
a little
wishful
thinking

if the lip is shorter by 1-2 mm. but starts to function well, it shall be equal in height to the healthy side within 1-2 years. . . . In all the less serious cases, we carry out simple vertical or somewhat arched incisions and sutures of the lip. Only in serious clefts we supplement the hypoplastic medial edge of the cleft with a flap according to Tennison, which is however only formed by skin.

ALIGNING THE MUSCLES IN ROTATION-ADVANCEMENT

Medial fibers O.K.

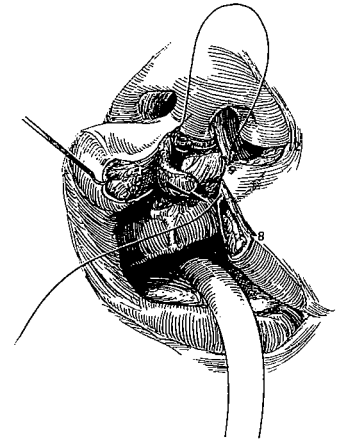
In the rotation-advancement, flap c removes the so-called ligamentous termination of the muscle edge on the medial side, and the rotation with back-cut positions the muscle fibers in a horizontal direction. *Minimal* edge undermining is all that is allowed to protect the integrity of the philtrum dimple.

Lateral fibers?

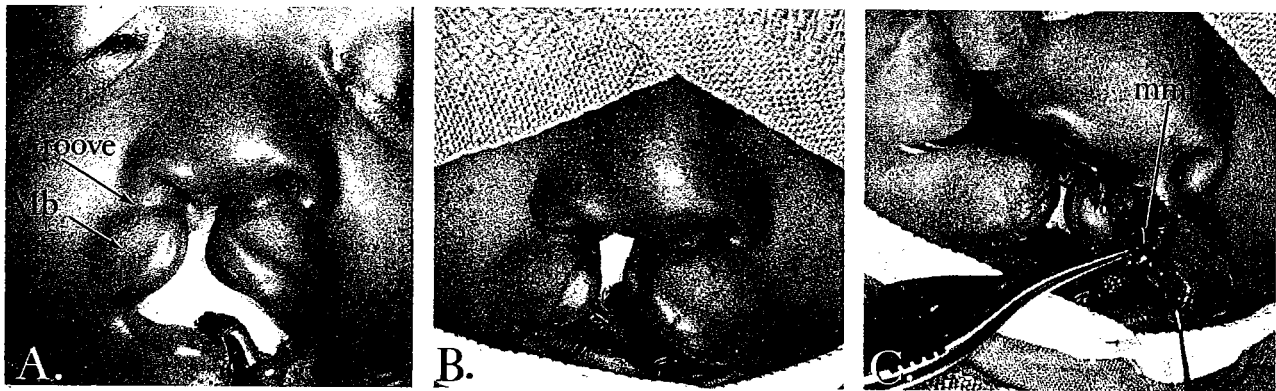
On the lateral side, we had already begun transposing a muscle edge flap from the medial side into the "weak" grooved area between the nasal base and the muscle bulge of the lateral lip element. One of the principles, the actual position of the defect, that caused the flap action to be shifted from the inferior triangular flap of Tennison to the *superior* rotation-advancement position suggests a similar repositioning of the muscle edge flap. Instead of an inferiorly based muscle edge flap taken from the weak cleft side by Randall and introduced into the non-cleft element, a superiorly based muscle flap from the medial element introduced into the deficient and often grooved upper portion of the lateral lip segment is more urgent! It at least supplies muscle to the defect of the lateral triangle (2) of Cosman and Crikelair's trapezoid (see p. 282). This may be all that is actually necessary.

Yet Fara's 1971 challenge to align all orbicularis oris muscle fibers for an end-on join was "a glove across the cheek." It provoked me to take up the gauntlet and go for the extra few degrees toward better horizontal positioning of the muscle fibers of the lateral element. This is more important in those complete and incomplete clefts which show the exaggerated bulge of

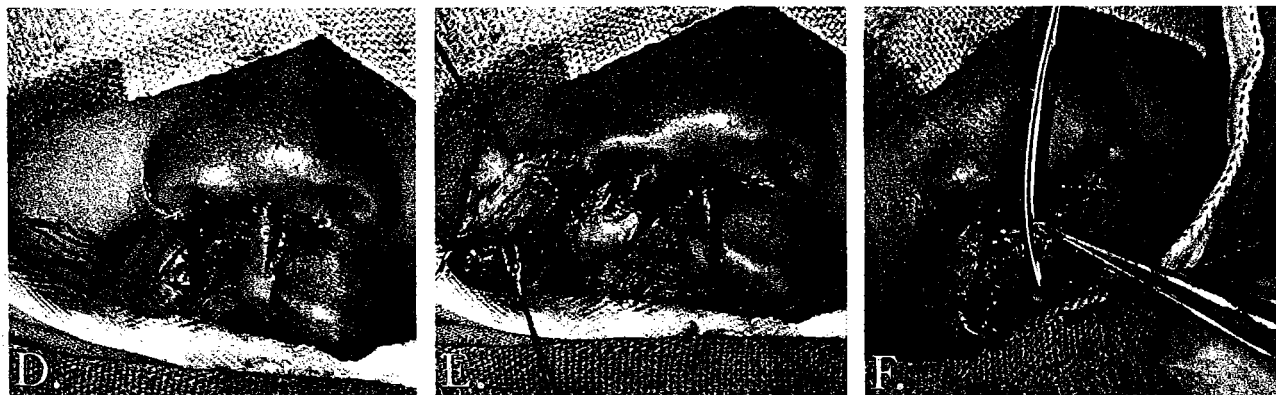
muscle in the lateral lip element. After the advancement flap has been developed, its muscle is freed from the skin and the mucosa, except in the upper one-half centimeter, so that with a muscle back-cut the fibers can be brought into horizontal position and stretched out to reduce the unnatural bulge, and the attenuated edge is trimmed back to good muscle. This procedure leaves a muscle gap above, which is filled by the previously mentioned muscle flap from the medial side. As the key stitch pulls the advancement flap into the rotation gap, a guide suture leads the medial edge muscle flap into the high lateral muscle gap.



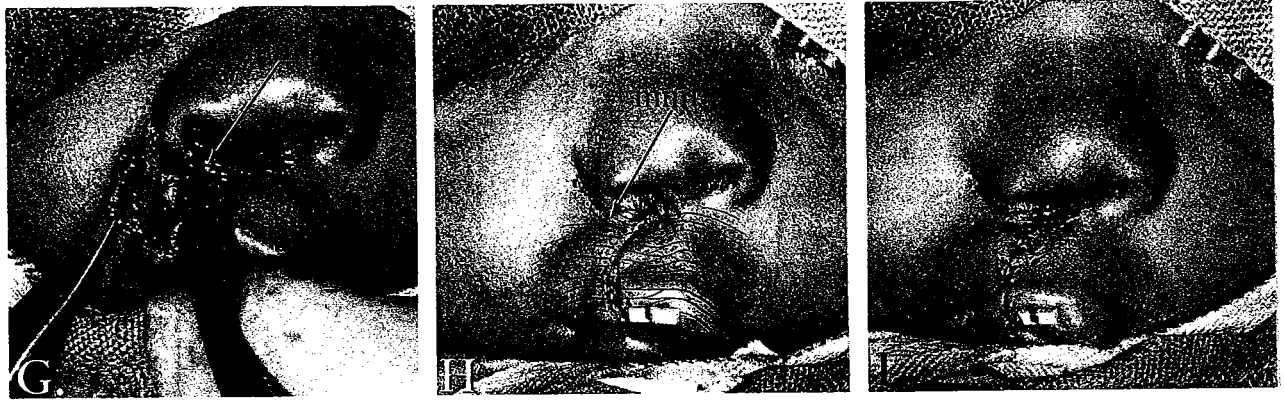Such positioning of the muscles, as demonstrated in this case which resident Les Hovey and I did in 1972, sets a possible plan for the future in certain cases in our clinic.



A. Complete cleft with lateral lip muscle bulge. B. Normal Philtral column dot marked; rotation and advancement incisions line marked. C. Rotation with "backcut" lets flap A down and flap c up. Muscle flap on medial cleft edge being developed.



D. Flap c sutured to columella. Abnormal direction of orbicularis muscle fibers outlined on the lateral lip element. E. Lateral lip musculature undermined from the skin and mucosa and "backcut" in the musculature brings fibers down into horizontal alignment. F. Attenuated cleft edge of freed orbicularis oris is trimmed back to good muscle.



G. Medial muscle flap transposed into gap above aligned lateral lip musculature. H. Orbicularis oris muscle fibers now in corrected position. I. Final suturing including muscle retention tie-over stitch shows orbicularis oris fibers well balanced.

Postoperatively in each instance, there has been excessive firmness of reaction following the extensive freeing of the muscle of the lateral lip flap. In time, of course, the hardness subsides, but with the excellent muscle function achieved previously, there is a question whether this extra trauma will be completely justified.

1974
Correspondence
from Fara
indicated his
increasing use
of rotation
and advancement

TIT FOR TAT

For the effort we have put in Fara's muscle fiber dilemma it is hoped that he will reciprocate by taking the time in his busy operative schedule to reconsider the advantages of the rotation-advancement principle. It is our contention that, besides happy end-to-end muscle fiber contact, he then will have "put it all together" and by preserving other important landmarks will achieve even more natural and aesthetic results.



Erle Peacock

A CLINICIAN'S DREAM

Erle Peacock, professor of surgery, evangelist of the fibroblast, historian of the Civil War and almanac of Carolina football, wrote a learned book, *Surgery and Biology of Wound Repair*, with

Walton Van Winkle, also of the University of Arizona College of Medicine. It was published in 1970 and stated:

In the opinion of the authors, one of the real advancements made in the last few decades in this area has been in devising a technique for the repair of congenital clefts based almost entirely on the concept of the cleft as a healed intrauterine wound. The most successful surgical procedures have been designed on the basis that the cleft is not only a wound but a wound which has undergone healing with all its complications. The concept that the original defect must be re-created (or corrected) before surgical reconstruction has been the most important contribution of the rotation-advancement technique. In addition to the fact that the rotation-advancement concept has made it possible to reduce the deformity of the congenital cleft more than any other previously devised procedure, it is enthusiastically recommended by us to all students of surgical biology as an example of the benefit to patients which accrues from combining technical excellence with sound biological principles.