

22. *Dissimilar Similarities*

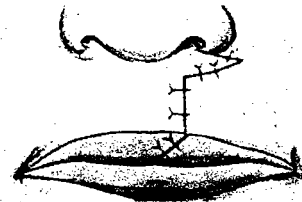
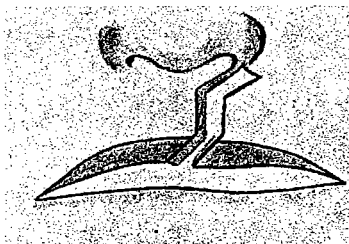

But optics sharp it needs, I ween,
to see what is not to be seen.

JOHN TRUMBULL

THE conception of rotation-advancement was based on fundamental general principles. It has preservation and positioning of all landmarks plus economy of tissue discard in its favor. Many have called it another Z-plasty, which reveals a partial lack of understanding of the basic principle. Some have sniped with generalizations, such as "It is difficult to see how this method in itself could do much to improve results," or by acknowledging the "precision and artistry of execution" have underrated the value of this principle in achieving the "beautiful early results."

Then in 1961 came a strange and disturbing statement by Berkeley:

Z-plasty repairs limited to the upper third of the lip and modeled after the Giralde [sic] technique as described by Thompson seem upside down in character. Blair and Brown pointed to the lower third of the lip as being the deficient zone. With Millard's remarkable success with the Giralde technique, it may be necessary to revise our thinking concerning the lower lip segment and the proper position of the "Z."



Stark was quick to repeat this mistake in 1962 with

Compounding
the error!

Giraldes' operation, in essence a Z plasty at the nasal base with a vertical scar, was the forerunner of Millard's procedure,

and

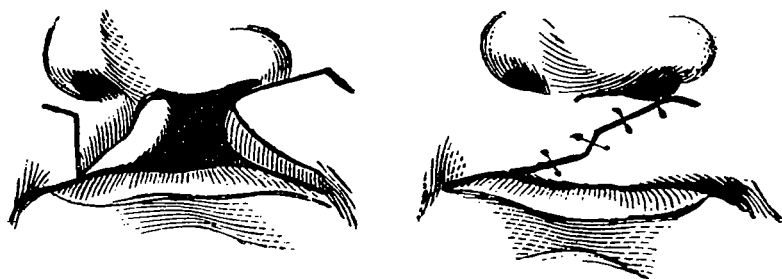
Millard adopted Giraldes' Z plasty in his operation.

As so often happens, one who is a partial authority makes a "snap" statement which, as there may be few true authorities on that particular subject, is taken up by others almost "parrot fashion." (I have done so myself.) The only trouble is, it is almost impossible to arrest the subsequent chain reaction, though sometimes it can be deflected and finally stopped. In order to check this misconception, both Berkeley and Giraldes were awarded a couple of pungent paragraphs in *Plastic and Reconstructive Surgery*, November 1961.

"Giraldes
actually put
the cupid's
bow up the
nose!"
M. Dean

To call the rotation-advancement method the Giraldes technique is inaccurate. Berkeley's only basis for grouping these two techniques together is that they are both supposed to involve the upper part of the lip. Any identification of the two in the literature is unfortunate, as Giraldes' conception did not incorporate any of the principles vital to the rotation-advancement approach. A casual observer *unfamiliar with either method* might at first glance think he sees a vague similarity. Yet when comparing equivalent diagrams of the two techniques he will see a fundamental difference in principle and multiple variances in detail. It will be even more obvious, of course, to those who have a working knowledge of either or both methods. Giraldes annihilated the cupid's bow-dimple component with a straight vertical incision which extended only a part of the way up the lip. He used no rotation whatsoever. Any advancement employed was directed in the opposite and unphysiological direction as a transposed flap which extended laterally in the lip below and out beyond the alar base. Thus a vital portion of the cupid's bow and dimple component not only has been destroyed but shifted to an unnatural upper lateral lip position. A result by this approach would fall far short of modern standards. It is humbly suggested that any happy results that are achieved by the rotation-advancement principle can be attributed to the fundamental differences between it and Giraldes' technique. And as the good Giraldes himself might have put it, "vive la difference!"

As Berkeley drew his conclusions from diagrams in Thompson's 1912 article, which in turn were but copies from Binnie, who got his information from Von Esmarch and Kowalzig, it seems only fair to old Giraldes to go back to what he really published in his 1869 book. First the diagrams,



then the sketches of his personal case emphasize the true disparity.



Although McDowell in 1966 suggested that the rotation-advancement "had some elements of a reverse Giraldes" (whatever that means), by 1968 Stark in his book, *Cleft Palate*, made no further effort to perpetuate the odious association. It would have been so much easier if our modern surgeons had let James Thompson settle the issue in 1912 when, after pointing out its various discrepancies, he dismissed the Giraldes operation with one simple sentence:

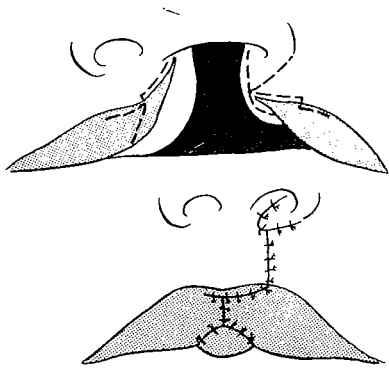
The result is a grotesque travesty of Nature.

The rotation-advancement is neither the reverse, a mirror image

nor any distant relative of M. Joachim Giraldes' 1869 misdemeanor.

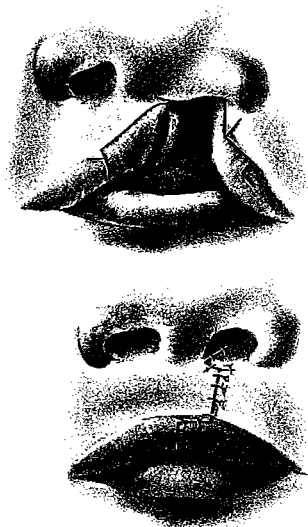
And that is not the end of the trouble with this fellow Giraldes. Born in Portugal, he was small of stature, being called "Petit Piccolo" by his colleagues. While performing an autopsy in 1856 he lost an eye and because of such a disfigurement evidently refused to be portrayed in any manner. In spite of great effort, no photograph, painting or statue of this famous Parisian surgeon serving at l'Hôpital des Enfants Malades could be found for you.

Several surgeons have associated the rotation-advancement procedure vaguely with an aspect of Veau's operation. McDowell expressed it this way:



The operation [Veau], a rather ephemeral one, entailed separation of the red from the white on both sides, incisions rather than excisions and construction of the vermillion from three separate flaps (which often led to lumpiness). . . . It did feature a small triangular flap from up near the columella which was fitted across into a spread incision under the ala, an idea which has persisted in some respects in Millard's more recent operation.

To see any important similarity calls for a stretching of the imagination. The fact that surgeons view the rotation-advancement as simply the interdigitation of two small triangular flaps at and near the nostril floor is discouraging. This may be due partly to my poor original orange-crate drawings, but the more recent revised diagrams make the comparison seem more far-fetched.



Others have pointed to Padgett and Stephensen's rendition of Veau's operation as being similar to the rotation-advancement approach. Here again, the fundamental Veau principle is shown as a straight-line closure with a vermillion interdigitation. The only possible similarity is the small triangular flap based superiorly and transposed across the nasal floor. This flap, however, is closer in size, angle, base position, function and principle to the family of flaps described by Collis, Blair, Trauner, Marcks, Obukhova and Wynn.

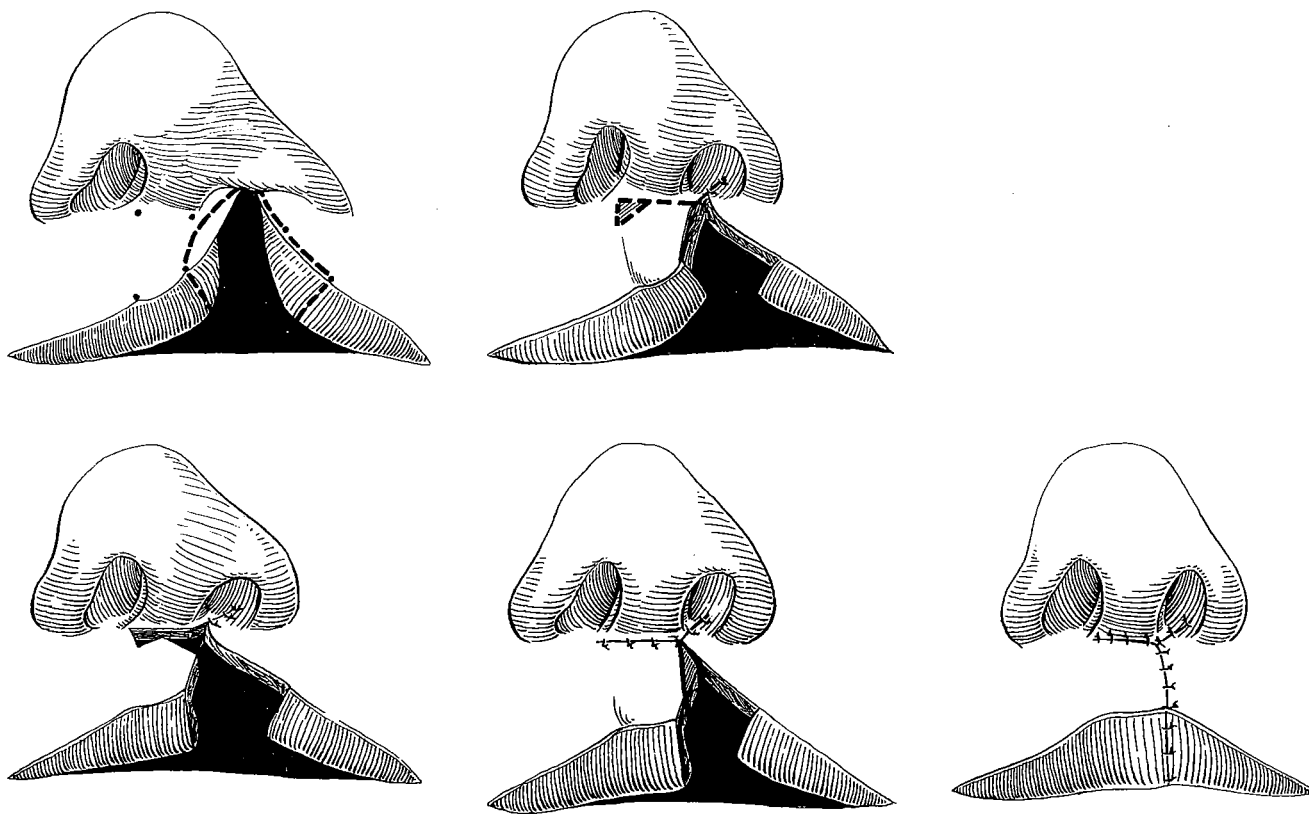
After my initial presentation of the rotation-advancement principle in Stockholm, Jacques Récamier, a student of Veau, gave me a reprint of a cleft lip paper he had published recently. It showed a high horizontal incision on the non-cleft side but in no way moved the cupid's bow into normal position or made any attempt to fill the gap with a lateral advancement flap. When he offered me the little paper he said:

We have discarded this as we found the scar deplorable.

Eight years later, with M. Récamier, he published a modification in which the high horizontal incision was extended across into the normal lip and a slight rotation was produced by a triangular excision.



Jacques Récamier



Galambos of Budapest, in Hamburg in 1964, said:

Récamier's method is based on the Veau procedure. The post-operative scarline however is of an entirely vertical direction; thus the correction of the alar base will not have been accomplished.

As expressed in my cleft lip section in Grabb and Smith, The triangle excision of the Récamiers, although not considered sufficient for adequate rotation, could be an adjunct when the normal side is too long vertically. Yet their Veau-type vertical straight line scar is considered a disadvantage, as the normal philtrum column has a gentle medial curve.

WHEN IS A Z NOT A Z?

As moderator for the cleft lip and palate panel during the International Congress in Rome, after listening to numerous presentations devoted to the use of the Z in cleft lip, I questioned the panel and the audience on the justification of such universal fascination for the Z and made the following accusation:

Promiscuous use of the Z-plasty in cleft lip surgery has become almost an obsession among modern plastic surgeons. Yet, the use of a Z-plasty against natural lines elsewhere would be abhorred. No surgeon would crisscross a forehead crease or the nasolabial line.

The Z has become undeservedly popular in cleft lip surgery probably because it can be used to lengthen the short sides of the cleft and actually assist in positioning the cupid's bow element. Yet a Z-plasty that interrupts the natural philtrum line and violates the philtrum dimple to produce an unnatural effect offers too few assets for the price demanded. The results may be *passable* when the scars consent to heal almost to invisibility or when the postoperative photographic records are so burned out with light that no scars can be seen. Otherwise such scars are *unacceptable*. Therefore, as each surgeon hastens to do his Z thing, one thought should be foremost: The scars we make will be our own and are *irreversible*. *They will not self-destruct in 60 seconds, 60 minutes or 60 years.*

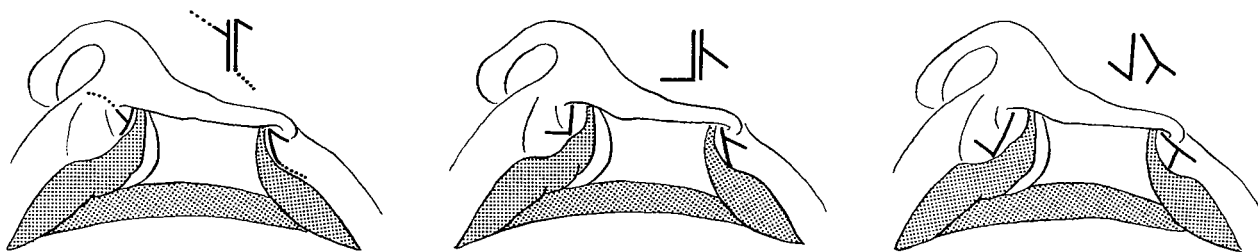
The Z got its greatest lip boost in 1959 when Clifford and Pool suggested that the one

procedure that accomplished two of the requirements in cleft lip surgery, positioning the bow and lengthening the cleft edges, was the "Z" plasty.

The Z-plasty, in all its possible forms, was then drawn by them on diagrams of the complete unilateral cleft using the adjacent

sides of the cleft as the central limb of the Z. They concluded:

It was soon apparent that all the repairs described in the recent literature become modifications of the "Z" plasty.



Bob Chase, Stanford University's Chief of Surgery, 10 years later summarized it this way:

All techniques for closure of the lip cleft are variations of a Z-plasty. The goal is to gain adequate length from the nostril floor to the vermilion ridge or junction to match precisely the contralateral side of the lip. The various methods which have been proposed (Mirault, Brown, Skoog, Tennison, LeMesurier, Millard, etc.) differ in the vertical level at which the Z-plasty is performed, but all represent the application of surgical geometry with an interdigitation of flaps.

It could as well be said to have qualities of a "Y" to "V".

Secondarily, and by chance, this may be partly true; primarily, it is not important. Strictly speaking, a Z-plasty is a double transposition of flaps or a double interdigitation. The rotation-advancement action in actual practice, or even in spirit, is neither. Yet in my original description I referred to the rotation-advancement as a "type of a lopsided Z and a half." This was another way of identifying it in a general plastic surgical manner and was more nearly true then than now. Since that original reference I have regretted the association because it is extremely misleading and only partly accurate. *Those who see the rotation-advancement principle as a high-level Z-plasty will have difficulty with its execution and will probably fail with it in complete clefts.*

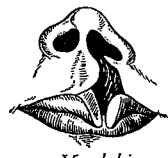Calling it a Z-plasty is like grouping a proud peacock (this bird was suggested specifically for such comparison by Vipin Buch, Bombay plastic surgeon) with a scrawny chicken. Both fowl are walking birds that lay eggs, peck for their food and are good to eat when well cooked. Yet their beauty, form, style and sacredness are quite different, and any similarity is both unintentional and at the genus *Gallus* level.



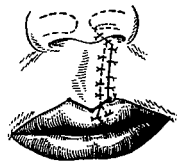
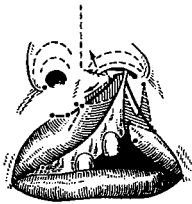
IF EVER THE TWAIN SHALL MEET

The rotation-advancement method may be a Z to some in the West, but in one area of the East it is considered linear. Russian Kolesov, of the Moscow Stomatological Institute, as late as 1970 itemized the cleft surgeon's role crudely as elimination of the cleft, lengthening of the upper lip and correction of the nasal shape. He then gave as the first grouping of modern cleft lip operations the linear or straight-line closure, which he discussed and dismissed in the following manner:

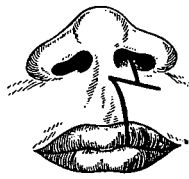
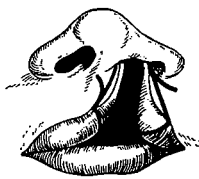The positive aspect of the linear methods is the cosmetic appearance of the line of the scar contained within the limits of the philtrum. However these methods do not permit adequate lengthening of the lip essential for wide complete clefts. After scarring, one half of the cupid's bow is pulled upwards, destroying the symmetry of the vermillion border line. Also several months after operation a creeping up of a triangle of mucous membrane is noted along the vermillion border.



Yevdokimov



Limberg



no МуЛларды

Then comes the hooker! Included in his category of so-called linear methods, Alexander A. Kolesov has grouped Yevdokimov, Limberg and Millard, explaining that they differed in the means of forming the nostril floor in complete clefts. Either he lost a hell of a lot in his translation or we are missing something in ours—maybe both! Yet diagrams are universal, and at no time has the rotation-advancement method simulated this Russian rendition. A communist plot was suspected, but as this event occurred before the recent policy of détente, it is hoped that new light will shine between nations and on methods even unto cleft lips and their treatment.

THE COUNTERPUNCH

Anyone who dares to propose a surgical technique becomes fair game in open season and exposes himself to honest, vigorous and constructive criticism by his peers. It is also his prerogative to evaluate this criticism and defend his stance with just reason,

or at least in good humor. As to past and future "potshots,"
John Trumbull said it best:

But as some muskets so contrive it,
As oft to miss the mark they drive at,
And though well aimed at duck or plover,
Bear wide, and kick their owners over.