

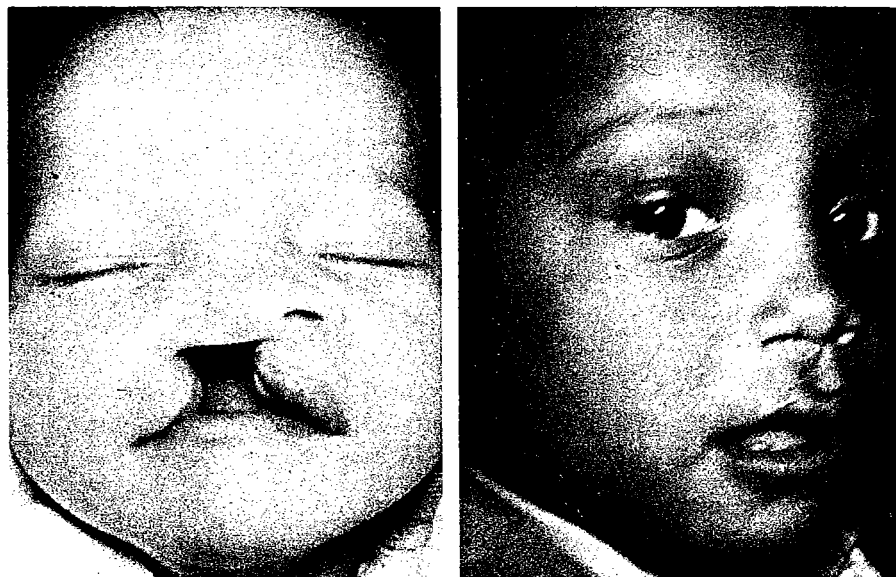19. *The Original Advancement Gradually Changes*

WITH two-thirds of the lip, including two-thirds of the cupid's bow, one philtrum column and the dimple, rotated down into normal position, the remaining one-third of the lip and bow must be produced as a flap from the lip element on the cleft side. Besides completing one-third of the lip, the flap must be fashioned to fill the high rotation gap in order to maintain the corrected position of the non-cleft element. The early description of making the most natural and effective use of the weak side emphasized two points. A high horizontal relaxing incision just under the alar base would release this component for medial advancement. In incomplete clefts any portion of the skin bridge referred to as Simonart's band with muscle in it could serve as the leading point of the advancement flap and thus conserve tissue usually discarded.

AMOUNT OF LATERAL LIP ELEMENT

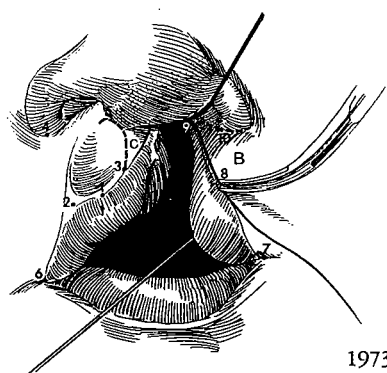
In complete clefts there is a varying amount of tissue in the lateral lip element. Pool in 1966 pointed out that the deficient lateral lip element with a "drop-off" from the alar base offered a problem in the rotation-advancement and, in fact, all methods. In some complete clefts there is an apparent deficiency of lateral lip caused by a contraction of the disappointed orbicularis oris. If this element is stretched gently, it will be found to have more tissue than is immediately evident and, consequently, is able to

supply the necessary piece of lip as demonstrated in this Jamaican case.




Yet there are some lateral lip elements which have actual deficiency to a severe degree. Then the tip of advancement flap B has to be taken from the nasal vestibule.

EXTENSIONS OF FLAP B INTO VESTIBULE



1973



1964

In wide clefts the stretch of the lateral vestibule of the flared ala is usually excessive, and when cleft closure is accomplished there is a bulging of redundant tissue blocking the nasal airway. This often necessitates wedge excision. Rather than excise, it is occasionally possible to incorporate some of the excess in the advancing tip of the lateral triangular flap B, as shown in this modern (1973) sketch. The amount available for this adjunct depends on the height of skin extension into the vestibule but is seldom as much as is shown here (1964).

PARING THE LATERAL CLEFT EDGE

The free border of the cleft element has to be pared a distance to match the opposing rotation edge. The length of this paring I described as

a matter of judgment and best fashioned by trial and error for each case.

Musgrave and Garrett, for Goldwyn in 1972, decried vagueness in the description of setting marks:

Unfortunately for the new surgeon, there are several techniques which start out their recipelike instructions with "Locate the point on the white line where it fades out." While this point can sometimes be found accurately, it is frequently so vague that the surgeon has great difficulty locating it.


Then too, this may not be the exact point for the termination of the lateral paring of the lateral flap B. A better guide is now available. Actually the limit of lateral paring can be set at a point on the mucocutaneous junction ridge from the cleft side commissure which is equal to the distance from the opposite commissure to the normal peak of the cupid's bow on the medial component.

Thus, a triangular advancement flap has been created with its greatest motion taking place in the upper portion of the lip. In fact, the high advancement of the cleft element renders it a "triple threat" to three vital problems: rotation maintenance, lip completion and correction of the abnormal flare of the alar base.

The next step was to free the nasal and lip attachments to the maxilla on the cleft side. The extent of this freeing depends on the case and must be quite radical in wide complete clefts so that there is less tension in the advancement.

Through the past 10 years certain adjustments have been made to facilitate these basic maneuvers. The horizontal incision and the freeing of the maxillary attachments for incomplete clefts are still much as described. In complete clefts, modifications in the advancement have been instituted. The upper horizontal incision varies and in the wider clefts is extended to curve around the alar base, as drawn by Pigott for the December 1968 *Plastic and Reconstructive Surgery*. This has been adopted as it allows more tissue to feed into this lip element and frees the alar base to allow it to be rotated medially. Of course, the *key* maneuver in the advancement campaign is the muscle suture which sets point 6 well into X.

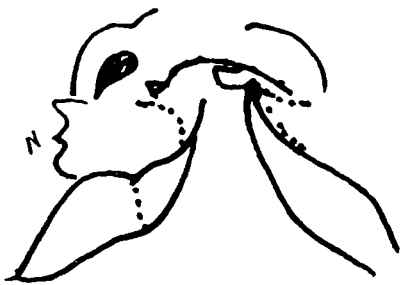
an important measurement



SHAPING THE HIGH HORIZONTAL INCISION

Although extension of the high lateral relaxing incision into a more radical circumalar direction was first presented formally at the Rome Congress in 1967 and published in *Plastic and Reconstructive Surgery* in 1968, one of my early Korean cases had an interesting diagram attached to it. Recently, while rummaging through old records, I came upon this postoperative rotation-advancement photograph with these diagrams. They date back to 1954 when I was first using a cleft side vermilion flap for overlap to the midline to accentuate the bow. A circumalar incision had been marked and the alar base cut free so it could move as a free agent into the side of the columella.

thus pre-dating
Pitanguy's
suggestion
9 years.



It took 13 years to come back to this general action. Also of interest is the fact that the measurement of the normal height of the lip (N) from the alar base to the height of the cupid's bow on the non-cleft side was used for designing a matching length on the cleft side with rotation and advancement.

Although the upper horizontal circumalar incision is curved, I suppose it might be undulated even more to fit the columella base. This thought was stimulated by a recent letter.

Gerald O'Connor, a student of Gillies in 1929-1930, wrote me in June of 1972. His last suggestions are food for thought.

Maybe I'm "Gilding the Lily" but that is what our work is all about . . . even to defeat the abnormalities that time, trauma or "Mother Nature" have presented to us . . . to create a functional, cosmetic and artistic structure, the so-called perfect norm, as best we can . . .

1. I do not believe there is a straight line per se in the body skin.

2. The lines are curved convex or concave or any straight line is broken either at the end or in the middle.

The base of the columella is curved in one direction or another. I'm talking off the top of my head but it seems to me that the upper part of your joining scar at the base of the columella is a straight line. If it exists as a straight line after your surgery I believe it can be improved by 1 or 2 small Z's.

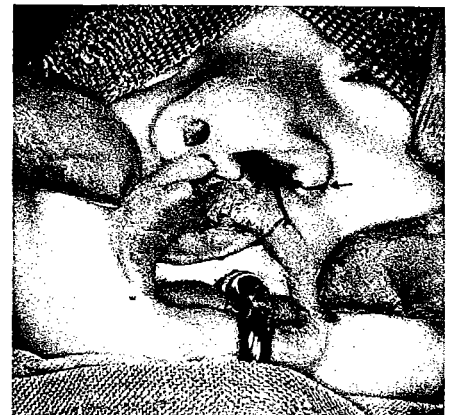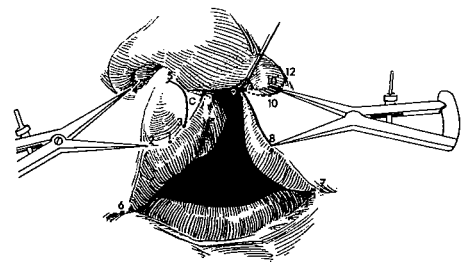
This is a possibility in an occasional case, and thank God Gerry was not talking about Z's for the philtrum line! Actually, the flowing curves of flap c and the alar base flap above eventually seem to cause the curving upper horizontal incision line of the lateral lip element to conform to an undulating crease join between these nasal and labial elements, somewhat as O'Connor indicated when he wrote:

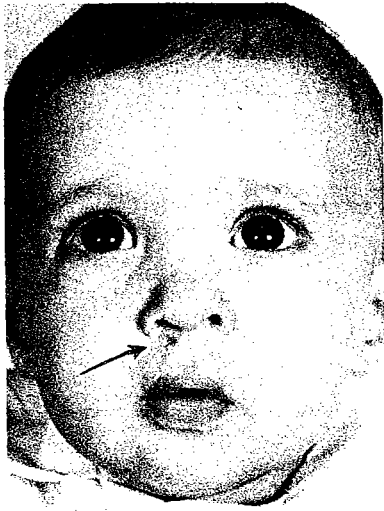If a surgeon draws a straight line with a ruler for an incision—even in the body midline—both sides of the body being different by bone structure, fat, muscle pull etc. after healing has taken place the so called straight line will become curved to some degree.

LENGTHENING THE LATERAL VERTICAL AXIS

Another axis of the lateral lip element which may be deficient is its vertical height from alar base to mucocutaneous ridge. When the distance is shorter on the cleft side than the normal (point 2 to point 4), there is a trick which satisfies the O'Connor curving principle but in a different plane. Raising the upper horizontal relaxing incision for the lateral advancement flap to include a bit of alar base lengthens the vertical height of the lateral lip element and shortens the elongated ala to the mutual benefit of both. This raised incision is shown with a compass marking in a complete cleft and with an arrow in an adhesion. Then, as the lateral flap B advances medially into the rotation gap, the prominence of residual alar base, still on the upper edge of the lateral flap, shifts into the nostril sill position in incomplete clefts and even to columella base in complete clefts, providing a natural outward swell somewhere along the nasal base.

I rarely get a contracture here because of the careful fitting.






DEFICIENT TIP

Occasionally the tip of the lateral advancement flap has a deficiency in tissue bulk which later will be reflected in a depression in that area of the lip construction. This can occur in a wide incomplete cleft with an attenuated Simonart's band or in a complete cleft with a small lateral lip element which necessitates the extension of the tip of the flap up into the nasal vestibule. Excess subcutaneous tissue and muscle along the edge of the cleft is often present and has to be trimmed to allow neat cleft edge-to-edge approximation. Recently this tissue has been salvaged as a flap to bolster any adjacent thin areas. If taken from the lateral element, it can be folded up under itself and tacked with a catgut suture to fill out the tip of the advancement flap.

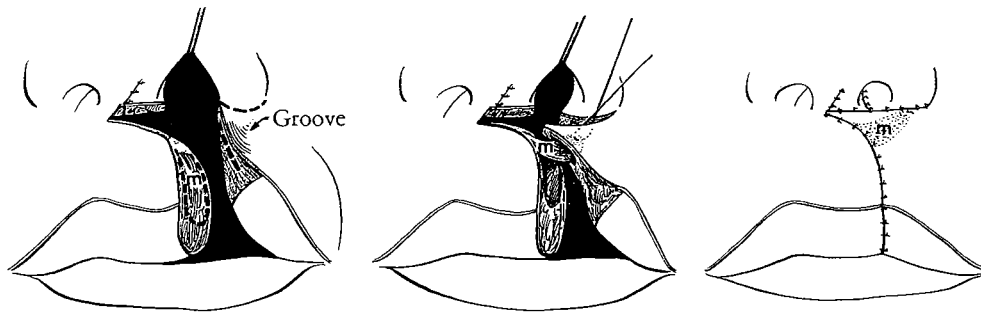


If taken from the edge of the medial element and based superiorly, it can be turned laterally to lie under and serve as extra backing again for the thin tip of the advancement flap.



If there is a depressed groove in the lateral lip element which sometimes exists and must be incorporated in the advancement flap, dissection of a pocket beneath the groove will lift the skin free to present a smooth external surface. Then the same medial muscle edge flap based superiorly can be actually plugged into the pocket to maintain the contour. This approach has been added and is predicted to be the most common use of the muscle edge flap in incomplete clefts.

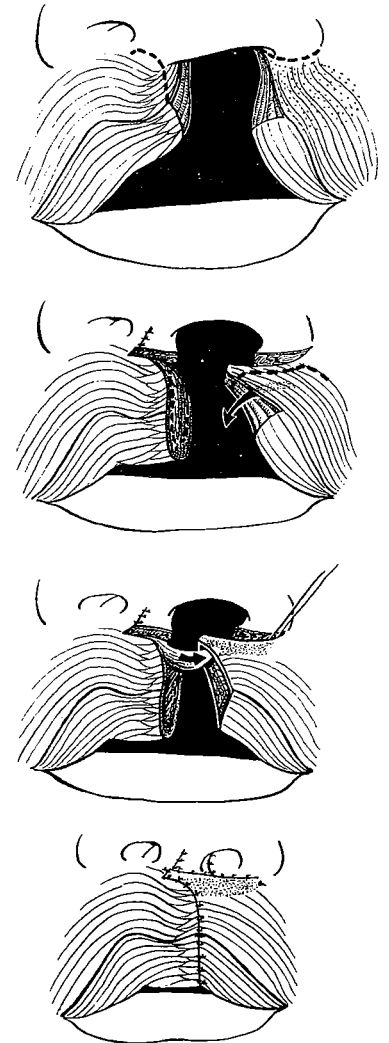
this is a good one!



ALIGNING THE LATERAL MUSCLE FIBERS

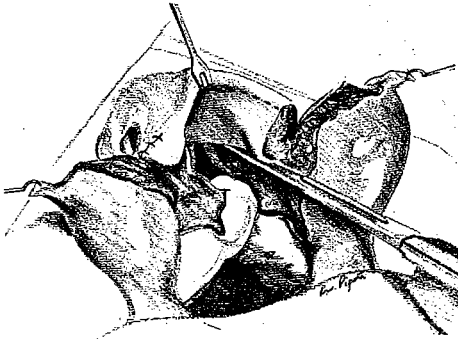
The advancement flap actually has a bit of both rotation and transposition in its action so that when it is cut free from the alar base and shifted into the rotation gap there is partial alignment of the muscle fibers. It is true, however, that the rotation component is not quite enough for end-on approximation to the fibers on the rotation side. Especially in those cases in which the lateral element has a definite muscle bulge, usually associated with some attenuation in its upper part near the nostril sill, an effort to improve alignment of fibers may be indicated. Leave the upper edge and tip of the lateral advancement flap intact for purchase of the key stitch to guide flap B into the rotation gap. One-half centimeter from the upper edge, the muscle can be divided transversely (*broken line*) so that after being undermined free from the skin and mucosa it can be brought down with its fibers in horizontal alignment. This maneuver leaves a muscle gap above which often is already deficient. A muscle edge flap taken again from the non-cleft side and based above can be transposed across the cleft and inserted into the upper muscle gap of the lateral element. This may turn out to be a sound and valuable use of the muscle edge flap.

Evidently, when the cleft is incomplete, the direction of the muscle fibers is less devious because postoperative incomplete clefts treated without radical undermining of the lateral lip musculature show excellent function by observation, palpation and electromyography. The extensive muscle dissection probably is best reserved for complete clefts and certain incomplete clefts with an exaggerated muscle bulge in the lateral lip element.



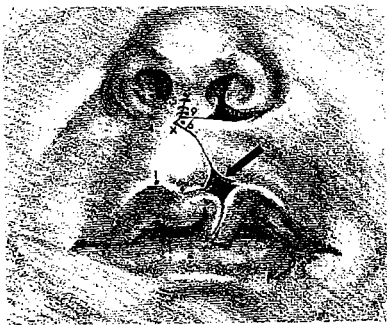
Early postoperative results have shown excessive reaction in the lateral lip element, indicating that such extensive muscle surgery for so slight a gain may not be justified.

FREEDING THE ALAR BASE FROM THE MAXILLA



In wide clefts, it is important to divide abnormal muscle attachments to bone by extensive freeing of the lateral lip element from the maxilla. This dissection, in severe cases, may be continued up into the vestibule with a scalpel to incise the nasal mucosa along the pyriform margin. The division of the alar adhesions to the retroplaced maxilla on the cleft side allows the recessed alar base to come forward. The resultant raw area in the lateral nasal vestibule has been left to heal, but recently the Muir-type mucosal flap has been found easily available. This is seldom necessary in incomplete clefts and so will be described in relation to complete clefts.

When the point of the advancement flap enters the depth of the rotation gap easily without tension, then the quintessence of the rotation-advancement principle has been satisfied. The rest is a matter of detail—but never underestimate the value of just such detail!




MATCHING EDGES

Take, for instance, the matching of the rotation edge to the pared edge of the lateral advancement element. Both have *convexities* which, when they meet, refuse to fit together, presenting a diamond-shaped divergence in the lower portion of the closure.

This had caused me and others much aggravation. The discrepancy had been overcome by *sutures under slight tension*, but tension at this point invariably resulted in a spread of the scar of union. Its strategic position at the peak of the cupid's bow on the cleft side produced a red area which by running into the red of the vermillion gave the effect of an asymmetrical contraction lift to the bow. Finally, two refinements were designed to reduce or prevent this blemish.

MAKING THE CLEFT SIDE CONCAVE

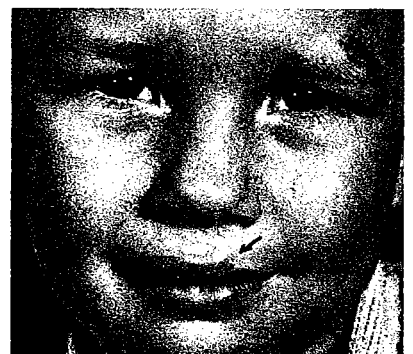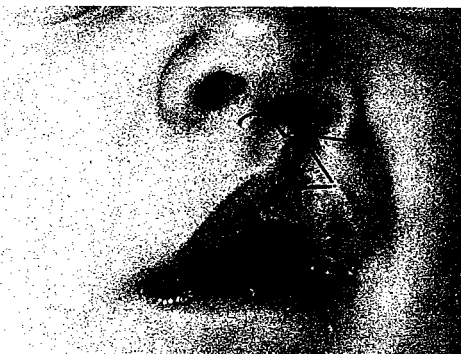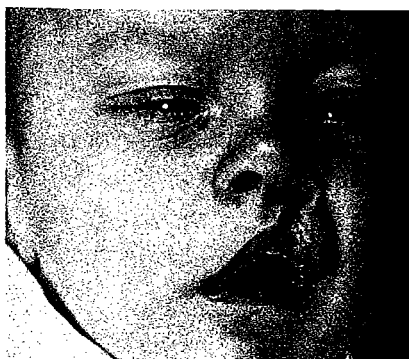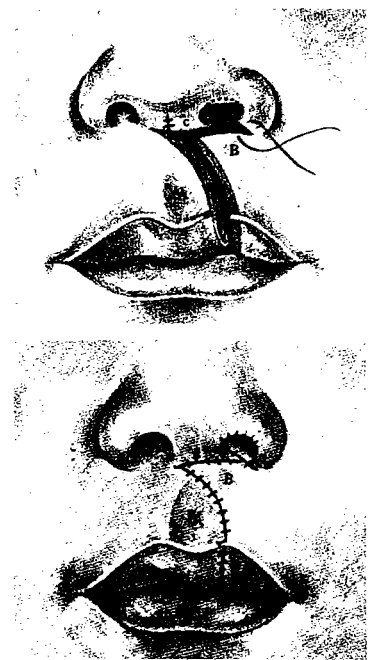
The curve of the philtrum column is convex on the dimple side but concave on the lateral side. Thus the convexity of the rotation incision is ideal. This then justifies paring *the lateral cleft edge to a slight concavity to fit the convexity* of the opposite side and reduce the tension of approximation, resulting in a better scar. Also achieved is an *increase in length* of this edge, which reduces slightly the distance of paring required and sets up the edge for a "white roll" interdigitation. Of course, if necessary, the amount and angle of concave excision can be increased to lengthen further the cleft edge.



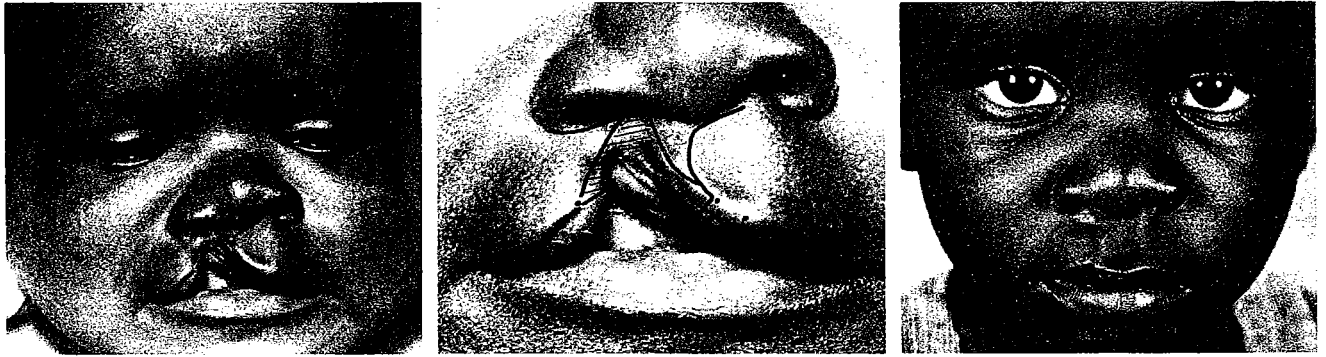
WHITE SKIN ROLL

Even when there is no spread of the scar, there is a small section of absent "white skin roll" which otherwise trims the entire normal vermilion border with a highlighted ridge. Thus the red of the vermilion "bleeding" vertically *without a break* into the pink of the scar is eye-catching and suggestive of a contracture; it needs an interruption. This effect has been achieved by salvaging a bit of the white skin roll during the lateral paring and transposing it as a skin flap 1 to 1.5 mm. wide by 2 mm. long across the mucocutaneous junction line. It should be as wide as the specific white roll it is bridging.

There are other advantages to the white roll flap crossing the cleft at the mucocutaneous junction line. It assures more perfect alignment of that landmark and avoids discrepancies such as may be seen in this boy, who did not have the advantage of the flap.



It also tends to *soften* the arc of the cupid's bow curve, which can be a bit abrupt when the two cleft edges are merely approximated.



The white skin roll interdigitation, conceived to camouflage the continuity of the mucocutaneous ridge, was first created in 1961 and reported in *Plastic and Reconstructive Surgery* in 1964. When it was first presented, astute Richard Webster of Brookline, Massachusetts, commented to me, "Say, that's a good one. Wish I had thought of it," which made me realize this little trick might be more important than was originally thought. Although it is possibly the smallest flap in plastic surgery, the deception it affords in some cases—certainly in the one shown below—has been rewarding.

