

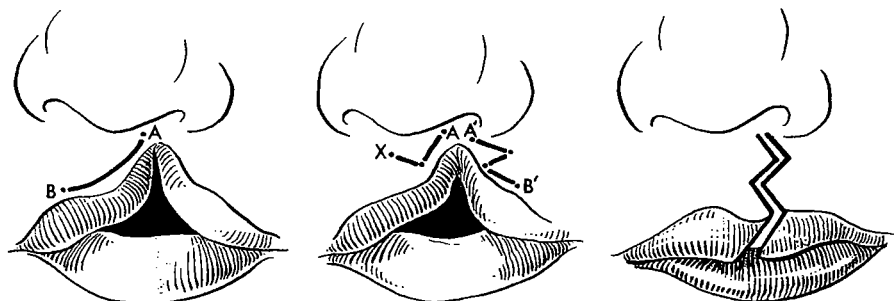
# 11. Preservation of the Cupid's Bow

## TENNISON

IN the summer of 1951, while a plastic surgery resident in Houston, I drove up to San Antonio to the Battle of the Flowers. San Antonio was the hometown of Charles Tennison, a disarming and seemingly easygoing "country boy" who had been operating on a number of lip clefts. He kindly invited me to his home and explained how he had been plagued by the upward contracture in the Negro of the more or less straight-line lip closure of the Blair-Brown method, because of which he had resorted to a Z-plasty and "some little ol' stitches." To facilitate the Z markings, he showed me his trick of bending a wire but made no mention of preserving the cupid's bow. In October 1951 at the meeting of the American Society of Plastic and Reconstructive Surgeons in Colorado Springs, Tennison presented his stencil method and demonstrated how the wire should be bent in three equal arms and placed on the cleft side of the lip for marking. Only half of the stencil was necessary to mark the medial side. It is reported that the results he showed, although quite good, were not a lot better than previously demonstrated by surgeons using the Hagedorn-LeMesurier principle.



Charles Tennison



## TENNISON AND MARCKS MEET

Kerwin Marcks of Allentown, Pennsylvania, realized the true value of Tennison's Z immediately and was excited about this preservation of the cupid's bow. After the meeting, while en route to Honolulu, Tennison and Marcks had an absorbing discussion on cleft lip.

Later, in his 1952 publication, Tennison outlined the important factors:

1. Adequate muscle approximation with muscle of the lip brought into as nearly as possible the normal transverse alignment.
2. Good skin coverage of the lip with the suture line placed in such manner that subsequent contracture of the scar is reduced to a minimum.
3. The production of approximately normal anatomy of the lip with preservation of the "Cupid's Bow." Any minor residual deformity should be easily corrected.
4. A full red border of the lip with normal "Pouting" protrusion of the lower portion of the lip.
5. Adequate floor of the affected nostril and correction of as much of the nasal deformity as possible at the primary operation.
6. Elimination of as much undermining of the face as is consistent with good closure.
7. A simple means of arriving at the locations of incisions so that standardization of the procedure is possible.

## CARDOSA

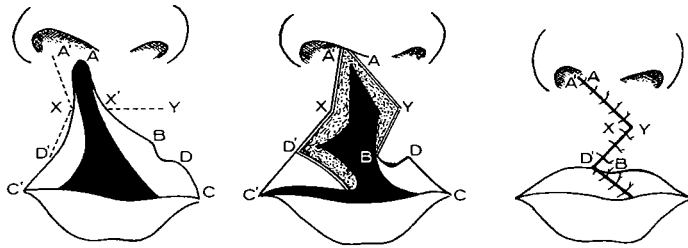


*Duarte Cardoso*

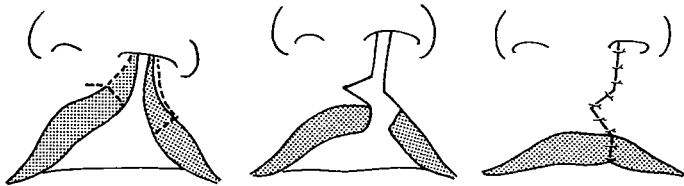
Independently and simultaneously with that of Tennison came the work of Duarte Cardoso, innovator and boatbuilder of São Paulo, Brazil. He also described a method for preservation of the cupid's bow and noted:

In a remarkable number of cases, the so-called cupid's bow is fairly individualized in the medial margin of the fissure. The usual techniques for repair of harelip disregard the preservation of the cupid's bow.

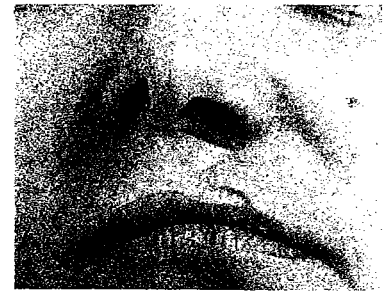His method was less sophisticated in its design. In fact, this



general approach is slightly reminiscent of a method credited to M. Jalaquier as early as 1880.



Plessier published a result of the Jalaquier method which revealed the surgeon's failure to place the cupid's bow correctly. This sometimes happens even with the Tennison markings when the surgeon does not understand the design.



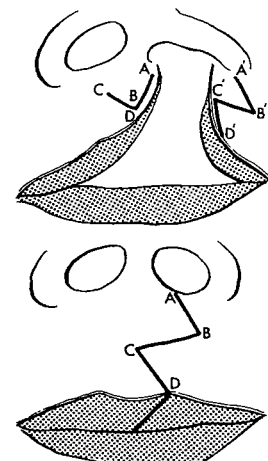
### MARCKS'S REMARKS

Tennison made no further effort to promote his method, to modify it or to give a later follow-up of his cases. Marcks, however, carried his banner in 1953 and did much to popularize the new principle for he felt the approach was "so different and so much more practical." He advised beginners to use the stencil to avoid inadvertently reversing the Z. Once "the pattern becomes mentally automatic" he preferred to measure and mark with calipers. He first noted an important landmark that is essential to the marking, cutting and fitting of the lip elements:

The mucocutaneous juncture of the normal lip is accompanied by a skin prominence running less than 1 mm. above and parallel to it. In the cleft lip it runs along both elements but disappears near the cleft, even though the mucocutaneous border continues for a variable distance more. For want of any name known to us, we choose to call this the "mucocutaneous ridge."

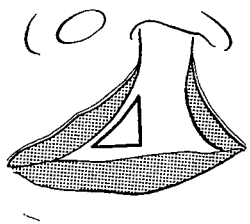


*Kerwin Marcks*



This ridge, or "white roll" as Gillies termed it, has become more important as the sophistication of this surgery increases. Marcks also noted:

The scar which enters the peak of the cupid's bow serves to accentuate this peak. Scar contracture at this point, within reason, is not objectionable. In the first several postoperative weeks, this point is sometimes rather markedly drawn up by scar. All of our cases have dropped to a normal level within several months, however, excepting those in which the variable flap was made too thin.

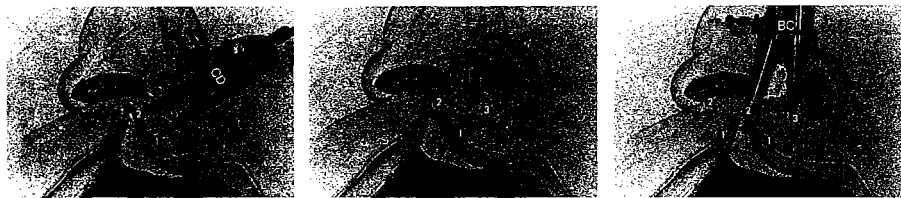

Marcks marked the Tension-type Z-plasty and then varied the angles of the Z until they almost resembled those of the quadrilateral flap of LeMesurier. Like Brown and McDowell, Marcks considered the lip deficit a triangle at the inferior border of the lip which he felt was corrected by a triangular flap placed at the inferior position. His most recent diagrams clarify his markings for complete clefts.



*Medial element*

Point 1 is placed at the termination of the medial mucocutaneous ridge and point 2 in the skin of the columella ridge. Marcks calls the distance between 1 and 2 "caliper distance" (CD). Point 3 falls on an imaginary line between 1 and 2 and perpendicular to it, pointing off a triangular flap based superiorly. The length of the base of this flap he calls "base caliper" (BC).



*Lateral element*

Point 1' is placed at the termination of the lateral mucocutaneous ridge and point 2' on the extension of the alar ridge as close to the mucocutaneous border as possible. "Caliper distance" is arced from point 2' and "base caliper" is arced from point 1', and where these arcs cross is point 3'. The flaps are marked, then incised and finally fitted together with interdigitation of the mucous membranes.

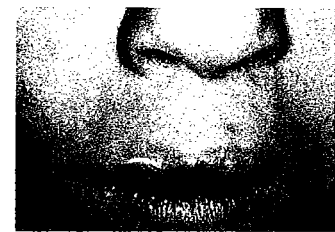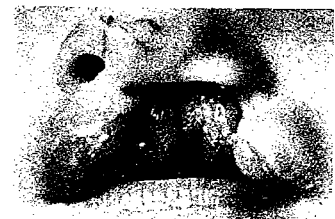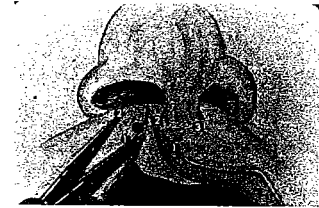




If the distance from 1' to 2' is longer than caliper distance, a superior lateral triangle may have to be excised. If the distance from 1' to 2' is less than caliper distance, the lateral paring will have to be extended laterally.

In 1972, Marcks summarized:

For the past few years we have utilized equiangular flaps to simplify the markings. Some lips look very good and some are a trifle short, but none are long. Any angulation greater than a right angle could readily produce a longer lip or the extension beyond the normal philtrum ridge could be responsible for a longer lip. This should never be done.

Here are two excellent cases by Kerwin Marcks which show the best that this approach can achieve. The cupid's bow is down and reasonably well balanced. The nose has been improved. The only possible objection is the unnatural position of the fine scars, which do not imitate the philtrum column of the normal side as they encroach on the philtrum dimple.



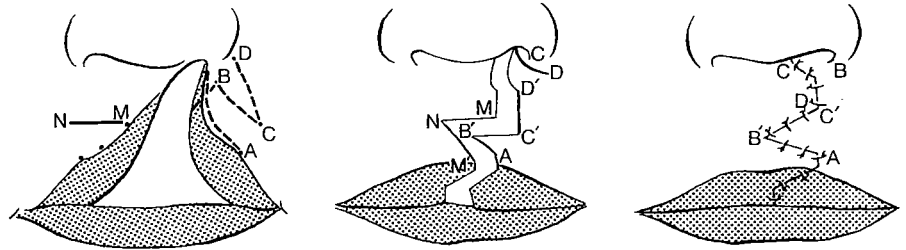
## OBUKHOVA

Several years after Tennison, Cardoso and Marcks, Lidiya Maksimovna Obukhova, highly respected by her colleagues and honored by her country with the Order of Lenin, pioneered the inferior triangular flap and preservation of the cupid's bow in Russia. In 1957 she published a report of an operation similar in principle to that of Tennison but adding an enlarged Collis-Blair type of lip flap for reconstruction of the nasal floor. In



*Lidiya Obukhova*

the 1958 scientific works of the Samarkand Medical Institute, Obukhova reconfirmed her faith in this method and mentioned its correction of the nasal ala and the important double closure of the nasal cavity and alveolar cleft.



Today, at the age of 75, L. M. Obukhova, whose early work continues to influence some of the younger Soviet cleft lip surgeons, is still an active operator in Samarkand and has a doctor daughter who is carrying on her work.

#### ANOTHER RUSSIAN RENDITION

A. A. Kolesov of the surgical division of the Pediatric Department of the Moscow Medical Stomatological Institute in 1970, for a handbook put out by the U.S.S.R. Ministry of Health as a standard textbook for students of stomatology, divided modern lip methods into three groups: linear closures, triangular flaps and the quadrilateral flap. He dismissed the first and last groups. In his expression of preference for the methods of Tennison and Obukhova, he noted the possibility of obtaining any lengthening needed, depending on the size of the triangular flap borrowed from the cleft side, and the potential for precise planning which simplifies its adoption by young specialists. He did acknowledge that, in interrupting the philtrum,

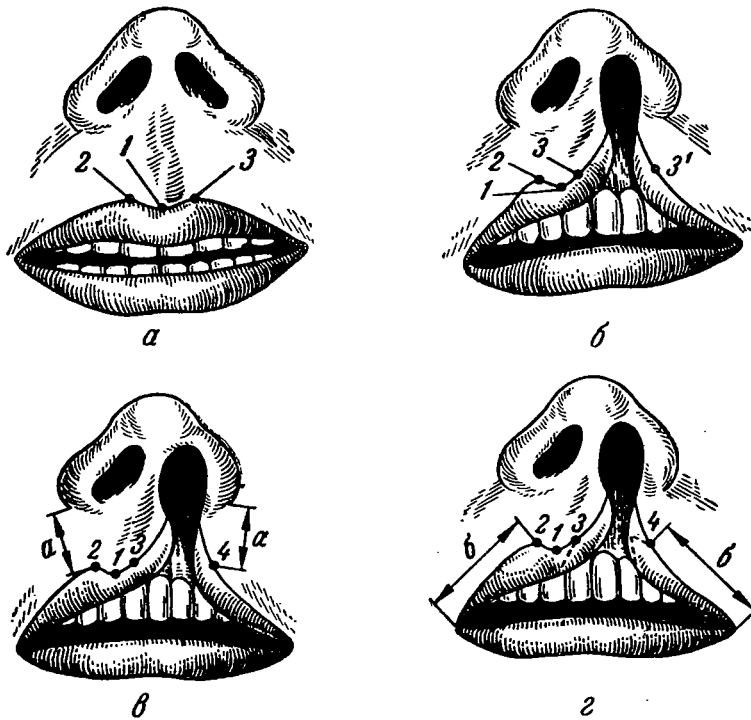
*borrowed  
stolen!* ?

The transverse direction of the post-operative scar lessens the cosmetic result of the operation.

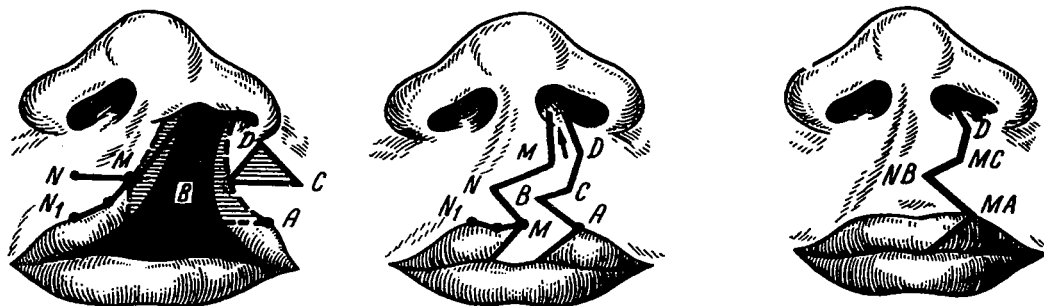He nevertheless recommended this type of operation for incomplete clefts without nasal deformity.

For clefts with nasal distortion, Kolesov used Limberg's

method of measuring, which is sound for almost any lip operation.



He then combined Obukhova's inferior triangular flap with Limberg's superior triangular flap to the nasal floor. In actual priority, this is merely a marriage between Tennison's principle and Collis' flap, which Obukhova combined in 1957 and Randall simplified in 1958.




Kolesov's excision and discard of a triangle of valuable lip tissue (lined transversely), as he described, "between the triangular flaps of Limberg and Obukhova," is uneconomical, and the scar interruption of natural lines presents the same objections already applicable in earlier cases with similar methods.



*Robert Hagerty*

## HAGERTY

Robert Hagerty, in spite of his Bostonian brogue, after training with Peer and remembering southern hospitality at Duke University School of Medicine during his student days, turned south and settled in Charleston. In 1958, at the University of South Carolina, he described an inferiorly placed lip flap similar to Tennison's which interdigitated a small triangular flap from the cleft side to dovetail into an inferior cupid's bow releasing incision on the medial side. His plan was a little complicated, with the normal side  $A$  to  $B = A''$  to  $B'' +$  width of flap  $X' = A'$  to  $B' +$  width of the dart  $X$ . He dropped a dotted line from the mid-columellar base to the center of the bow and joined this with a second dotted line extending perpendicularly from the height of the bow on the cleft side. The position of the dart was determined by bisecting the distance from the intersection of the vertical and horizontal dotted lines to the center of the bow. Actually, Hagerty is a great fellow, both in stature and in person, and more uncomplicated than the intricate planning of this design would indicate.



## RANDALL



*Peter Randall*

Peter Randall, at the University of Pennsylvania in 1959, did to the Tennison-Marcks principle what Brown and McDowell did to the Mirault-Blair: He simplified and reduced the size of the triangular flap. As he said,

The flaps used by both of these surgeons (C. W. T. and K. M.) are quite large and although these are shown to produce excellent results in children with wide defects, in narrower clefts it would seem that a much smaller flap could be used to better advantage.



Randall, the master of measurements, reduced this lip design to a mathematical pattern and was awarded an Honorable Mention prize in the Foundation Essay Contest for his work and numbered markings.

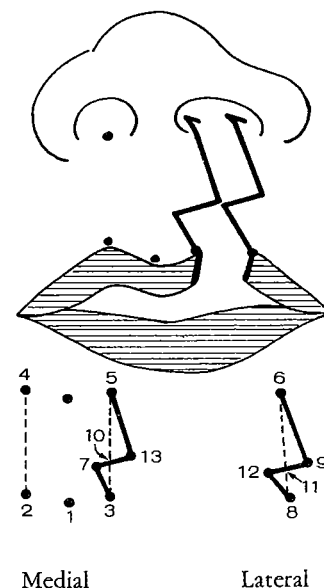
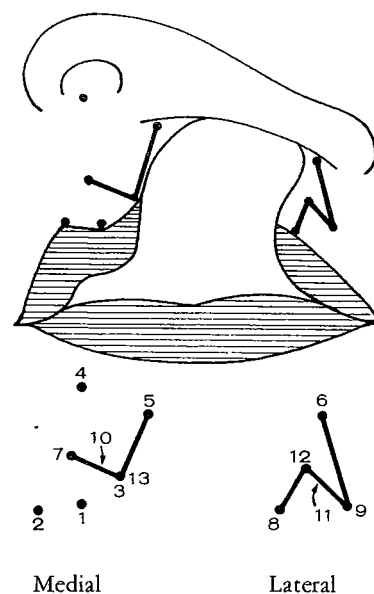
1. Marking the superior peaks of the cupid's bow on the cleft and the non-cleft side (3,8).
2. Measuring the vertical height on the non-cleft side from the base of the columella to the superior peak of the cupid's bow (4-2).
3. Measuring the vertical height of the medial flap (5-10).
4. Determining the difference between these two measurements (4-2 minus 5-10) which will be the distance across the lateral triangular flap (11-8)—or the distance the cleft side of the cupid's bow must be brought down to bring it into normal position.

Points 2 and 3 mark the peaks of the bow, and 4, 5 and 6 are the same as in the Brown-McDowell design; 5-3 is marked, and then 3-7 is extended about at a right angle but never past the line 4-2. The difference between 4-2 and 5-10 should equal the distance across the lateral triangular flap 8-11. Point 12 is picked so that 12-8 equals 12-9. The position of 12 is determined by the tissue available. Tissue medial to 8-12-9-6 is discarded. A small triangular flap at the base of the ala, similar to that of Collis and Blair, is fitted into an incision inside the base of the columella.

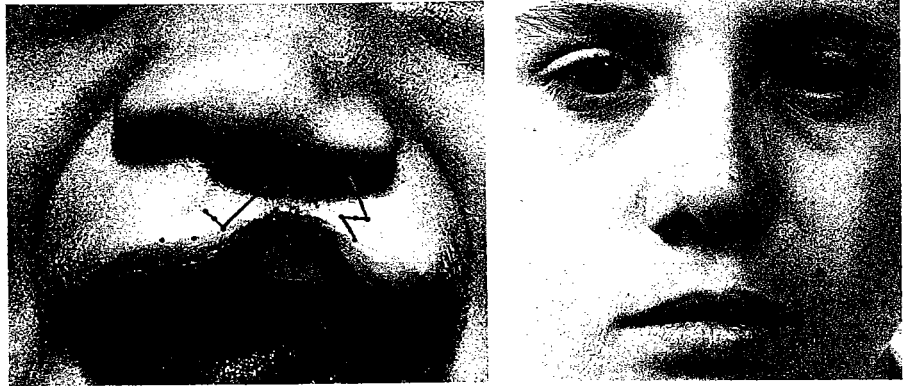Randall noted in 1971:

After 14 years of use the only change has been that the triangular flap is made no wider than 4 mm. in the infant.

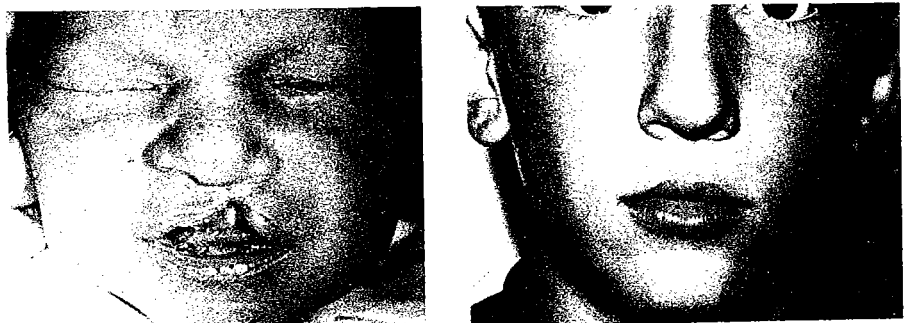For his example Randall chose and sent me what appears to have been an incomplete (halfway) cleft which is somewhat difficult to evaluate because of the photographic shadows. It is a case he first published in *Plastic and Reconstructive Surgery* in April 1959. After 14 years, a submucous resection and a vermilion surgical touch-up, the case exemplifies an excellent result of the small inferior triangular flap. One cannot but be concerned that the design plans such a large amount of tissue discard. The zigzag scar across the normal philtrum column may catch the eye under certain lighting, and its low insertion tends to smooth out the



dimple, but because of the reduction in size of the flap the unnatural effect seems to be less noticeable. The nose, which was not severely deformed, is improved but still retains some of its original asymmetry.



Recently Randall presented me with another incomplete cleft with an eight-year follow-up. Although the flat lighting hides half of the fine scar in a result that is quite pleasing, the zigzag across the philtrum is discernible.



In 1971 I learned several of the secrets of Peter Randall's success. In the backyard of his Georgian home, built by his father in the Chestnut Hill area of old Philadelphia, he has two important landmarks most useful in summer. One is a large smoke-house apple tree in the shade of which he can contemplate numerical lip points. The other is a horse trough which he and Posey fill with beer and ice for friends who come to help her distract him from his numbers racket.

And so, two Pennsylvanians not only embraced the Texan Tennison principle but improved it, each in his own way and not without discourse between themselves. Kerwin Marcks, of

Dutch descent, short of stature, large of heart, is always game for a joke. He called up Peter Randall one night and, in an attempted change of voice, said:

“Dr. Randall, this is Dr. Schniggelfritz and I have a baby with a cleft lip. Do you do this type of case?”

“Yes, Doctor . . . er . . . Schniggelfritz, I am very interested in cleft work.”

“Well, Doctor, that is interesting. Have you heard of a Dr. Kerwin Marcks? Is he any good?”

“Why yes, I know Dr. Marcks and he is very good.”

“But Doctor, he’s getting on in years. I’ve heard he may be a bit senile.”

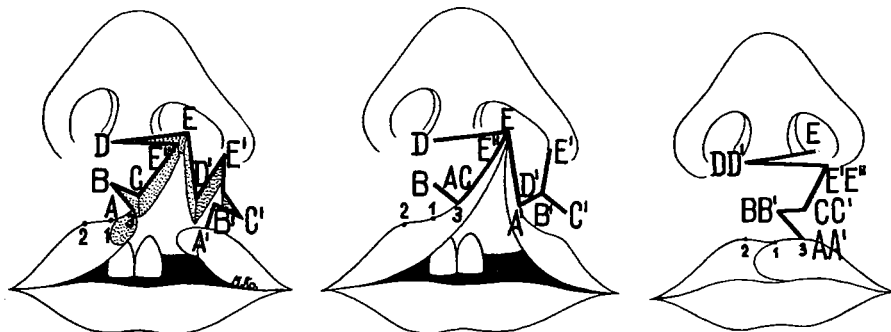
By now, Randall was on to Marcks’ ruse and answered:

“Dr. Marcks is mature but all the more experienced, Dr. Schniggelfritz!”

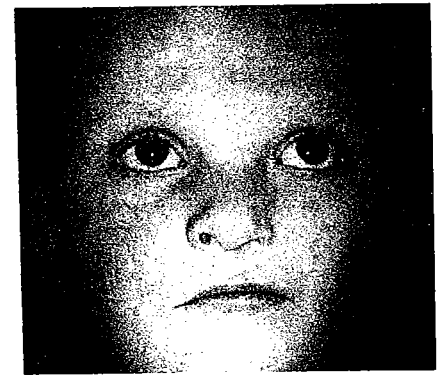
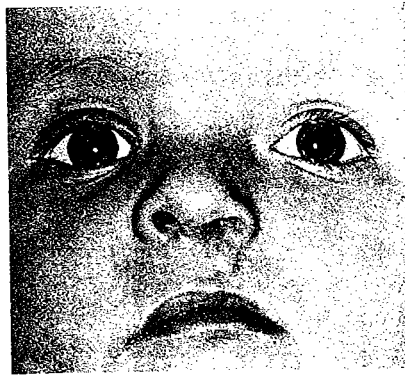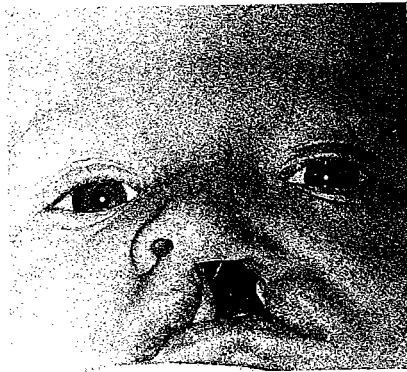And they both had a good laugh.

#### TRAUNER CHANGES

Meanwhile Trauner, who combined his “Z-plasty at the entrance of the nose” with the LeMesurier method, began to find the lip on the cleft side often becoming too long. With the introduction of the Tennison Z principle and later Randall’s reduced version, Trauner, appreciating the value of preserving the natural bow, substituted Tennison-Randall for LeMesurier in the lower portion of the lip. In his diagrams  $AB = A'B'$  and  $BC = B'C'$ . He also overlapped the non-cleft side with vermilion from the cleft side and turned a larger septal flap across the floor of the nose to maintain the release of the alar base from the maxilla.



This patient operated on by Professor Trauner shows the early healing phase and the result at eight years.



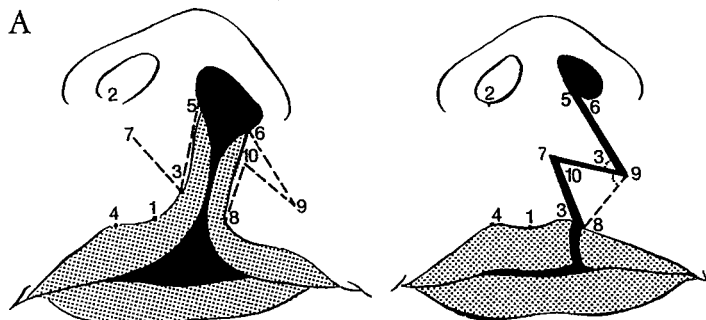
In 1972 in Miami, Trauner noted that this change did not produce as strong a cupid's bow but the one preserved was more natural. He also reported to us that 50 percent of his noses, after his primary surgery, resulted in a symmetrical nasal tip. His many years of experience prompted him to conclude that scars improve so much with time that secondary corrections should be postponed for years.

#### A Z FRANÇAIS

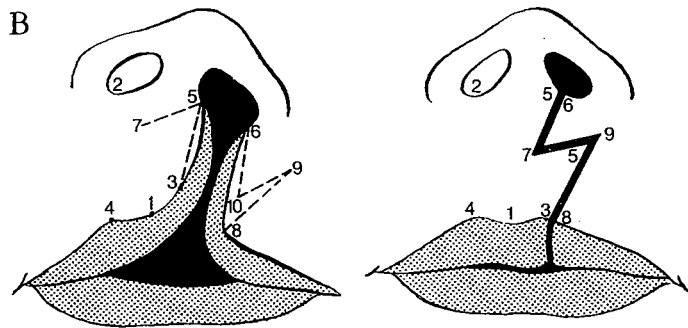


Pierre Petit

The gentle Professor Pierre Petit of Hôpital Saint-Vincent de Paul, Paris, was one of Veau's favorite students and carried on the master's great work. In 1961, with Borde and Malek, he described his rendition of the Tennison triangular flap procedure, claiming it to be "*une solution mathématiquement parfaite.*" Two designs were presented. Design A marked the medial flap 7-3-5 with an angle of 60 degrees and the base above, while the lateral equilateral flap 8-10-9 had its base below. The transposition of these two flaps lengthened the cleft edge to equal the normal distance from 2 to 4.

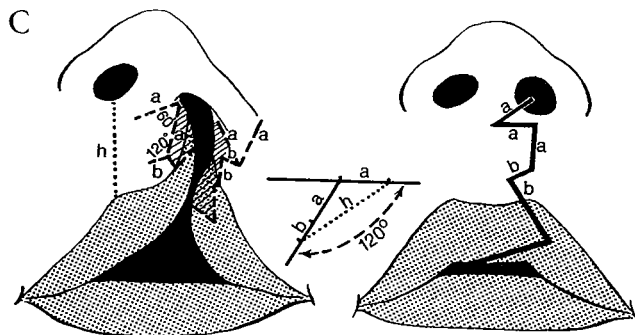


To improve the position of the alar base design, B reversed the position of the bases of the two flaps. Here again, the sum of the width of the two flaps' bases equaled the normal distance from 2 to 4.



In 1972 Petit wrote me of modification C, which combines Trauner and Tennison somewhat as Skoog combined them. He explained it this way.

If the hypoplasia of the lip is too marked then two triangular flaps on the lateral border of the cleft are determined geometrically as with the other designs. The double Z provides a double advantage—it gives a good inrolling of the nose and a good release of the lip "*avec un très bon arc de cupidon.*"



He also explained that he continues to close the anterior palate at the time of lip closure as Veau did but using only the nasovomerine layer without the overlapping mucoperiosteal flap.

This method for Petit offers the security of geometric accuracy but as in all Tennison-type Z's, the cupid's bow is positioned at the cost of scars crossing natural lines and destroying or encroaching upon the philtrum dimple.

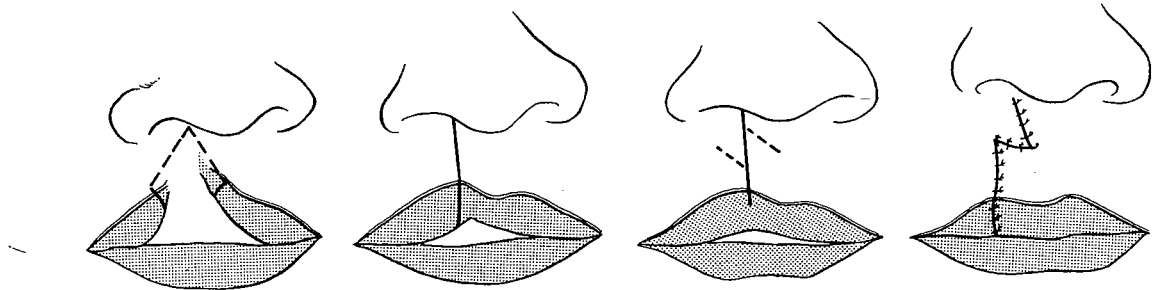


Castro de Lemos

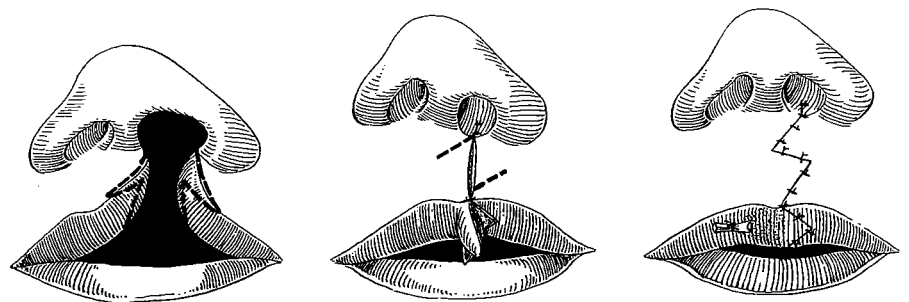
## SIMPLE Z

Some surgeons varied their use of the Z-plasty principle by paring the cleft edges first and then marking and cutting the Z in the primary operation, preserving the cupid's bow in the process.

Perseu Castro de Lemos of Recife, Brazil, in 1956 and again at the Congress in Rome in 1967, advocated freshening of the cleft edges, preserving the residual cupid's bow plus a Z-plasty which he called cheilo "Z" plasty.



Victor Spina of São Paulo, with O. Lodovici in 1960, also designed a straight-line paring of the cleft edges, and they too had the sophistication to preserve the residual cupid's bow. Then they lengthened the vertical height of the short cleft side with a Z-plasty. An interesting aspect of their plan was the denudation of the excess vermilion flap from the cleft side used to bolster the non-cleft side.



## MANY JOIN THE RANKS

The obvious value of preserving the cupid's bow was responsible, along with the many minor modifications, for the gain in popularity of Tennison's principle. Lewin's study in 1962 revealed that the Hagedorn-LeMesurier method was used by 42.8 percent of American and Canadian surgeons and that the Tennison-Randall was coming up fast with 37.4 percent.

## OHMORI

Ohmori of Japan in 1963 expressed appreciation for the Z as an improvement over the straight-line closure:

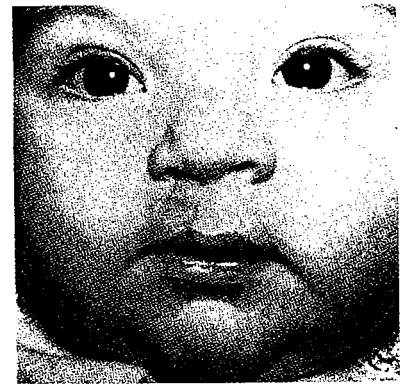In the past the surgical treatment of primary cleft lip consisted of hand massage to the cleft lip area to bring elongation of the cleft lip and then the defect was sutured in a straight line. The results of this procedure were, in almost all cases, very poor. Today we usually apply the triangular flap method to repair the cleft lip.

## BOSTON BRAD

Some surgeons were so overjoyed to get a bow that they accepted the zigzag scar with a cavalier attitude. Bradford Cannon of the Massachusetts General Hospital discounted this disadvantage in the Medical Intelligence section of the *New England Journal of Medicine* with

The angular scar is inoffensive.


Inoffensive to whom?!




## WANG

Mark Wang, at the Albany Medical College in 1960, tried to combine the best of LeMesurier and Tennison. He claimed:

The normal cupid's bow is preserved and, by the use of a quadrilateral flap, the advantages of accurate predetermination of the final length of the repaired side, stepladder suture line and, finally, the central protrusion of the upper lip are retained.



Mark Wang



According to Wang:

The measure of a successful congenital cleft lip repair is not in the immediate result but how well cosmetically and functionally it keeps pace with the growth of the patient.

He has saved the cupid's bow, which is good, and his broken-line closure reduces contracture but presents an unnatural line. Of greater concern to Wang must be the threat of his quadrilateral flap's simulating that of LeMesurier with gradual unattractive elongation of the cleft side of the lip with *growth*.

Soon after Wang combined LeMesurier and Tennison, two British plastic surgeons, Joss and Rouillard, in 1962 gave their criticisms of the LeMesurier, Tennison and Randall procedures:

Randall has described a modification of Tennison's method whereby the lip markings are drawn and equated mathematically, but this is not felt to be an advantage over the simple but effective bent wire technique. . . . Whatever the operator's preference in regard to skin marking, the incisions once made are irrevocable (particularly with the LeMesurier repair) and mistakes become magnified as the child grows. One major criticism which seems justified in both LeMesurier's and Tennison's methods is that the nasal deformity is only partly corrected, the Z-plasty being essentially in the lower half of the lip.

#### DAVIES

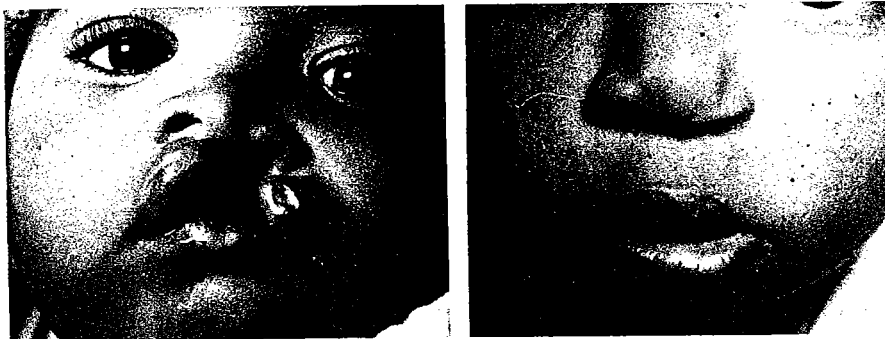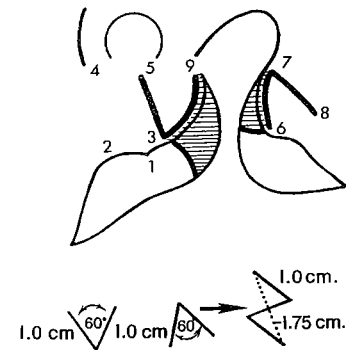


David Davies

In Cape Town, South Africa, nestled on the other side of Table Mountain from the harbor, is Groote Schuur Hospital, the site of Barnard's first cardiac transplant. Here also, and at the University of Cape Town, is the dashing David Davies, son of another plastic surgeon, David Davies, Sr. In 1965 Davies presented a simple method for utilizing two equal flaps of a pure Z-plasty to give a predetermined height of the lip on the cleft side. He advocated the use of various-sized steel triangles with handles attached to aid in the systematic marking of the flaps. Having done so many operations, he now seldom bothers with metal flap markers but measures first the height of the lip on the normal side (2-4). He then marks two equilateral triangles,



5-3-9 and 6-7-8. On the basis that a Z-plasty made with 60 degree angles will cause an increase of length along the main axis of 75 percent, each limb must be four-sevenths of the normal (2-4) distance in order to achieve a final lip length on the cleft side exactly equal to that on the normal side. In other words, if the two flaps are marked with an angle of 60 degrees with a length of 1 cm., the final lip length will end up 1.75 cm. Or when the lip is operated on at three months, the length of the normal side is usually about 1 cm., which calls for triangles of 0.58 cm.

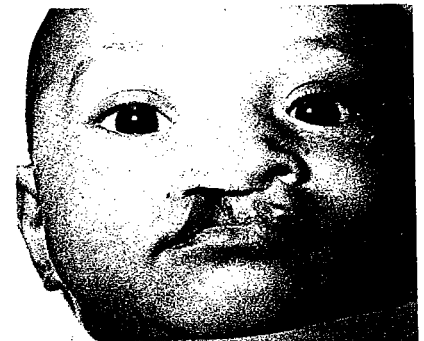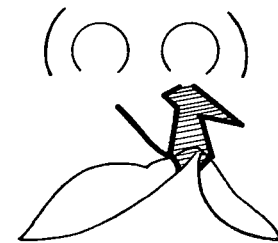


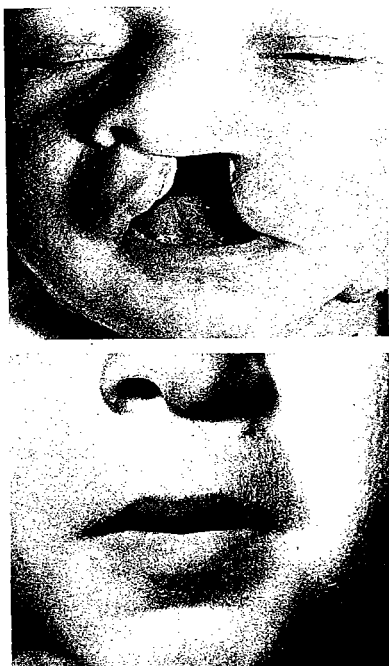Of course, more tissue has to be discarded in incomplete clefts to ensure perfect lip length.

Davies prefers the full Z-plasty for the complete cleft. In 1971 he admitted that the most common criticism has been that the horizontal limb of the Z-plasty crosses the area of the philtral ridge on the cleft side. He feels that the ascending Z-plasty limb is rarely noticeable and often mimics a philtrum ridge. The horizontal limb often fades well, he claims, but he admits:

The most troublesome and noticeable part of the scar is the point and superior ascending limb of the Z-plasty. It sometimes has a tendency to form a miniature trapdoor or bridle scar.

One case forwarded to me by Davies had been photographed with strong crosslighting, revealing a good lip even without preservation of its philtrum dimple. The light exposure had softened the effect of his obviously excellent scar crisscrossing the philtrum column line. His accompanying comments were pertinent:



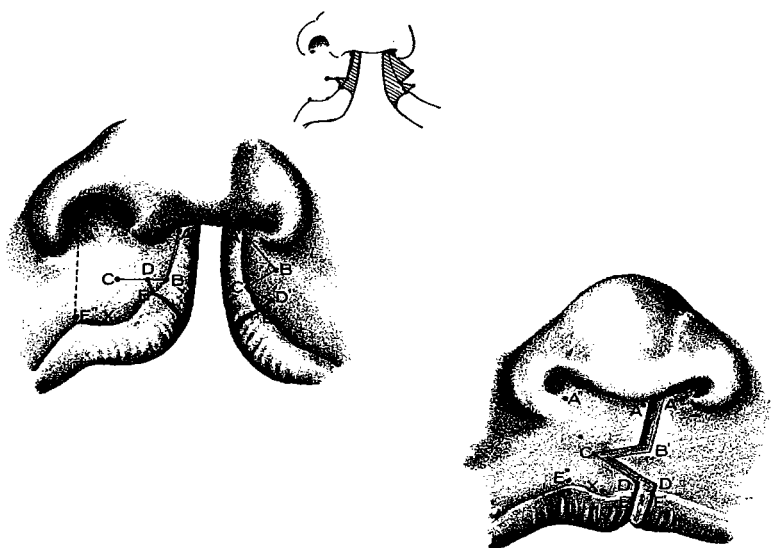


However, there is still flattening of the nose on the affected side and the indirect lighting across the lip brings out an annoying facet of the Z-plasty which often manifests itself no matter how careful one's technique and that is the slight raised prominence of the tip of the upper flap. I make a point now of snugging this tip well down into the apex of the V with a subcuticular stitch in order to prevent this rising up postoperatively.

In spite of his own criticisms, he produces, in my opinion, lip results as good as if not the best of those achieved by any variation of the Z-plasty. Perhaps because he is a bit closer to the rotation-advancement in the placement of his scars?

### CRONIN

Concerned about the unreliability of getting a good join across the cleft at the mucocutaneous line, Thomas Cronin in 1966 made a slight modification in the Tennison-type lip closure. He lifts his medial transverse incision, CB, 1 mm. above the potential peak of the bow on the cleft side from E to D. On the lateral side again he raises his flap 1 mm. above the edge from E' to D'. Then a vertical cut is made across each mucocutaneous ridge to facilitate the alignment of the vermilion border. In essence, the slightly elevated lateral triangular flap is let in slightly above the mucocutaneous ridge on the medial side in a short straight-line join. Brauer subsequently joined Cronin in this 1 mm. jog.



## POPULARITY OF THE Z

In 1959 Raymond Brauer, after having previously embraced and modified the LeMesurier method, concluded that Tennison's method was superior in unilateral primary clefts for the following reasons:

- 1) It saves the cupid's bow, the medial half of which is sacrificed by LeMesurier's incisions as indicated by the stippling.
- 2) It relieves vertical shortness of the lip on the cleft side in the body of the lip, rather than merely in the lower third.
- 3) The scar falls laterally where it is far less noticeable than is a central scar which distorts the cupid's bow and displaces laterally.

On the bus to the teaching sessions at the American Society of Plastic and Reconstructive Surgeons meeting in Las Vegas in 1972, I challenged Brauer:

"Ray, I think you persist in cutting a Z-plasty in the lower portion of the lip out of some old resentment from my residency days in Houston."

He laughed and said:

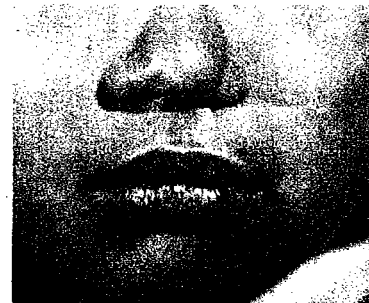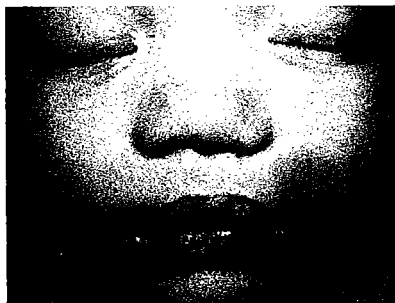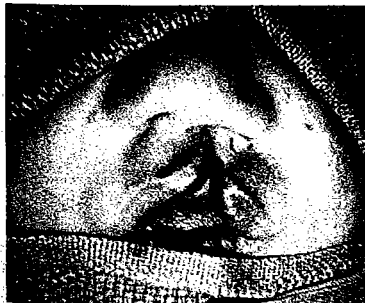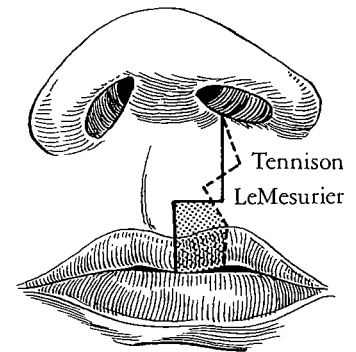
"No, but if you have a contracture at the elbow a Z-plasty placed directly in the antecubital space gives easier release than one higher on the arm."

Easier maybe, but ease is not our most important factor. An entire displaced component, it would seem, should be moved as a *whole* and not be "drawn and quartered."

It has been said that Brauer's lips rank among the best. I asked him to send me examples, preferably complete clefts with long-term follow-ups. Here is an example which shows Brauer's markings on an incomplete cleft, the early result and a later follow-up of the Z.



Raymond Brauer



Another fine example is used to demonstrate an important point. The photo of the original deformity reveals not only a complete cleft but a predictable longer-than-ideal vertical lip length on the normal side. Brauer executed his neat inferior triangular interdigitation without transgressing or affecting the normal side. He achieved good positioning of the bow, but, as could be foretold, the total vertical lip length eventually appears longer than ideal. This is not the fault of the method but the result of matching the cleft to the long normal side.



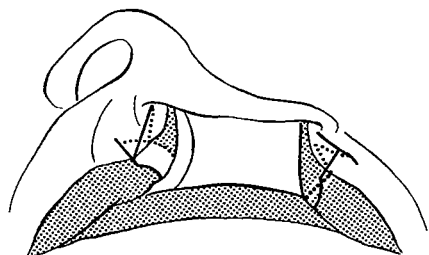
The question arises: Should we shorten the long normal side rather than knock ourselves out lengthening the short cleft side in those rare cases with a predictable long lip future?!

#### CLIFFORD AND POOL



Robert Clifford

In Detroit in 1957, with the aid of a blackboard in a small room on the thirteenth floor of the Henry Ford Hospital Clinic, Drs. Robert Clifford, Pool, Kelly and Kislov hotly debated the pros and cons of the various popular cleft lip techniques. They measured hundreds of infants' lips in the adjacent clinic and sketched and erased thousands of drawings in a constant blackboard battle. Finally, in 1959, young Pool presented their findings to the American Association of Plastic Surgeons in Boston. Included was a probing comparative analysis of the LeMesurier and Tension methods illustrated by a *composite* drawing. He commented on



the tissue used in the triangular [Tension] flap repair [dotted line] and sacrificed in the square [LeMesurier] flap repair [dark line]. Square *versus* triangular flap: the square flap technique sacrifices vermilion and remnant of cupid's bow on the cleft side of the midpoint. Likewise, when the oblique incision is past the midline or through the philtrum, the lip will be made

long and tight. The only tissue sacrificed in triangular flap repair is the skin above this flap. . . . One definite disadvantage in the use of the quadrilateral flap repair is that it is generally planned from the cleft side with a preconceived idea of lip height. When an error is made it is usually in the direction of excess length with concomitant horizontal tightness and sacrifice of the useful normal remnants of cupid's bow, midline dimple and midline tubercle.

Pool recalls now with nostalgia how, during his presentation, six authors of plastic surgery textbooks, with much experience in cleft lip surgery, sat in the front row. Although the previous papers had been vigorously challenged, when he finished and waited in anticipation for discussion, the audience got up, turned around and left the room for intermission without one word. As he says today,

It was rather like a nightmare and I left the room feeling that I had laid a colossal egg.

To add to this blow, only 36 hours later Robert H. Clifford, his chief and friend, died. Actually, their analytic study stands as an important landmark in cleft surgery.

Although more conservative of landmarks and tissue than the square flap, the triangular flap is by no means as simon-pure as Clifford and Pool indicated.

Musgrave in 1964 felt that the Tennison technique is easy to teach, easy to perform and best suited for the severe degree of incomplete cleft lip and for most complete clefts. He suggested:

In the complete unilateral cleft lip, when possible, an attempt is made to plot the triangular flap on the lateral elements of the lip, as long as the markings can be maintained within the lateral nasal crease where the ala joins the lip. When this is not feasible and it appears that the incision would extend too far laterally, the Tennison method is not used and instead a quadrilateral flap is planned.

#### INCREASE IN VERTICAL LENGTH


Surgeons have noted, as with the quadrilateral flap of LeMesurier, that the triangular flap of Tennison also results in increase in

vertical lip length on the cleft side in certain cases. Pool attributed this outcome to a vertically long lateral element. Brauer and Cronin purposely made the lip shorter by one or two millimeters initially to compensate for the subsequent increase in vertical height.

Musgrave with Garrett for Goldwyn's 1972 book, *The Unfavorable Result in Plastic Surgery*, noted:

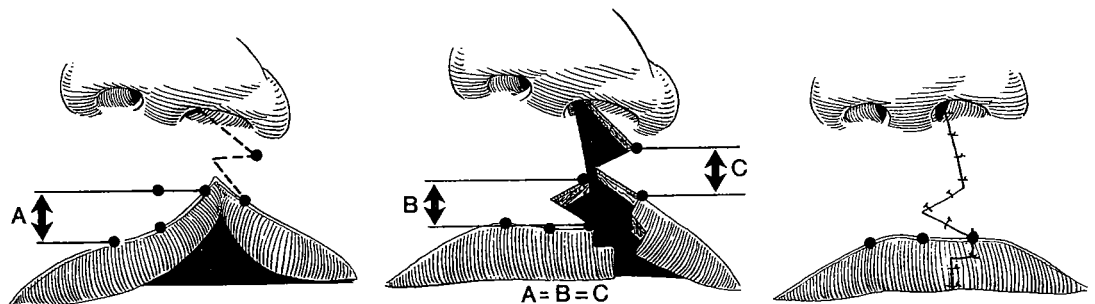
The surgeon who chooses to use one of the lateral flap methods, i.e., either a rectangular or triangular flap introduced just above the vermilion border, should be aware that in the patient with a wide cleft, this rotated tissue which originally was cheek tissue has been turned downward and medially to be inserted into the medial border of the cleft. With time, the lip may well become too long. It behooves the surgeon, therefore, who is considering use of such a flap method (LeMesurier, Wang, Hagerty, Randall, Tennison) to be alert to such potential lengthening and to plan a lip that is approximately 1 mm. on the short side.

#### SIMPLIFYING THE DESIGN



Chandler Sawhney

Chandler Sawhney of Chandigarh, India, considers the increase in vertical lip length to be due to faulty design rather than abnormal growth. He does admit that a small error at time of operation is likely to become more apparent as the lip grows and the scar stretches. In 1972 he proposed a simple, logical way to design and measure the Tennison method. A transverse incision across the philtrum which stops at the midline will drop the cupid's bow into symmetry. Taking the difference in height of the peaks of the bow on the cleft and normal sides after pushing the columella into straight position determines both the amount of drop on the medial side and the width of the triangular flap on the cleft side. Of course, these two are equal to each other.



## CRITICISM BASED ON PRINCIPLE

The Tennison principle and all of its subsequent modifications made one important advancement, the preservation of the cupid's bow and its placement into normal position. This had been accomplished by taking a triangular flap from the cleft side to insert into an inferior releasing incision on the non-cleft side. In fact, this *means* does not justify the *end*; too many proved principles are being ignored.

1. Like the Mirault modifications this method also bases its logic on the false supposition that the actual defect in the cleft is in the lower one-third of the lip. This, of course, is not the case.

2. The main triangular flap is taken from the deficient cleft side, and in principle it is unwise to borrow from Peter to pay Paul when Peter can ill afford it.

3. There is already missing tissue so that further discard of tissue is unsound in principle. It is particularly extravagant in incomplete clefts with the Tennison approach.

4. Nasal correction by this approach is not simultaneous but requires a separate action. The straight-line scar of the upper portion of the closure runs directly into the floor of the nose, a telltale sign of cleft lip. The short-sided columella remains short, no nostril sill is created and, in order to move the alar base far enough medially, more excision of tissue is necessary.

5. Probably the most important flaw in this approach is the Z-plasty in the lower portion of the lip. It crisscrosses Langer's lines, violating the potential vertical philtrum column and disrupting the philtrum dimple. Even when the scars heal superbly, the result is unnatural. When the scars are poor, the effect is unacceptable. Photographs of results in which flat lighting has wiped out the scars completely are misleading.

Of the cases that come through our clinic, those that have been treated according to the Tennison design often are reasonably good. The unnatural zigzag of the scar is the only aspect

that is universally offensive. Of course, when the surgery has not been carefully executed, the secondary correction can be exceedingly troublesome.

Or, as paraphrased by Professor R. L. Last:

Seven times seven turn your knife in your hand  
Ere you cut the skin of a fellow man.  
Seven times seven and go out to dine  
Ere you cut across a Langer's line.