

7. Increasing Vertical Length of Cleft Edges

VON GRAEFE

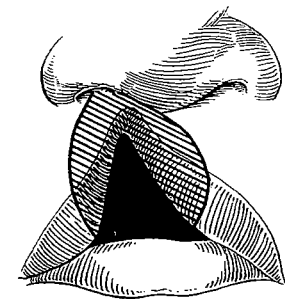
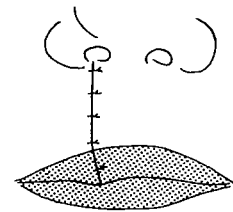
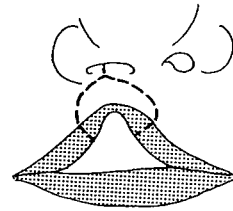
THE next step in the logical progress of cleft lip surgery involved a more radical paring of the borders to increase the vertical length of the cleft edges. Carl Ferdinand von Graefe, Professor of Surgery at the University of Berlin, about 1816 advocated curved excisions in paring of the cleft edges in lip closure.

HUSSON


In 1836 Husson, a British surgeon, described curved incisions which actually excised much lip tissue, but with approximation of the curved edges there occurred not only a lengthening of the edges to prevent eventual shortening by contracture but also a relative fullness or pout at the free border.

NÉLATON

Auguste Nélaton, a French surgeon more famous for orthopedic and urological procedures, in 1859 devised a simple lip-lengthening operation which was advocated in incomplete cases when the cleft did not extend into the nostril. A transverse inverted "V" incision was made above the fissure, and the notch was then pulled down, leaving a diamond-shaped wound. Several sutures closed this wound in the vertical direction with specific lengthening at the area of the cleft but not without skin distortion and with far from an ideal scar.



Auguste Nélaton



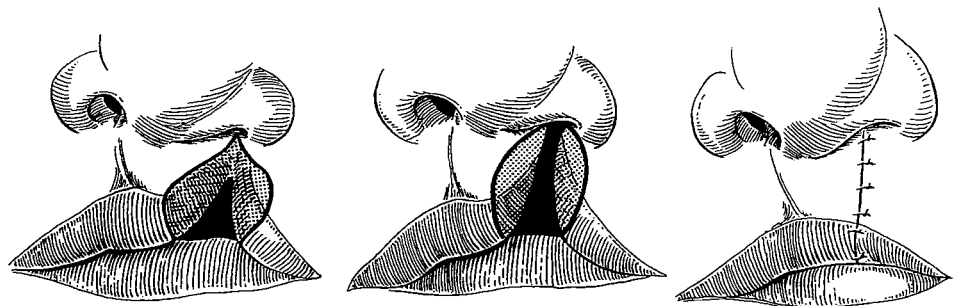
ROSE



William Rose of London, 1847–1910, came from a long line of surgeons and himself became an expert operator with “an exquisite sense of touch in manual skills.” He was a drummer, deer hunter (he had antlers everywhere) and the first-rate whip often seen driving his four-in-hand. He was a good teller of tales with “a laughter that could be heard in the next street.” Quite early he attracted the attention of Sir William Fergusson, who took Rose with him into private practice and obtained for him an appointment on the staff of King’s College Hospital. For a surgeon who knew how instruments should be used, it was a pleasure to watch Rose operating:

He had large and apparently clumsy fingers which were actually extraordinarily dextrous. To see him using the finest of gut in the finest curved needle in a hare-lip operation was to feel that one had met a master surgeon. He came to the Hospital at tea or dinner time to see for himself how the cleft patients fared.

In 1879 Rose advocated a design similar to that of Husson with curved incisions mutually concave from nostril to vermilion and through the vermilion at a 60-degree angle. This provided a line of union of such length that contracture of the scar would not make a notch in the red margin. Rose was responsible for popularizing this approach some 60 years after von Graefe and at least 40 years after Husson first described the principle.



THOMPSON

James E. Thompson, 1863–1927, originally from Northwick, England, subsequently became Professor of Surgery at the University of Texas in Galveston. In 1912 he described an angled paring to lengthen the cleft edges and delineated with feeling and a sketch the lovely curves of the normal lip:

The mucous membrane of the upper lip is separated from the skin by a sharply defined line which is carried from one angle of the mouth to the other in a beautiful curve known as the cupid's bow. The convexity of the bow points upward toward the nostrils, but the middle of the bow takes a sharp downward turn. . . . Resting on the middle of the cupid's bow we have a pear-shaped depression which forms the center of the upper lip.

After this poetic discourse, he acknowledged reality:

Even the most sanguine operator never dreams of reproducing a Cupid's bow.

He admitted that

the completed lip is often a wretched imitation of Nature's masterpiece.

He emphasized that

the newly formed lip must not be too short but must be lengthened so that it will more than cover the gums.

He designed his paring procedure generally in the shape of a diamond excision and advocated accurate marks with a compass so that the angled excisions on each side would make it match its opposite. When the vermilion thickness varied, the angle of the mucosal incisions was varied to balance the vermilion closure. Thompson also noted the importance of medial placement of the alar base.

These are Thompson's own 1912 words in defense of the originality of his procedure:

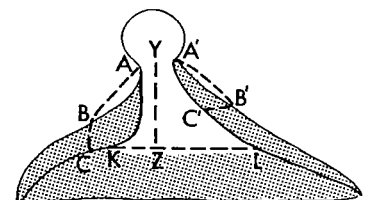
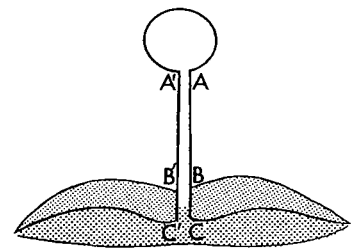
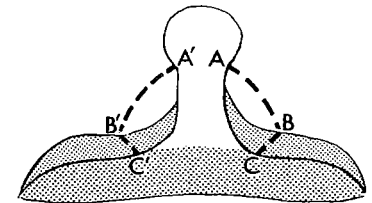
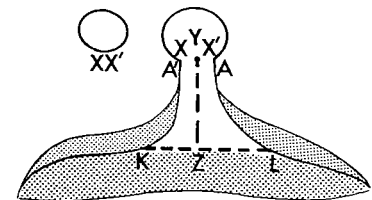
The flaps are pared according to the method of Rose, but the conception and actual performance of the operation differ so radically from his that the operations are totally unlike.



James Thompson



!!



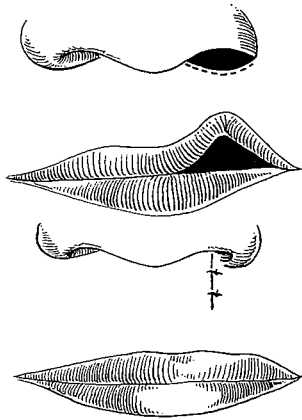
Ironically, progress has narrowed this gap, and history groups their contributions into the Rose-Thompson principle.



Charles Mayo

A M A Y O

Charles H. Mayo, one of the famous Rochester, Minnesota, surgeons, was said to have a “sixth sense”—mechanical versatility. He could master a difficult situation with exceptional speed, and, since he enjoyed variety, his operating list might include excision of a knee joint, sectioning of the gasserian ganglion, a hysterectomy and a cleft lip. He developed a method for lip clefts which was respected enough to be included by Binnie in his 1916 book. It was designed for certain incomplete notched lip clefts in which the ala of the nose was flared and the nostril wide. Mayo advocated relieving the tension thoroughly by separating the ala from its deep attachments. Then, after denudation at the floor of the nostril and by pulling the lip downward and introducing sutures, he converted the horizontal nasal floor wound into a vertical one. This resulted in obliteration of the lip notch along with correction of the deformed position of the ala. The economy of correcting two deformities with one maneuver has appeal.

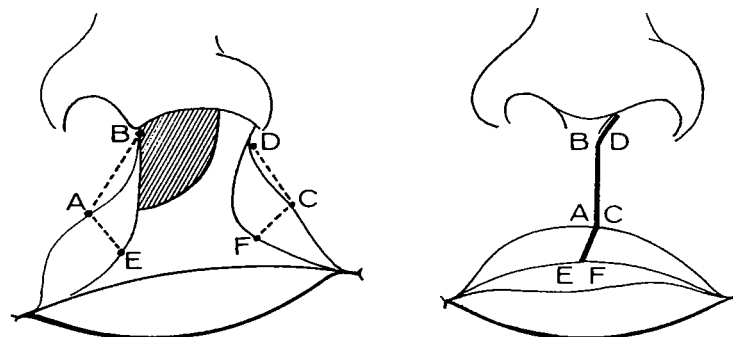


L A D D

The tall and distinguished William E. Ladd, pioneer in pediatric surgery at Boston Children’s Hospital, corrected every deformity occurring in a baby from cleft lip to imperforate anus. In 1915 he developed a cleft lip procedure which increased the vertical length of the cleft edges by straight paring carried further laterally and cutting through the vermilion at a 90-degree angle.



William Ladd



Staige Davis approved this method in 1919, but actually it seems in principle to be a step backward because lengthening by extensive lateral parings tightens the lip from side to side, particularly at the free border, and destroys any eversion or natural pouting.

In 1945 I was one of Dr. Ladd's last group of surgical interns. I remember that he was more concerned with tracheo-esophageal fistulae at that time and seldom operated on a cleft lip. He acknowledged that a plastic surgeon specializing in this problem should produce better results. By this time cleft lip surgery had become a specialty beyond the scope of the general surgeon; fortunately, many of the general surgeons were wise enough to accept this fact.

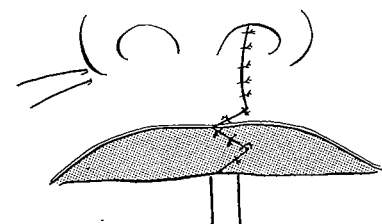
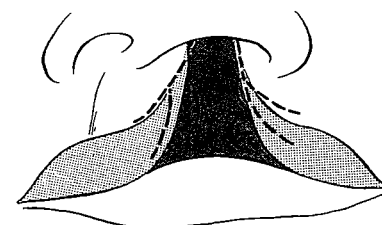
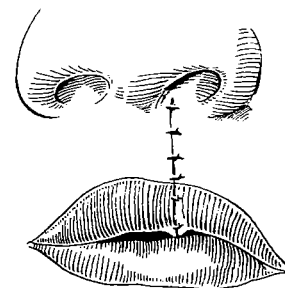
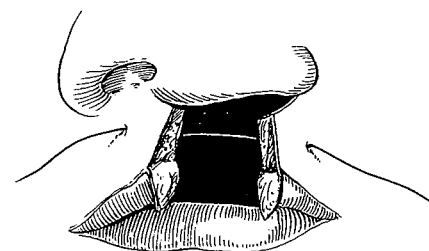
BROWN

Because of their region of interest, the oral surgeons compose another group of specialists who have been active in cleft lip and palate work and in the early days also made contributions. Even today they often concern themselves with the problem. G. V. I. Brown, D.D.S. and M.D., at Milwaukee's Children's Free Hospital in 1918 described straight turning of mucosal flaps from the cleft edges to form an asymmetrical tubercle similar to the plan of Ladd and with similar discrepancies.

The more popular Rose and Thompson methods paradoxically became known as the *conservative* surgical approach to cleft lip. It now has become apparent that this approach was indeed *more radical* than realized as it inadvertently destroyed natural landmarks. Yet other surgeons made their name embracing the same principle, and a few continue to do so even into the second half of the twentieth century.

VEAU

In 1925 Veau published his first cleft lip method which, although primarily a straight-line closure, had aspects similar to those of Mirault's final design. Veau subsequently abandoned this early plan as he gradually changed his technique.

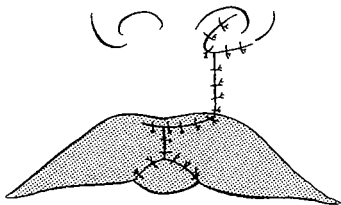
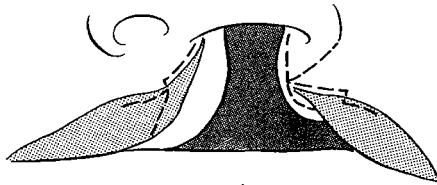




Victor Veau


Victor Veau, a general surgeon of Paris, was one of the great cleft surgeons of all time. He was a tall, gentle man with a small goatee and an aura of *bonhomie*. Through his voluminous cases, as seen in his *Bec-de-Lièvre* published in 1938, he not only had extensive experience with many designs but a remarkable influence on cleft surgery throughout a great part of Europe and Britain.

Sophisticated straight line



Veau's final unilateral cleft lip design was a variation of lengthening the edges of the cleft by paring. On the non-cleft side he pared the mucosa just distal to the mucocutaneous junction line far enough to achieve a length equal to the normal. On the cleft side he pared laterally just proximal to the mucocutaneous junction line an equal distance, freeing a mucosal flap for overlapping the free border on the non-cleft element. This aspect of his approach, strangely enough, is reminiscent of a technique originally attributed to Mirault as his second method but is not the method now recognized as Mirault's procedure. Veau also freed the alar base and turned it across the cleft just inside the entrance to the nostril, a trick used by surgeons before and after him.

Principles of cleft closure for which Veau also was renowned involved his vigorous approximation of the muscle elements with wire *suture musculaire* and his closure of the anterior palate simultaneously with lip surgery. He rarely was able to achieve a symmetrical cupid's bow and, invariably, ended up with severe asymmetry of the nose, the disadvantage of a straight-line vertical scar and often subsequent retrusion of the maxilla. Yet, in its simplicity and several aspects of surgical soundness, the Veau approach still enjoys popularity today in various areas throughout the world—and certainly wherever the French have had influence and their lovely language is understood, even unto Indochina.

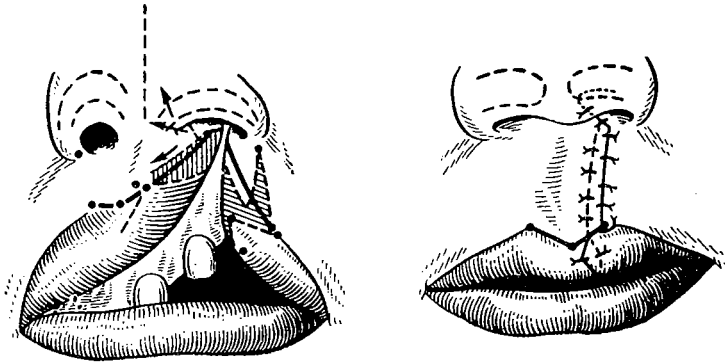


Alexander Limberg

LIMBERG

In his gray and silver 1963 handbook, translated by resident Tony Wolf, Alexander A. Limberg of Leningrad, a gentle and refined

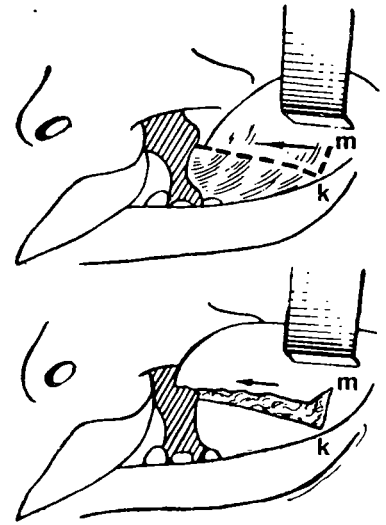
senior surgeon of Russia, incorporated the modern touches of primary nasal correction and preservation of the cupid's bow into the old Veau straight-line design.



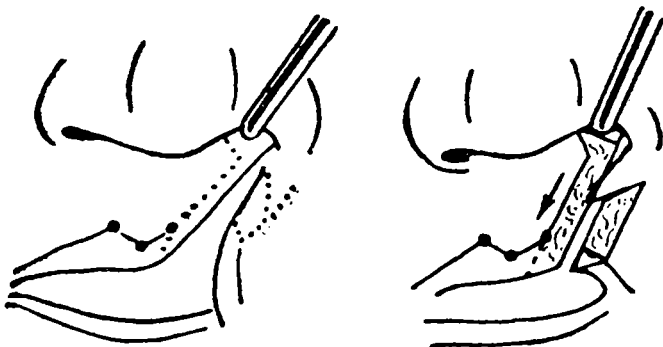
Important in his complete cleft closure is the release in the upper buccal sulcus which he refers to as a right-angled "poker incision." The soft tissue of the lateral lip element is freed from the bone and advanced without tension. As he explained:

Angle K closes from 90° to 0 , while angle M opens from 0 to 180° and due to the elasticity of the mucous membrane the advancement occurs without conical distortion.

On the non-cleft side, his "poker incision" starts at the high point of the vermilion border, continues along the edge to the nasal vestibule and at the lateral surface of the nasal septum cuts at a right angle and opens 45 degrees. A triangular flap with a superior base taken from the cleft edge of the lateral lip element is transposed across the cleft into this medial dart. A vermilion flap from the cleft side is also inserted into a releasing incision in the vermilion on the non-cleft side in another maneuver similar to that of Veau but credited by Limberg "after Miro, 1844."



"poker" = "back-cut"





Thomas Kilner

God help
one who
cannot!

KILNER

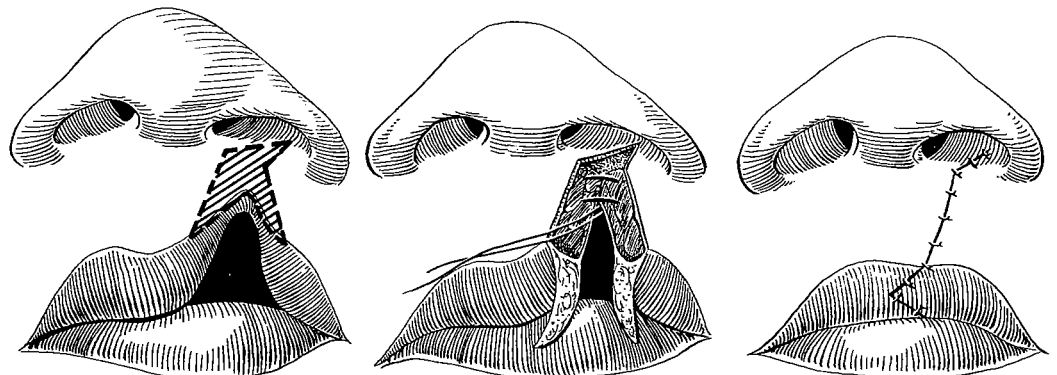
The modern British champion of the *conservatives* was Nuffield Professor Thomas Pomfret Kilner of Oxford, trained in plastic surgery by Gillies. He was short, rotund and genial enough to remind one of a Toby jug, but his appearance was deceptive for he could be quite irascible. Son of a Manchester schoolmaster, he always retained some of the teacher characteristics, being a strict disciplinarian with an organized, tidy mind insisting that everything be preset and absolutely correct. As noted by Dick Battle, a student of and assistant to Kilner for years, his inflexibility was reflected in one of his favorite dictums:

God protect me from the surgeon who changes his plan in the middle of an operation.

His cleft lip method was a careful straight-line approximation of the separated parts with the removal of the minimum of tissue, paying particular attention to muscle union. Actually, the method used by Kilner was a refined combination of Rose, Thompson and Veau, paring to lengthen and then to approximate. What he wrote in 1937 he stuck to the rest of his life.

In my opinion, it is wiser to underdo things at the early operation than to sacrifice too much tissue in a desire to produce a perfect cosmetic result. The essential principle in primary lip cleft repair is suture in layers and adequate apposition of the muscle layer is the keynote of success. When the lip has functioned and developed for a few years it is easy to add any finishing touches which are required. The ease with which this is done varies according to the simplicity of design of the initial repair. All types of flap operation render it more difficult.

His design of a unilateral pre-alveolar cleft with paring and mattress suturing had the appeal of simplicity.



Kilner was a pure irreversible conservative. When baited about the merits of a flap method he would glare sternly over the top of his little half-spectacles and insist:

I am unalterably opposed to chopping up the lip with flaps!

Of this straight-line closure David Davies of Cape Town said in 1971:

I was privileged to assist the late Pomfret Kilner with a lip repair on his visit to South Africa in 1958. Meticulous and loving workmanship produced a near perfect lip from a straight line repair. One cannot ignore such a display of virtuosity but as a corollary one cannot accept such techniques as the norm. Straight line repairs have the advantages of simplicity, ease and speed but the long term results are not satisfactory. Kilner pointed out that the operation is so sparing of tissue it lends itself to secondary correction. However, no secondary correction is really as easy as the primary repair and one should aim for a normal shape and form at the initial operation.

but the landmarks are gone

F A R A

Miroslav Fara of Charles University, Prague, obsessed with the worthy desire to get the orbicularis oris muscle fibers joined end to end across the cleft, explained to me in 1972,

In the case of unilateral clefts I prefer now to operate by methods using straight or almost straight incisions and sutures because I am able more easily

- 1) to fold down the muscles for suture end to end,
- 2) to shape the ala nasi by means of an auxiliary skin flap, going from the lateral to the medial side in the threshold of the nostril, and
- 3) to perform the final corrections on the lip.

This is the Kilner philosophy but with more sophistication in the positioning of the muscles and a Trauner adjunct for the nose.

P E E T

The genial Eric Peet had served as a plastic surgeon in India during World War II and, at the same time, become a tiger



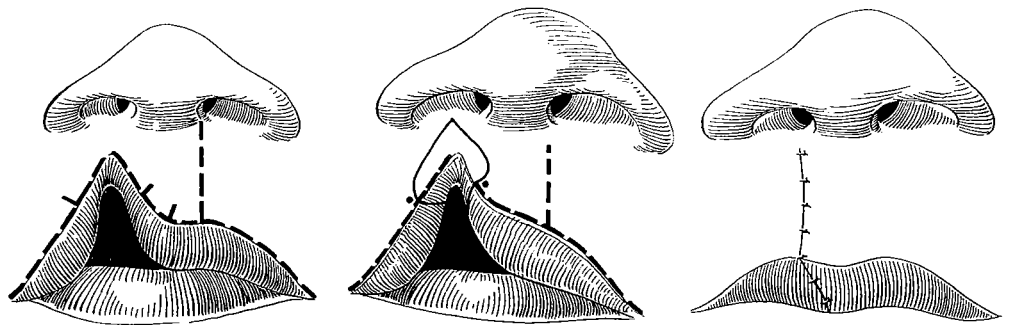


Eric Peet

hunter. Fortunately, he lived to tell such tales as that of the day he was thrown from an elephant into tall grass with a wounded tiger. In the fall he lost his rifle, but the faithful elephant boy drove the elephant back into the tall grass to bait the tiger's second attack. This gave Peet the seconds he needed to retrieve his gun, retreat and wait for a pickup by the elephant before the final return to finish off the tiger. After incidents like this it is easy to understand why Peet was content to become one of the archconservatives of Oxford.

By now, however, the importance of preserving the cupid's bow had become established, so his markings and excisions took these landmarks into account. As he wrote for Rob and Smith in a book which was published after his death:

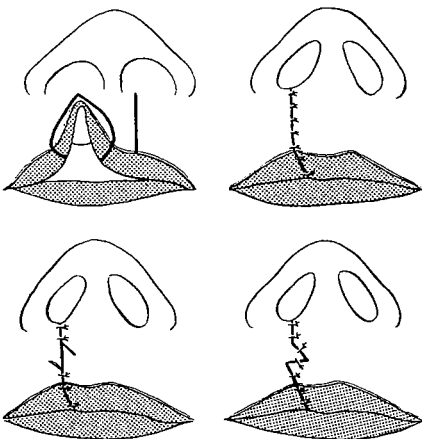
The medial incision is a curved one, equal in length to the normal side of the philtrum. The angle between the lower end of this skin incision and the skin vermilion line is designed to be the same as that between the philtral ridge and skin vermilion line of the uncleft side, in an attempt to produce a symmetrical Cupid's bow. The skin incision on the lateral side of the cleft will usually be almost a straight one, equal in length to the normal side of the philtrum.



A secondary Z-plasty

Yet Peet's sporting streak got the best of him eventually for he partially broke from the purist stand and prescribed a Z-plasty in the middle of a straight-line closure in cases in which the vertical height of the lip was unduly short on the cleft side. He mentioned that his Z-plasty produced a natural eversion of the lip.

For Peet, this divergence from the straight line was venturing into tiger country with Kilner, who considered such action only that of a "renegade."



At first thought, one may be lulled into Peet's logic. As a conservative turned flapper, he had a point:

Z-plasties are the accepted approach to straight line contractures.

Yet when used in this fashion in cleft lip, two plastic surgery principles are violated. First, the use of generous curved excisions for paring the cleft edges causes much valuable tissue to be discarded, tissue that could well be used in the Z-plasty. Second, this is a Z-plasty that violates the natural lines as well as the philtrum of the lip.

MASTERS

A variation of the straight-line closure was described in 1954 by Frank Masters with Georgiade, Horton and Pickrell at Duke University. They advocated simple interlocking "Z's" with 90-degree angles in the repair of incomplete clefts. This approach did not lengthen the cleft edges except by paring but did interrupt the straight-line closure. It might just get by in very minor clefts but, as Masters says today, it is seldom used except in certain secondary cases with a thickened straight-line scar.

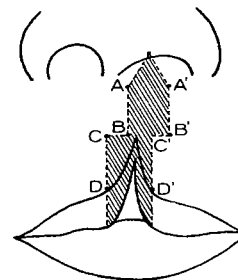
BARTELS

Roger Bartels with O'Malley, Douglas and Wilson in Orlando, Florida, in 1970 modified the interlocking for a wider variety of cases by varying the angles in the lateral incision. As Bartels explained in 1972, he rarely sees primary clefts, but this method has been useful occasionally in secondary cases as a slight amount of edge lengthening can be achieved in addition to a breaking of the straight line of closure. Yet it would be the latest Disney World fantasy to claim that this more primitive principle would satisfy modern standards in most clefts.

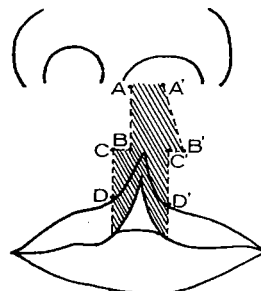
Both this and the Masters design call for much tissue discard, an unnatural scar line and no provision for positioning or salvaging natural landmarks.



Frank Masters



Roger Bartels



In summary, it can be said of the so-called conservative approach that paring to lengthen vertical height produces a fairly good-looking lip, depending on the craftsmanship of the surgeon, and reasonable function inasmuch as the muscles have been united. Yet, since both tissue and important landmarks have been discarded, the results are lacking both in substance and in natural detail, and these, alas, are then lost forever.