

2. *Anatomy in Multiple Dimensions*

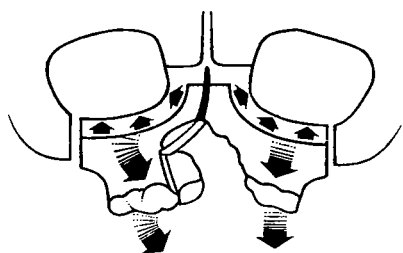
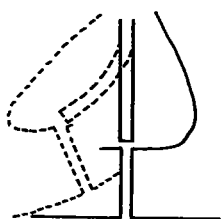
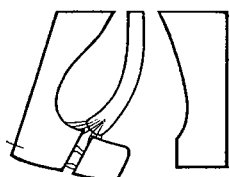
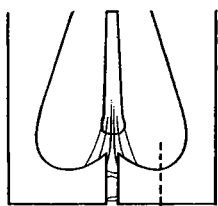
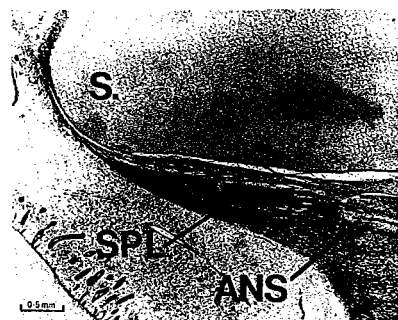
ALL anatomy and most surgical textbooks laboriously describe again and again the normal anatomy of the face. Most of us find that *anatomy unrelated to surgery gets lost in its Latin*. Yet when pertinent to the surgery, it becomes *vital* and exciting and will be called upon constantly throughout this book to influence the design of surgery.

Here in its own unrelated section, it will be reviewed in its multiple dimensions but in "bikini" briefness, just enough to cover the essentials but not so much as to put you to sleep. Certainly, a comparison of the anatomy of the cleft deformity and that of the normal in reference to muscles, blood supply and specific labial and nasal peculiarities merits our attention, as these elements should influence directly any plan of cleft lip surgery.

Remember, the anatomy of the cleft deformity reflects not only the varying extent of embryological failure but the ultimate result of growth and development in the absence of intact dynamic labial and palatal musculature as well as the lack of structural support of the bony arch and partition between the oral and nasal cavities. In fact, because of a unilateral cleft, growth and development exaggerate the asymmetry and with it the difficulty of correction.

THE EFFECT OF THE SEPTUM ON THE MAXILLAE

Ralph A. Latham, trained at Queen's University, Belfast, and inspired in clefts by Burston in Liverpool, is now Associate



Professor of Oral Biology at the University of North Carolina School of Dentistry, Chapel Hill. In 1969, in *Cleft Palate Journal*, he proposed the hypothesis that the nasal septum is a key factor in the height and anteroposterior dimensions of the face and presented diagrams and microscopic studies for substantiation. He showed by photomicrograph a sagittal section from a 17-week fetus demonstrating the septopremaxillary ligament (SPL) in relation to the nasal septum (S) and the anterior nasal spine (ANS). Then at Georgiade's 1973 Foundation Cleft Symposium at Duke University, he repropoed that in the embryonic period the nasal septum is the dominant growth structure and in the normal there is equal septal drag on both maxilla as diagramed. When a unilateral cleft occurs, one side is set free, but the forward drag is still present on the other side through the intact septopremaxillary ligament effecting deviation in growth. The broken line sketched by Latham shows that a bent septum must incur a deficiency in height of the premaxillary region. Then, in the latter half of the prenatal period and after birth when the maxillae begin to exert their own growth, the bent septum acts as a bridle impeding downward progress of one maxilla. Thus, Latham pins the blame on the septum for premaxillary rotation, first downward and later upward, pointing to the tethering restraint of the bent septum on both downward and forward growth of one maxilla. He describes the final stage as: "It is much like the way a fish pulling on the line bends the fishing rod."

ANATOMY OF THE UNILATERAL CLEFT LIP NOSE

The typical nasal deformity associated with congenital unilateral cleft of the lip presents both a discrepancy and a displacement of parts which persists without great improvement during growth. The distortion, being confined to the cleft side only, is emphasized by the constant comparison with the normal opposite side.

1. *Platform.* When the actual platform of the nose is cleft, the projection and outward rotation of the premaxilla and the

retroposition of the lateral maxillary element certainly guarantee that the nose will sit *askew*. Even when there is no bony cleft, the discrepancies in maxillary contour are responsible for some degree of nasal asymmetry. This is an architectural fact, for any structure, with one of its key legs shortened or pulled out from under it, must tilt!

2. *Septum*. With the medial maxillary element forward and the lateral maxillary element backward the effect is reflected in the twist and slant of the septum. The anterior portion of the septum tilts over the cleft like a lean-to with its inferior edge dislocated out of the vomerine groove and presenting with the nasal spine in the floor of the normal nostril. This dislocation is responsible for a twist to the nasal tip.

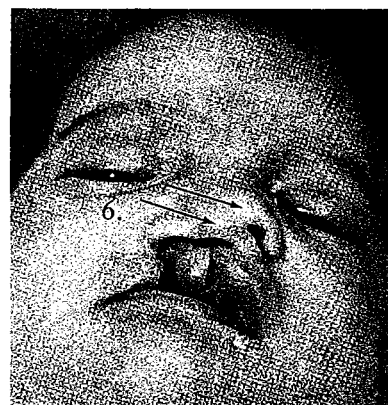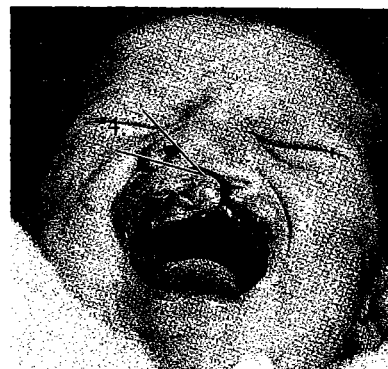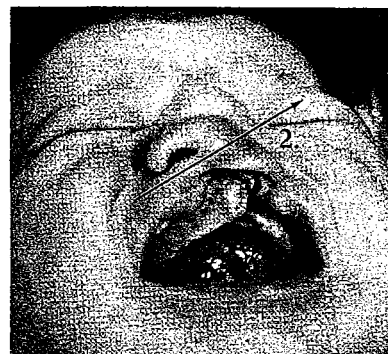
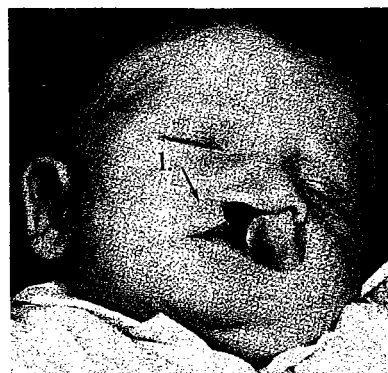3. *Nasal bones*. The asymmetry of the maxilla and premaxilla and the deviation of the septum assure some distortion of the nasal bones.

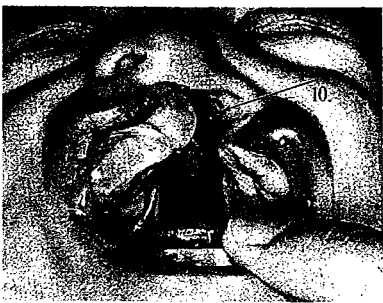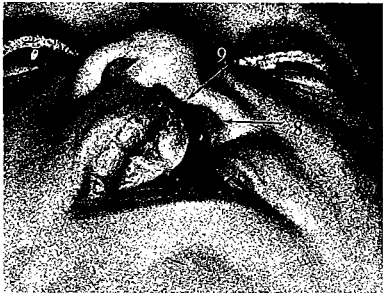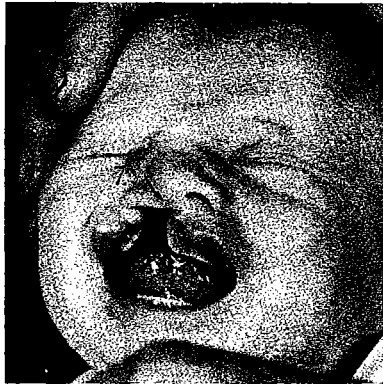4. *Columella*. The columella is deflected by the deviation of the septum behind it. It also suffers a unilateral shortness in vertical height which can vary from three-fourths to two-thirds to even one-half that of the normal side.

5. *Nasal floor*. In complete clefts the nasal floor is cleft not only in skin and muscle but in bone, and the position of the maxillary elements can vary from overlap to abutment to gaps of millimeters or centimeters. In incomplete clefts there can be a variation from a thin skin bridge across a very wide nasal floor to a nasal floor within a millimeter of the normal width. I have never seen one the exact size of or smaller than the normal side.

6. *Lower lateral alar cartilage*. The alar cartilage on the non-cleft side should be normal but often seems to be overdeveloped when compared to the attenuated cartilage on the cleft side. The deformed alar cartilage arching the cleft is dislodged from its rightful balanced position beside its mate in the dome of the tip. Rather, its medial crus is lower in the columella, with the junction curve of the medial and lateral crus separated from the opposite alar cartilage and resting below it, being flattened, spread and stretched across the cleft at an obtuse angle.

7. *Alar crease*. The alar crease on the normal side runs parallel



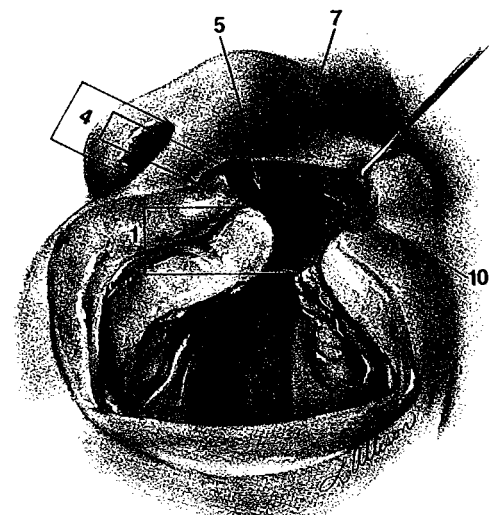
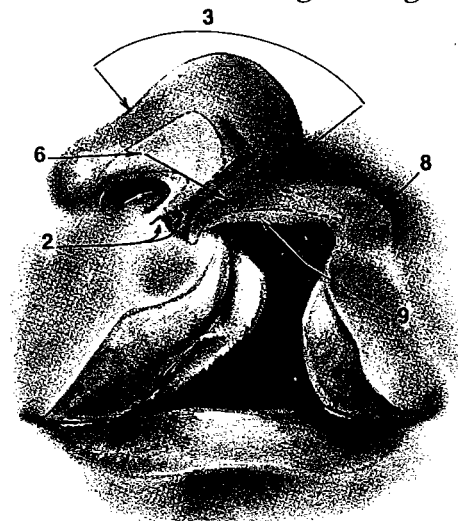


to the upper border of the lower lateral cartilage and smooths out as it approaches the bulge of the alar cartilage in the dome of the nasal tip. On the cleft side the alar crease has no alar cartilage bulge to give way to and consequently, unopposed by this structure, continues obliquely across the tip just lateral to the join of the columella and through the rim of the ala. This abnormal extension of the alar crease across the tip on the cleft side produces a disjointed effect to the tip and often is responsible for an actual kink in the alar margin itself.

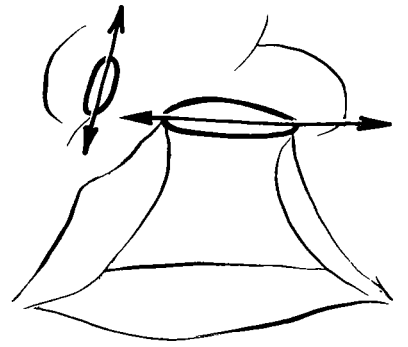
8. *Alar base.* The alar base is invariably rotated outwardly in a flare. It can be wider in bulk than normal or grooved, everted or misformed in various ways to complicate the correction.

9. *Alar rim.* Invariably there is a skin curtain without cartilage which droops over the alar rim like a web further reducing the apparent length of the columella on the cleft side.

10. *Vestibular lining.* The lining of the nasal vestibule seems to be stretched over a greater area than on the normal side with actual eversion of the lining in the alar base region. Yet there is a paradoxical discrepancy in a shortness of lining along the axis from its lateral attachment to the pyriform opening to its join with the septum at the tip. A pull on the nasal tip will cause a band in the lining to rise like a web arching obliquely across the lateral vestibular wall. Gillies and I wrote that the bridling effect of the tissue shortage on the cleft side was responsible for dragging one entire alar cartilage from its normal riding position with its opposite fellow on the tip crest of the septum. In fact, this shortness in the vestibular lining inside coincides with the abnormal extension of the alar crease over the dorsum on the outside and may be partly responsible for the excessive grooving.



The total effect of these 10 unilateral nasal discrepancies produces a nose with the nostril aperture on the cleft side positioned along a *horizontal* axis, whereas the normal nostril aperture takes a *vertical* direction. This is accompanied by a flat nasal tip on the cleft side, along with a webbed nostril arch and a flaring ala which in the adult may be responsible for an increase of as much as one-half inch in total nasal length on the deformed side. In fact, as Gillies and I wrote in 1953 (published in 1957),

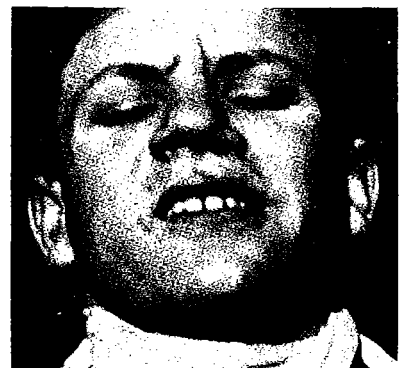

If the patient is approached from the left one may be presented with a prospective Hollywood profile, from the right a Fagan caricature.

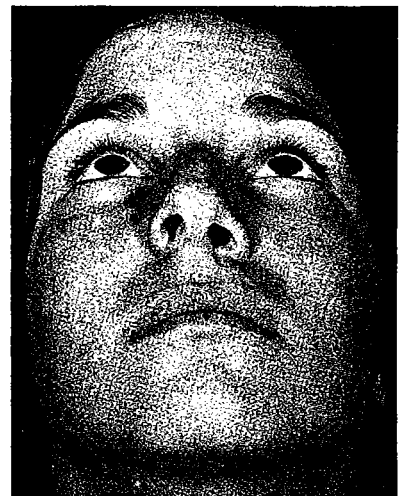
half
a
hook

The appearance is truly bizarre, eye-catching and pathognomonic of this congenital anomaly.

It would seem that the presence of a cleft in the nasal floor associated with generalized spreading, a cleft in the lip muscle allowing unopposed dragging of the nasal spine to one side and the alar base to the other and the inequality of the maxillary platform ensuring an asymmetrical nasal tilt could account for all the characteristics of the unilateral cleft lip nose. Yet minor and even moderate degrees of this same deformity can occur in the absence of any lip cleft at all. In fact, here is a somewhat faded photograph I took in the Lord Mayor Treloar Hospital courtyard at Alton in 1948 of one of Kilner's cases which revealed a cleft lip type of nasal deformity with no history of cleft lip except a slight congenital scar. At the time, this boy caused me much concern as he *nullified* the myth that the associated nasal deformity is directly dependent upon the actual cleft in the lip.



This microform is more common than is generally realized. Besides the English boy just mentioned, the American girl shown here, and even a super movie star who has mumbled his way to more than one Oscar, show a first-degree nasal asymmetry which, if not traumatic, could be congenital. Then there is the international array of published cases by R. Brown, Stenstrom and Thilander, Tulenko, Boo-Chai and Tange and Kozin.



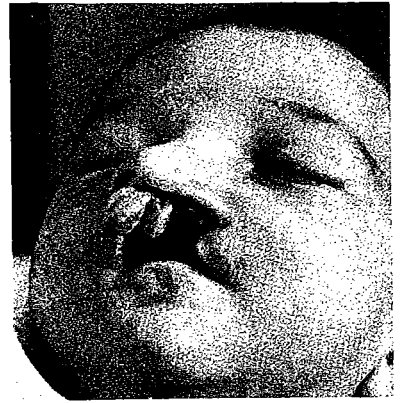After H. Pashayan and F. C. Fraser wrote a paper entitled

"Nostril Asymmetry Not a Microform of Cleft Lip," Maria Tolarova of the Czechoslovak Academy of Sciences, Prague, challenged their stand, reporting that nostril asymmetry occurred frequently in the first-degree relatives of patients with clefts. That the excess of nostril asymmetries in her study was greatest in the relatives of patients with isolated cleft palate, hardly a microform embryologically, is puzzling. Yet Tolarova held her ground, noting that nostril asymmetry as a microform was accompanied by associated deformities such as: underlying bone deficiency or prenatal scar with vermilion deformity, alveolar ridge discrepancy at the lateral incisor, malpositioned teeth in this area, cleft uvula or osseous cleft or even bent alveolar arch in the lateral incisor region. At least all these examples of nostril asymmetry confirm that first there must be an interruption in the natural nasal development, probably associated with inadequate mesoderm migration in the nasal area.

To Stark's question, "Is the nasal deformity due to displacement of the cleft half as the alar base sinks into the crevasse, or is it due to an inherent tissue deficiency upon the side of the malformation?" there have been several answers. Huffman and Lierle blamed the malposition of the cleft half, and Stenstrom and Oberg pulled on cadavers to reproduce the deformity. Finally, Richard Stark and Joshua Kaplan turned to measurements of ectodermal volume on the two sides of the primitive nose in embryos with unilateral clefts and found a *relative deficiency on the cleft side*. In a 24.5 mm. embryo the ectodermal ratio of the normal versus the cleft side was 6.1 to 5.4 sq. cm. or a cleft deficiency of 7 sq. mm. In a 36 mm. embryo the ratio was 23.4 to 20.2 or a cleft deficiency of 32 sq. mm. In a 48 mm. embryo the ratio was 18.2 to 14.8 or a deficiency of 34 sq. mm. This last and largest (48 mm.) embryo had a smaller nasal ectodermal volume than the 36 mm. one, confirming the obvious fact that some individuals are destined to have larger noses than others.

So, the nasal deformity is probably the result of a combination of factors. Once the normal embryonic sequence of nasal events has been upset, all the other anatomical vectors act to exaggerate the distortion. In spite of the odd exception, there does exist

a vague correlation between the extent of the lip cleft and the degree of nasal distortion. The nose in minor lip clefts, although occasionally moderately deformed, usually has only minimal distortion, whereas in complete clefts the nasal deformity is consistently severe and often horrendous.



ANATOMY OF THE UNILATERAL CLEFT LIP

The upper lip, attached above to the nose, blending laterally into the cheek and curving into the lower lip at the commissures, is formed of muscles and glands covered in front with skin and lined behind with mucous membrane. These layers are tightly adherent to the muscles and are sealed along the free margin with a vermilion border which is unique in man. Brescia of Loyola University described the red of the lip vividly in *Cleft Lip and Palate*, by Grabb, Rosenstein and Bzoch:

In this transitional zone the epithelium is thin and not keratinized; also the connective tissue papillae are numerous, densely arranged, slender, and extend close to the surface epithelial cell layers. The abundance of eleidin in the epithelial cell layers, which increases translucency, and the numerous rich capillaries of the papillae, create the red color of this area.

Burkitt and Lightoller explained the development of this aspect of the human lip:

When lips ceased to be prehensile organs and were being used in a modified way for speech, the marginal portion became weaker and was dragged upwards and forwards by the more powerful m. quadratus superior and downward and forward by the m. quadratus inferior and the platysma. Originally this action exposed some of the mucous membrane of the mouth, which, in course of time, became modified to form the present red lip area.

MUSCLES

The orbicularis oris muscle around the mouth with its sphincter-like ability to contract and relax has influential muscle

associates that act as happy elevators and sad depressors. These oral muscles, which are involved in normal labial and nasal action, are divided into two groups, both supplied by the facial nerve. Sir Arthur Keith in 1923 noted that muscles supplied by the facial nerve are peculiar in that many mental states are reflected in them, and their development goes hand in hand with the development of the brain:

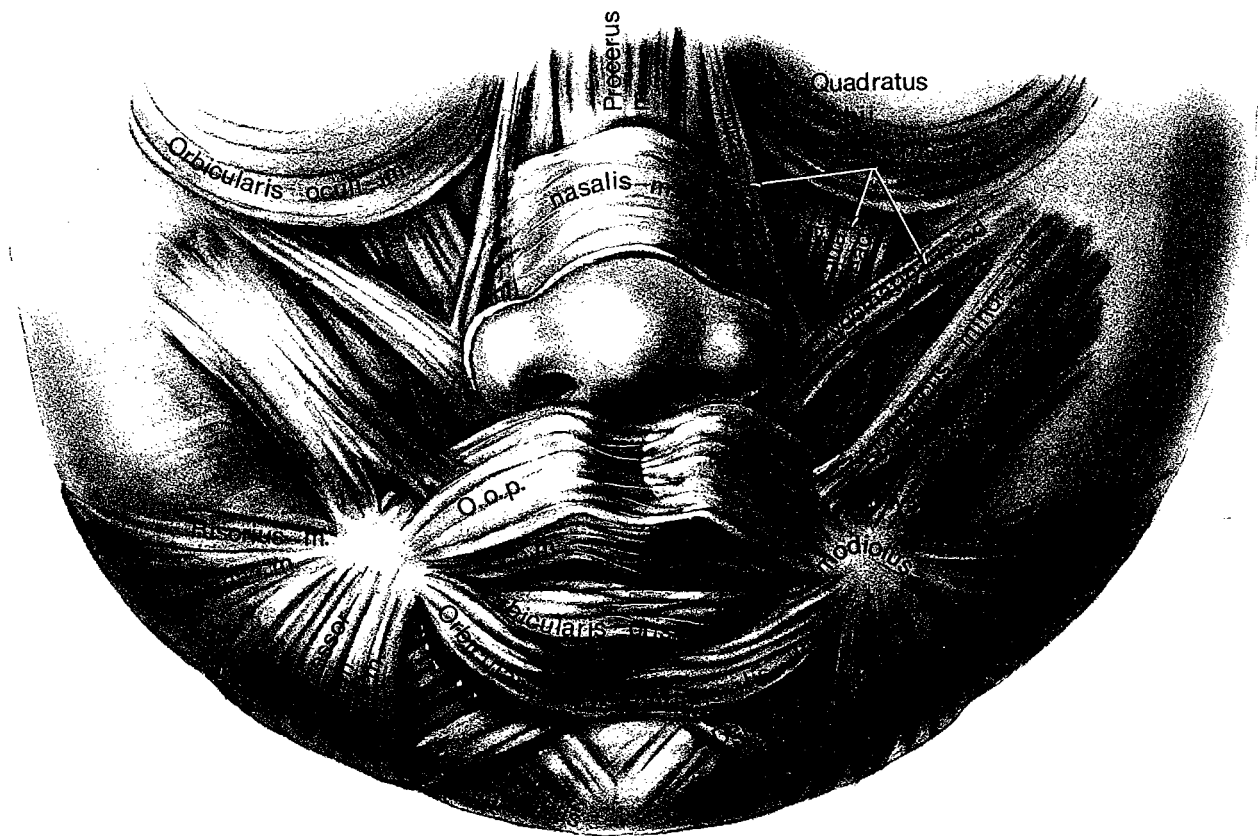
The more highly developed the brain of any primate, the more highly specialized are its facial muscles.

As we go up the scale of development of the mammalia, we find that the muscles about the mouth and in the lips become greatly specialized and are finer and more delicate in texture. For instance, in his study of the facial musculature of the Australian aborigine, Lightoller found muscles that were much thicker and more powerful with less apparent differentiation.

Orbicularis oris

Burkitt and Lightoller in 1928 described the orbicularis oris not as a true sphincter muscle but as eight muscle components with their origins in the small muscle mass, the modiolus, at each angle of the mouth. Arising from their respective modioli, the orbicularis fibers of one side end by decussating in the median line with fibers from the opposite side. The orbicularis is composed of four pars peripherales extending from the rima oris outward in an ever diminishing sheet reaching as far as the septum nasi above and the labiomental groove below on the right and left. It lies approximately in the center of the lip, and its fibers are pierced and interlaced by the fibers of the quadratus labii superioris and inferioris and labial portions of the platysma, the so-called labial tractors which pass through it to gain insertion in the fibrous tissue beneath the mucous membrane.

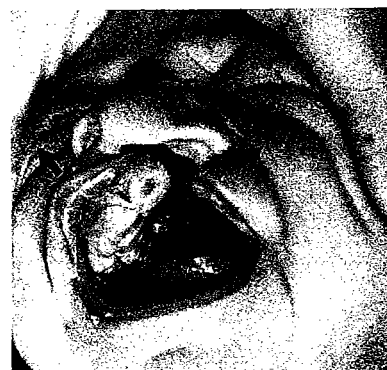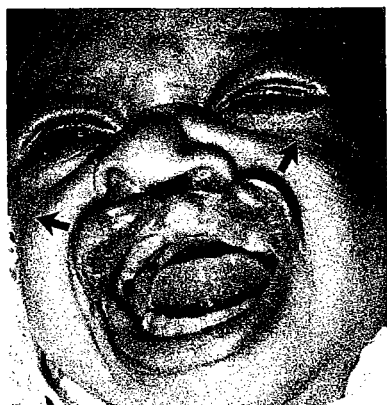Intimately associated with the pars peripheralis is the pars marginalis with its two right and left components lying in a plane superficial to the pars peripheralis and confined to the area beneath the lip vermillion.



Tractor muscles

Greatly affecting the action of this circumoral musculature are the labial tractors. They are radially arranged as superficial and deep muscles, and most have as an attachment the modiolus at the angle of the mouth.

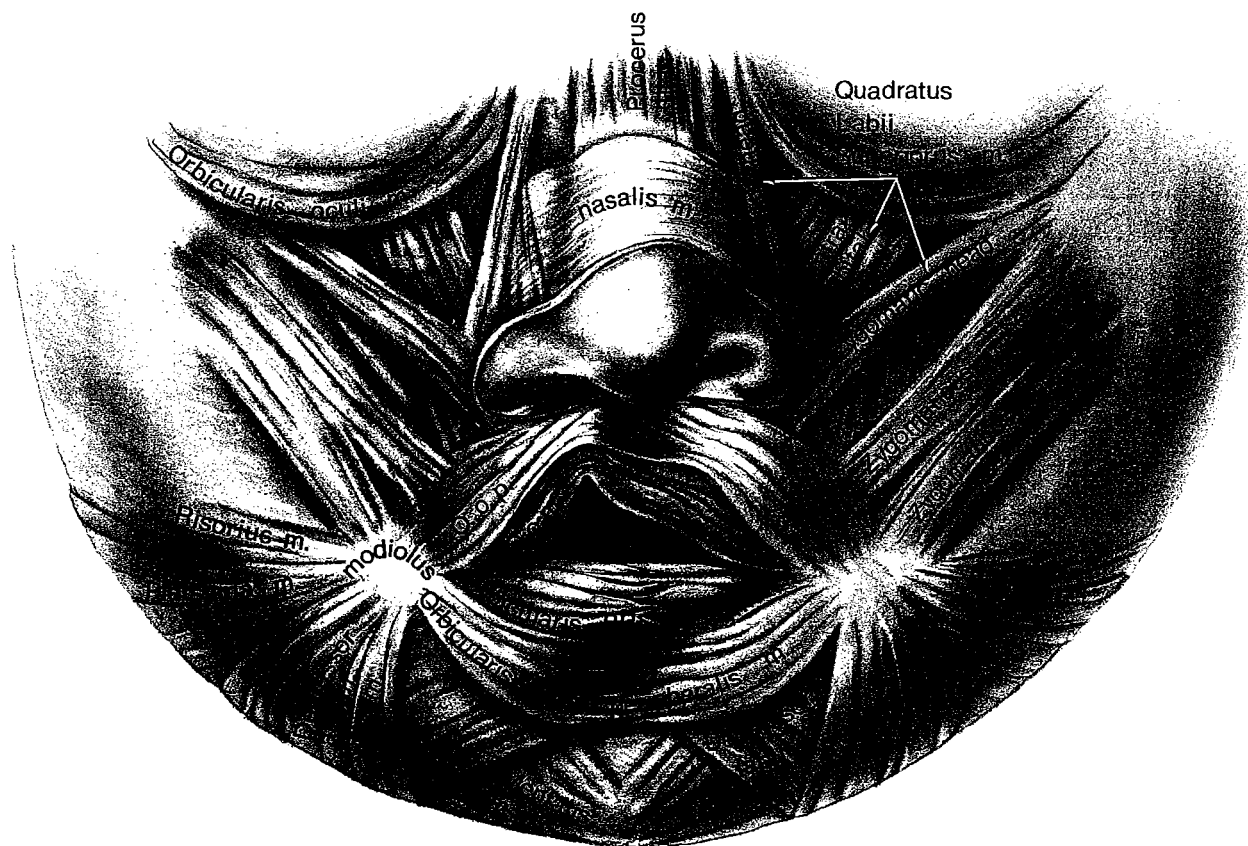
In the upper lip, these include the superficial zygomaticus major and minor, the quadratus labii superioris and the deeper levator anguli oris, which raise the lips and corner of the mouth and spread the nostrils. In the lower lip are the superficial depressor anguli oris and the deep depressor labii inferioris and mentalis muscles, which pull the lip down and the corner of the mouth outward. Then there is the superficial risorius, which pulls the corner of the mouth laterally, and the deep buccinator, which tenses the cheek. The fibers of these muscles insert into both the skin and mucous membrane by means of elastic tendon



extensions. According to Brescia, where the tendons insert in a concentrated area a dimple occurs, but where they insert in a linear fashion a crease is formed.

Cleft muscles

In the presence of a cleft, the orbicularis oris muscle fibers do not decussate transversely across the midline over the maxilla but tend to run up parallel to the cleft edges toward the base of the nose. With their integrity divided, they often contract into a disappointed, useless lump usually evident on the cleft side. With the orbicularis oris muscle sphincter crippled by the split and no longer a worthy opponent, the antagonist tractor muscles make the most of their advantage, exerting unnatural lateral lifting and distortion of the lip elements in both incomplete and complete clefts.



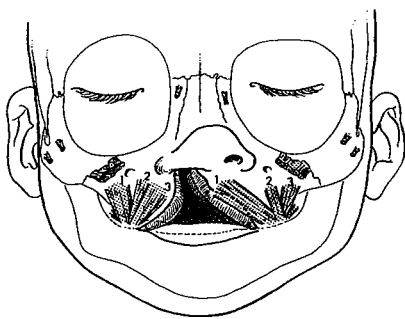
running horizontally to the cleft edge. In unilateral incomplete clefts the muscles did not, as a rule, cross the cleft unless the bridge was at least one-third of the height of the lip. These findings prompted Fara to exclaim:

They show what difficult tasks confront us, if we wish to bring the muscle fibers together "end-to-end" and not "side-to-side" or "end-to-side" in the primary suture of the lip—regardless of the method used.

It is interesting that almost simultaneously, in 1966, Pennisi, Shadish and Klabunde in San Francisco compared microscopic sections of the philtrum and the skin bridge in incomplete clefts with normal lips. Their work was finally published in 1969 when they noted that the muscle fibers in the normal were orderly and transverse whereas in the cleft lip the muscle fibers swept up vertically toward the nose, running parallel to the edges of the cleft.

These general findings were further corroborated by two Muscovites in 1969 when R. D. Novoselov and A. A. Lavrentiev studied the surgical anatomy of the mimetic muscles in the oral region in three cadavers of newborns with congenital unilateral clefts of the upper lip.

On the side of the cleft they have a number of morphological peculiarities: they are less differentiated (more densely adhere to each other and have common muscle fibers), the beginning on the bone is displaced 2–3 mm. anteriorly and posteriorly. The muscles of the surface layer are somewhat longer and wider, approach the angle of the mouth lower by 2–3 mm. Muscles of the deep layers are shorter and narrower in the cross section and are situated to the oral cleft in similar or blunter angles. Splitting of the musculus orbicularis oris is attended by changed direction and attachment of the main muscular bundles of the deep layer. The most powerful of them, the superior muscular bundle on the side of the cleft, is attached to the base of the nasal ala, and on the healthy side in the region of the nasal base. They play an important role in the mechanism of displacement of base of the nasal ala on the side of the cleft and base of the nasal septum on the healthy side. This should be taken into consideration when restoring the continuity of the musculus orbicularis oris. In connection with splitting of the musculus orbicularis oris, the function of the latter is lost. This leads to incoordinated contraction of mimetic



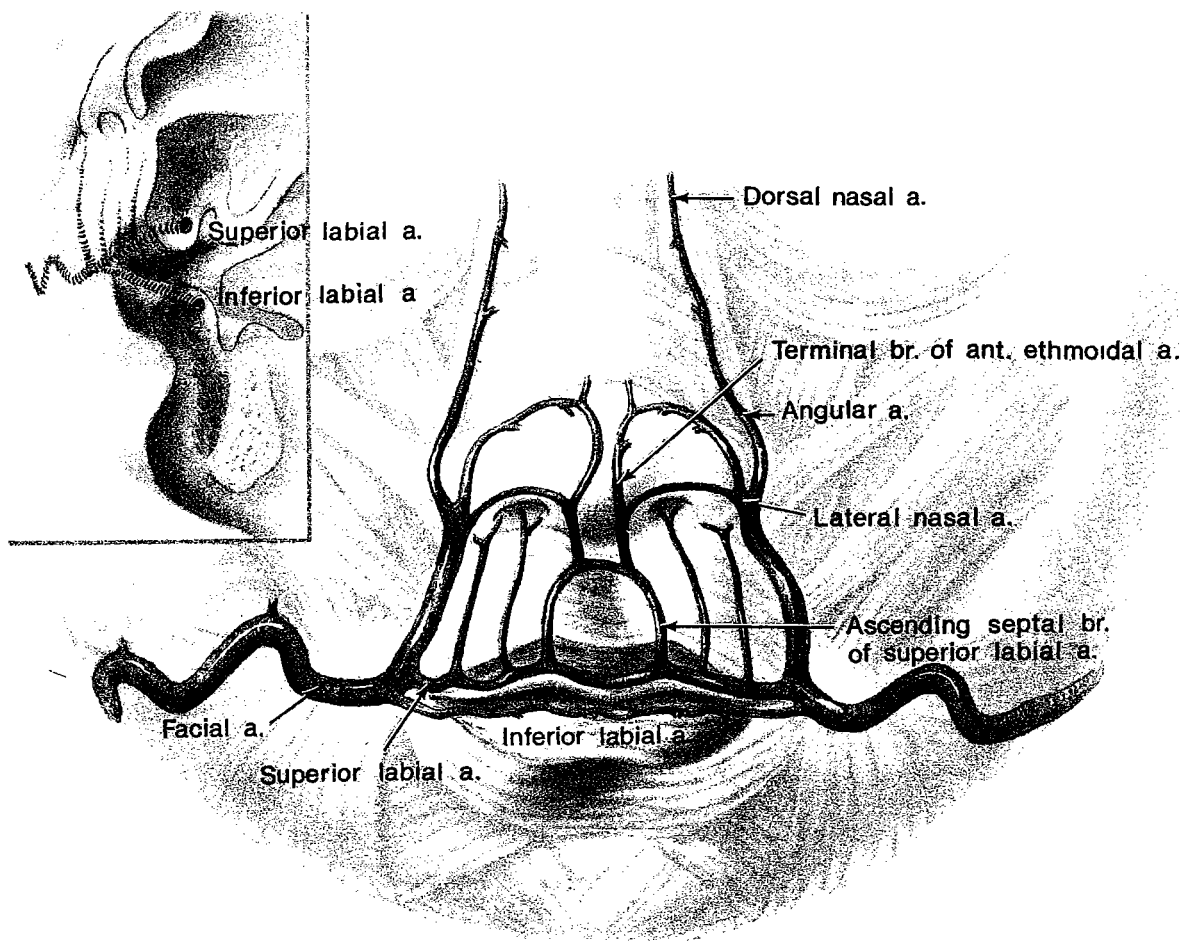
muscles in the oral region. The non-counterbalanced muscles-antagonists at the moment of contraction exert a faulty effect on the nasal cartilages and fragments of the alveolar process. This effect should be considered as one of the active factors in the mechanism of deformations of the nose and facial skeleton.

VESSELS

The main blood supply to the lip and nose area comes from the facial arterial branch of the external carotid artery. Auxiliary sources come from the ophthalmic and the infraorbital arteries. The facial artery gives off inferior and superior labial branches which arise near the corner of the mouth and course as the coronary vessels close to the free border of the upper and lower lips deep to the muscle and close to the mucous membrane. In the upper and lower lip, the right and left labial arteries freely anastomose to form a circle surrounding the oral aperture. The facial artery then proceeds upward along the nasolabial fold and at the ala gives off the lateral nasal branch and then becomes the angular artery proceeding up to anastomose with the dorsal nasal artery, a branch of the ophthalmic. Meanwhile, the posterior septal artery arising from the sphenopalatine artery in the roof of the nasal cavity courses down the vomerine groove to the incisive foramen, anastomosing with the major palatine and ascending septal branches of the superior labial arteries.

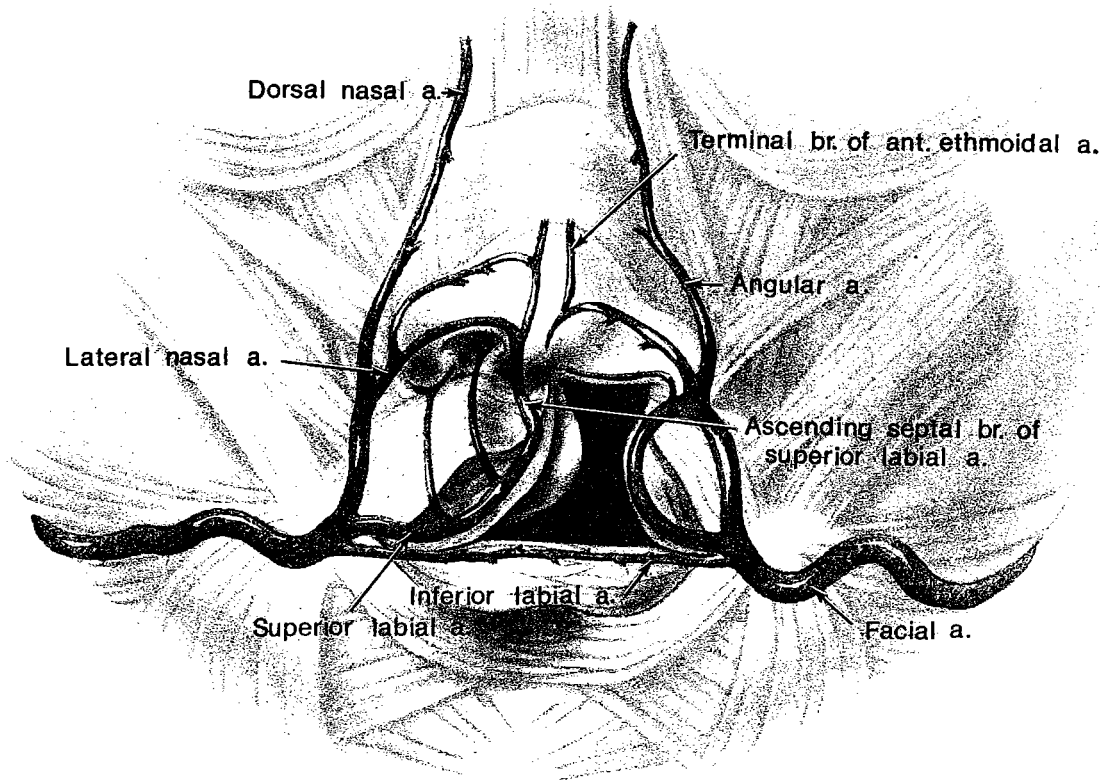
Near the inferior lateral attachment of the ala, the lateral nasal artery splits to run one branch along the lower border and another along the upper border of the lower lateral cartilage. These branches anastomose in the midline with the terminal branches of the anterior ethmoidal arterial extension of the internal carotid artery. The anterior ethmoidal artery comes through the cribriform plate of the ethmoid bone, enters the nose and passes along the undersurface of the nasal bone arch, continuing distally over the upper lateral cartilages to the tip of the nose. Here it joins the lateral nasal branches to continue into the columella, anastomosing with the ascending septal branches of the superior labial artery.

*Important
in the
Abbe flap*



Fara of Charles University, Prague, in his dissections of three incomplete and four complete unilateral clefts found the arterial networks generally coursing along the edge of the cleft upward parallel with the muscle fibers and stronger on the lateral cleft side than on the medial philtrum side. In incomplete clefts the vessels crossed the bridge always from the lateral side.

Slaughter, Henry and Berger dissected out the blood vessels in clefts to demonstrate the variation from the normal, and their 1960 vascular patterns, with slight corrections, have been used as a guide for these anatomical drawings. Although there is an interruption in the usual arcade in the upper lip in unilateral clefts, there is sufficient blood supply to both lip elements and the nose to allow surgery without slough and with the expectation of adequate healing.

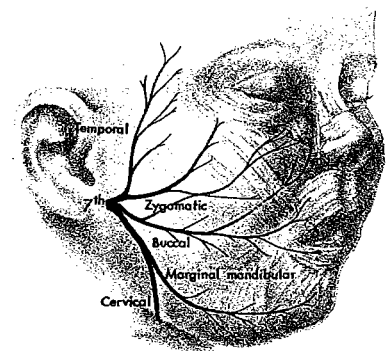
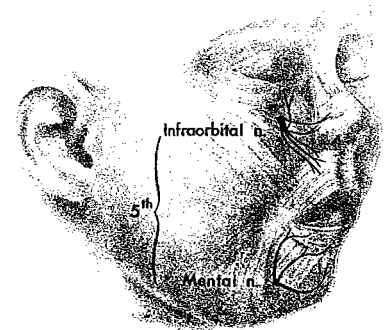


NERVE SUPPLY

The sensory nerve supply to the involved areas of the lips and nose comes from branches of the fifth or trigeminal nerve surfacing through the infraorbital foramen as the infraorbital nerve and through the mental foramen as the mental nerve.

The motor nerve supply to the muscles of the lips and nose comes from the seventh or facial nerve through its zygomatic, buccal and mandibular branches.

Of course, the presence of a cleft through the lip musculature interrupts the normal course of the nerve fibers, but they do extend to or influence the muscles up to the edges of the cleft. As the field of action is involved mostly with the terminal branches of these nerves, their significance in the surgery is limited.



SURFACE ANATOMY



The surface anatomy of the lip and nose is also important in the planning of surgery. It was Leonardo DaVinci, artist, anatomist, sculptor, architect, biologist and engineer, who during the Italian Renaissance, among other things, divided the face into three *equal* parts—the forehead from hairline to brow, the nose from its root to its base and the lips and chin from nasal base to inferior border of the mentum. These proportions with slight variations are essential for a normal face.



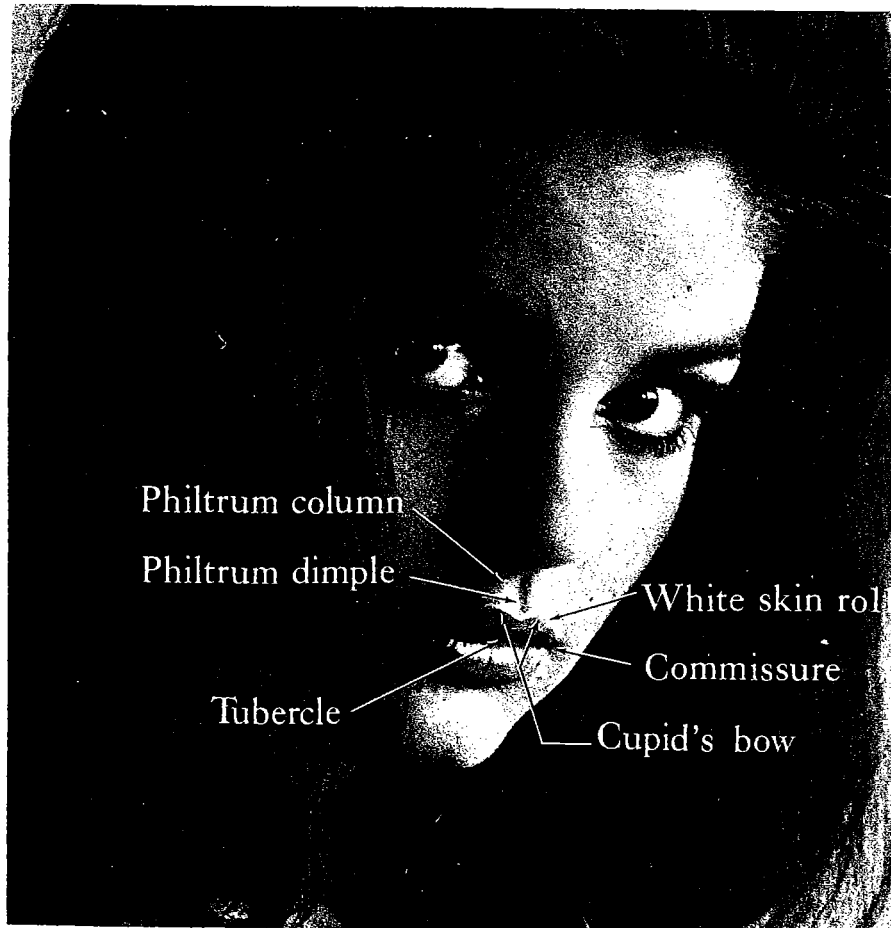
In the normal, the columella stands as a graceful central column, straight and narrow right up to the proud nasal tip. At its base, the columella flows as a nostril sill across in front of the nasal floors toward non-flaring alar bases. The arches of the alae are symmetrical, with equal bulges of the alar cartilages in the nasal tip.

The ideal length of the upper lip at rest places its inferior edge at the lower one-third of the upper incisor teeth. As the upper lip rises, more of the incisors are revealed until with smiling there is three-fourths to total incisor exposure.



The eversion of the upper lip places it slightly out in front of the lower. At the mucocutaneous junction of the upper lip, there is an uninterrupted 1 to 2 mm. rounded roll from com-

missure to commissure which tops the vermilion and picks up a white light. It coincides in its curves with the undulations of the cupid's bow of the vermilion, which has a central free border tubercle flanked by slight indentations. From the height of each arch of the bow, the philtrum columns curve upward toward the base of the columella. Between these columns is a philtrum hollow or dimple which accentuates the effect of the eminences.



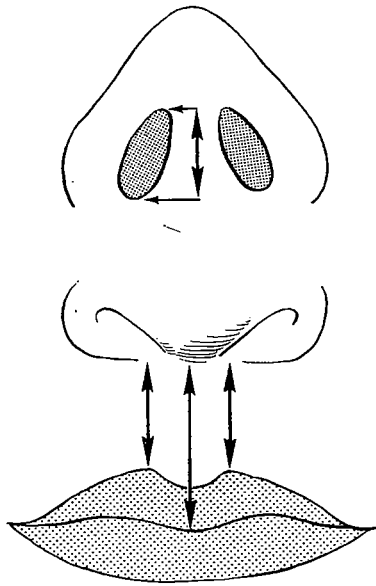
Human noses vary according to race, sex and circumstance as to the straightness of the septum, height and width of the bridge, position and shape of the tip, shape and size of the nostrils, position and thickness of the alar bases and length and width of the columella.

Human lips also vary with race, sex and circumstance in length and width, muscle strength, amount of expression, degree of hair bearing, curve of the cupid's bow, width of the muco-

cutaneous "white roll," depth of the philtrum dimple, height and direction of the philtrum columns, fullness of the vermilion, strength of the tubercle and amount of eversion.

MEASURING THE NORMAL

Farkas and Lindsay measured 100 normal Canadians, 50 boys and 50 girls from the ages of 16 to 20 years. They found:



Length of columella

| | | | |
|--------|-----------|------|----------|
| Male | 10-16 mm. | mean | 12.3 mm. |
| Female | 9-15 mm. | mean | 12.2 mm. |

Width of columella

| | | | |
|--------|----------|------|---------|
| Male | 7-10 mm. | mean | 8.2 mm. |
| Female | 6-9 mm. | mean | 7.9 mm. |

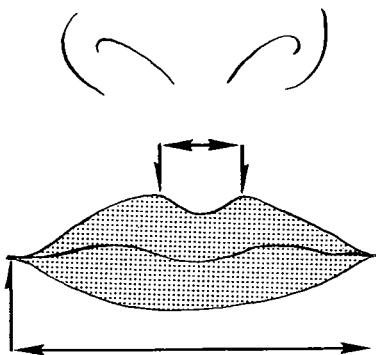
Lateral vertical length of lip

| | | | |
|--------|-----------|------|----------|
| Male | 11-21 mm. | mean | 16.4 mm. |
| Female | 10-20 mm. | mean | 14.6 mm. |

Medial vertical length of lip

| | | | |
|--------|-----------|------|----------|
| Male | 18-26 mm. | mean | 22.0 mm. |
| Female | 16-24 mm. | mean | 19.6 mm. |

The normal Canadian measurements for medial vertical length of lip were similar both to those of central European norms, which Hajnisova found to average 21.2 mm. in the male and 19.2 mm. in the female, and to those of west European norms, which Hajnis found to average 21.5 mm. in the male and 20.5 mm. in the female.



Michael Franz and Anthony Sokol of Columbus, Ohio, measured 40 normal philtrums from peak to peak of the cupid's bow and the total distance from commissure to commissure. They then computed the philtrum-commissure ratio to be the commissural distance divided by a factor of 3.75 to provide the measurement of the proposed philtrum. More simply, the width of the philtrum should be slightly more than one-fourth of the width of the mouth.

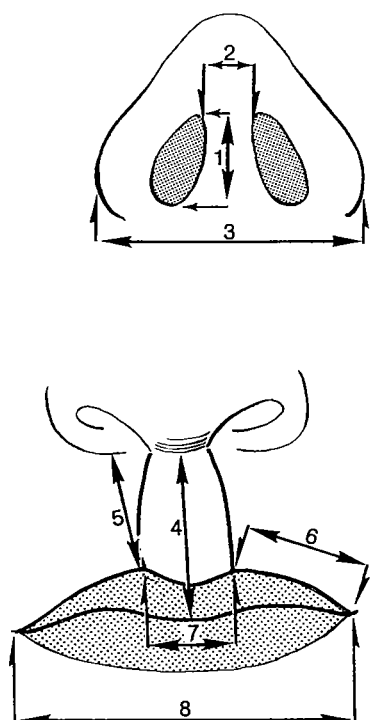
Fully aware of the significance of *knowing the normal*, my residents, with Gaston Schwarz, a Molson Foundation Fellow in training from Montreal, as principal investigator, have taken calipers into their homes, kindergartens, hospital nurseries and wards to compare the key distances in the lip-nose complex at various ages. They have used the calipers on each other and have shown exceptional diligence in measuring the attractive secretaries, nurses and patients of our plastic surgical division. The numbers may not be of great statistical significance, but they follow a trend that might be expected.

RACIAL COMPARISONS

Of course, there are normal differences in races other than skin color, and in the nasolabial area these can be important in the design of cleft correction. A comparison of nose and lip measurements in Caucasian and Negro males and females at various ages reveals, in spite of specific variations, some general consistent differences. For simplicity, all measurements have been rounded off to the nearest tenth of a centimeter.



Averages in cm.



| Age | Newborns | | | | 5 Years | | | | Adults | | | |
|---|-----------|-----|-------|-----|-----------|-----|-------|-----|-----------|-----|-------|-----|
| | Caucasian | | Negro | | Caucasian | | Negro | | Caucasian | | Negro | |
| Sex | M | F | M | F | M | F | M | F | M | F | M | F |
| Nose | | | | | | | | | | | | |
| 1. Columella height | 0.4 | 0.4 | 0.5 | 0.3 | 0.7 | 0.6 | 0.5 | 0.5 | 1.3 | 1.1 | 1.0 | 0.9 |
| 2. Columella width | 0.4 | 0.5 | 0.4 | 0.4 | 0.7 | 0.7 | 0.5 | 0.6 | 0.8 | 0.6 | 0.9 | 0.7 |
| 3. Nasal width | 2.2 | 2.3 | 2.5 | 2.4 | 2.7 | 2.5 | 3.4 | 3.6 | 3.6 | 3.3 | 4.4 | 4.5 |
| Lip | | | | | | | | | | | | |
| 4. Vertical height (base of columella to tubercle) | 1.5 | 1.2 | 1.4 | 1.4 | 2.1 | 2.1 | 2.4 | 2.3 | 2.4 | 2.0 | 2.6 | 2.9 |
| 5. Vertical height (nasal base to cupid's bow peak) | 1.1 | 1.0 | 1.1 | 1.2 | 1.6 | 1.4 | 1.9 | 1.7 | 2.2 | 1.5 | 2.1 | 2.1 |
| 6. Width (cupid's bow to commissure) | 1.5 | 1.5 | 1.6 | 1.5 | 2.3 | 2.3 | 2.3 | 2.1 | 3.2 | 2.9 | 3.1 | 3.5 |
| 7. Width (philtrum, peak to peak) | 0.7 | 0.7 | 0.8 | 0.6 | 1.0 | 1.0 | 1.1 | 0.9 | 1.5 | 1.3 | 1.2 | 1.3 |
| 8. Width (entire mouth, commissure to commissure) | 3.3 | 3.5 | 3.8 | 3.0 | 5.6 | 5.3 | 5.3 | 5.1 | 6.3 | 5.7 | 7.2 | 5.7 |
| Total number of cases | 12 | 12 | 10 | 10 | 13 | 11 | 12 | 14 | 20 | 20 | 17 | 18 |

GENERALIZATIONS ON CAUCASIAN AND NEGRO MEASUREMENTS

Columella: There is no real difference in height at birth, but with growth there is a greater increase in height and width in Caucasians.

Nasal width: In the Negro the nose is only slightly wider at birth but with growth becomes considerably wider.

Lip length: Negro and Caucasian are close in lip length at birth, but with growth there is more elongation in the Negro, especially in females. It is of interest that our Caucasians resemble the Canadian and European Caucasian in vertical lip measurements.

Mouth width: Sexes and races are close, but total mouth width is greater in the male Negro at birth and as an adult.

Philtrum: The races and sexes are close at birth, but Caucasian adult males have wider philtrums than Negro males.

COMPARISONS WITH ORIENTALS

Curiosity about comparison of the Caucasian and Negro with the Oriental prompted me to ask my friend Khoo Boo-Chai in Singapore to measure some Chinese lips and noses. His measurements unfortunately were carried out on postoperative clefts, but as the normal side was measured there probably can be some correlation.



Averages in cm.

| Age | 3 Months | | 5 Years | | Adults | |
|--|----------|-----|---------|-----|---------|-----|
| Race | Chinese | | Chinese | | Chinese | |
| Sex | M | F | M | F | M | F |
| Nose | | | | | | |
| 1. Columella height | 0.4 | 0.4 | 0.5 | 0.4 | 0.6 | 0.5 |
| 2. Columella width | 0.5 | 0.5 | 0.5 | 0.6 | 0.6 | 0.7 |
| 3. Nasal width | 3.1 | 3.0 | 3.5 | 3.5 | 4.3 | 3.9 |
| Lip | | | | | | |
| 4. Vertical height (base of columella to tubercle) | 1.2 | 1.1 | 1.3 | 1.5 | 2.2 | 1.9 |
| 5. Vertical height (nasal base to cupid's bow peak) | 1.2 | 1.2 | 1.2 | 1.2 | 1.6 | 1.3 |
| 6. Width (cupid's bow to commissure) | 1.7 | 1.7 | 2.5 | 1.8 | 2.6 | 2.5 |
| 7. Width (Philtrum, peak to peak) | 0.7 | 0.7 | 0.8 | 1.0 | 1.2 | 1.1 |
| 8. Width (entire mouth, commissure to commissure) | 3.3 | 3.4 | 4.1 | 4.9 | 5.6 | 5.3 |
| Total number of cases | 7 | 3 | 7 | 1 | 4 | 6 |

Columella length and *nasal width* of the Chinese at five years are closer to those of the Negro and in the adult fall between those of the Caucasian and Negro.

In the Chinese *lip length* is shorter and *mouth width* is smaller than in either Caucasian or Negro, but the *philtrum width* is about equal to that of both Caucasian and Negro.

It is possible that these slight but consistent differences may explain, in part, the rash of variations appearing in the Oriental cleft lip literature.

A BUILT-IN NORMAL

In the unilateral cleft at least the surgeon has the non-cleft side as a *guide to this individual norm* and should *use it* as such.